Anatomy: Neck

Question 1 of 78

A 28 year old climber falls from a steep rock wall and sustains significant injuries to his back. Imaging shows injuries that impinge on the posterior rami of several spinal nerves. Which of the following muscles is most likely to be affected in this patient:

a Levator scapulae

b Erector spinae

c Trapezius

d Latissimus dorsi

e Rhomboid major

Next > | See Answer | Something wrong?

Question Navigator

1 Current Question
2 ...
3 ...
4 ...
5 ...
6 ...
7 ...
8 ...
9 ...
10 ...
11 ...
12 ...

©2014 - 2017 FRCEM Success | Website designed & hosted by Cyberfrog Design

Anatomy: Neck

Question 1 of 78

A 28 year old climber falls from a steep rock wall and sustains significant injuries to his back. Imaging shows injuries that impinge on the posterior rami of several spinal nerves. Which of the following muscles is most likely to be affected in this patient:

a) **Levator scapulae** ✗
b) Erector spinae ✓
c) Trapezius
d) Latissimus dorsi
e) Rhomboid major

Answer

The intrinsic back muscles, including the erector spinae muscles, are innervated by the posterior rami of spinal nerves. The extrinsic back muscles (including the trapezius, latissimus dorsi, rhomboid major and minor, and levator scapulae muscles) are innervated by the anterior rami of spinal nerves.

Notes

Movements by the vertebral column include flexion, extension, lateral flexion and rotation. Rotation occurs predominantly in the thoracic column.

Muscles of the back are organised into superficial, intermediate and deep groups.

- Extrinsic muscles (innervated by anterior rami of spinal nerves)
  - The superficial group consists of muscles related to and involved with movements of the upper limb.
  - The intermediate group consists of muscles attached to the ribs and involved in respiratory function.
- Intrinsic muscles (innervated by posterior rami of spinal nerves)
  - The deep group consists of muscles directly related to movements of the vertebral column and head.

The deep muscles of the back include:

- the splenius capitis and cervicis (extensors and rotators of the head and neck)
- the erector spinae and transversospinalis (extensors and rotators of the vertebral column)
- the short segmental muscles.

The erector spinae (highlighted red) is the largest group of intrinsic back muscles, lying posterolaterally to the vertebral column between the spinous processes medially and the angles of the ribs laterally. The muscles in the erector spinae group are the primary extensors of the vertebral column and head. Acting bilaterally, they straighten the back, returning it to the upright position from the flexed position, and pull the head posteriorly. Acting unilaterally, they bend the vertebral column laterally.

Flexion of the vertebral column is provided predominantly by the rectus abdominis muscle assisted for rotation by the obliques.

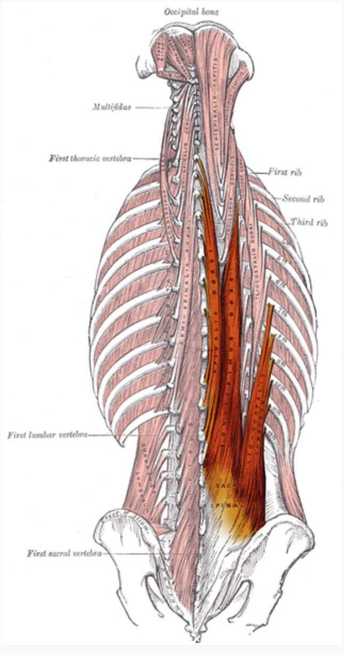

By Henry Vandyke Carter [Public domain], via Wikimedia Commons

Next >

Something wrong?

Question Navigator

1 Current Question
2 ...
3 ...
4 ...
5 ...
6 ...
7 ...
8 ...
9 ...
10 ...
11 ...
12 ...

©2014 - 2017 FRCEM Success | Website designed & hosted by Cyberfrog Design

FRCEMSuccess

MENU

Anatomy: Neck

Question 2 of 78

A 18 year old presents to ED with painful swollen exudative tonsils. You diagnose acute bacterial tonsillitis. Which of the following lymph nodes is most likely to first become visibly enlarged during tonsillitis:

a Submandibular

b Parotid

c Preauricular

d Submental

e Jugulodigastric

< Previous | Next > | See Answer

Something wrong?

Question Navigator

1 Answered
2 Current Question
3 ...
4 ...
5 ...
6 ...
7 ...
8 ...
9 ...
10 ...
11 ...
12 ...

©2014 - 2017 FRCEM Success | Website designed & hosted by Cyberfrog Design

Anatomy: Neck

Question 2 of 78

A 18 year old presents to ED with painful swollen exudative tonsils. You diagnose acute bacterial tonsillitis. Which of the following lymph nodes is most likely to first become visibly enlarged during tonsillitis:

a) **Submandibular** ✗
b) Parotid
c) Preauricular
d) Submental
e) Jugulodigastric ✓

Answer

The jugulodigastric node directly receives lymphatic drainage from the palatine tonsils, tongue and pharynx.

Notes

The deep cervical nodes form a chain along the internal jugular vein and are divided into upper and lower groups.

The most superior node in the upper group (lying where the posterior belly of the digastric muscle crosses the internal jugular vein) is the jugulodigastric node which receives lymphatic drainage from the tonsils and tonsillar region.

The most superior node in the lower group (lying just inferior to the intermediate tendon of the omohyoid muscle) is the jugulo-omohyoid node which receives lymphatic drainage from the tongue.

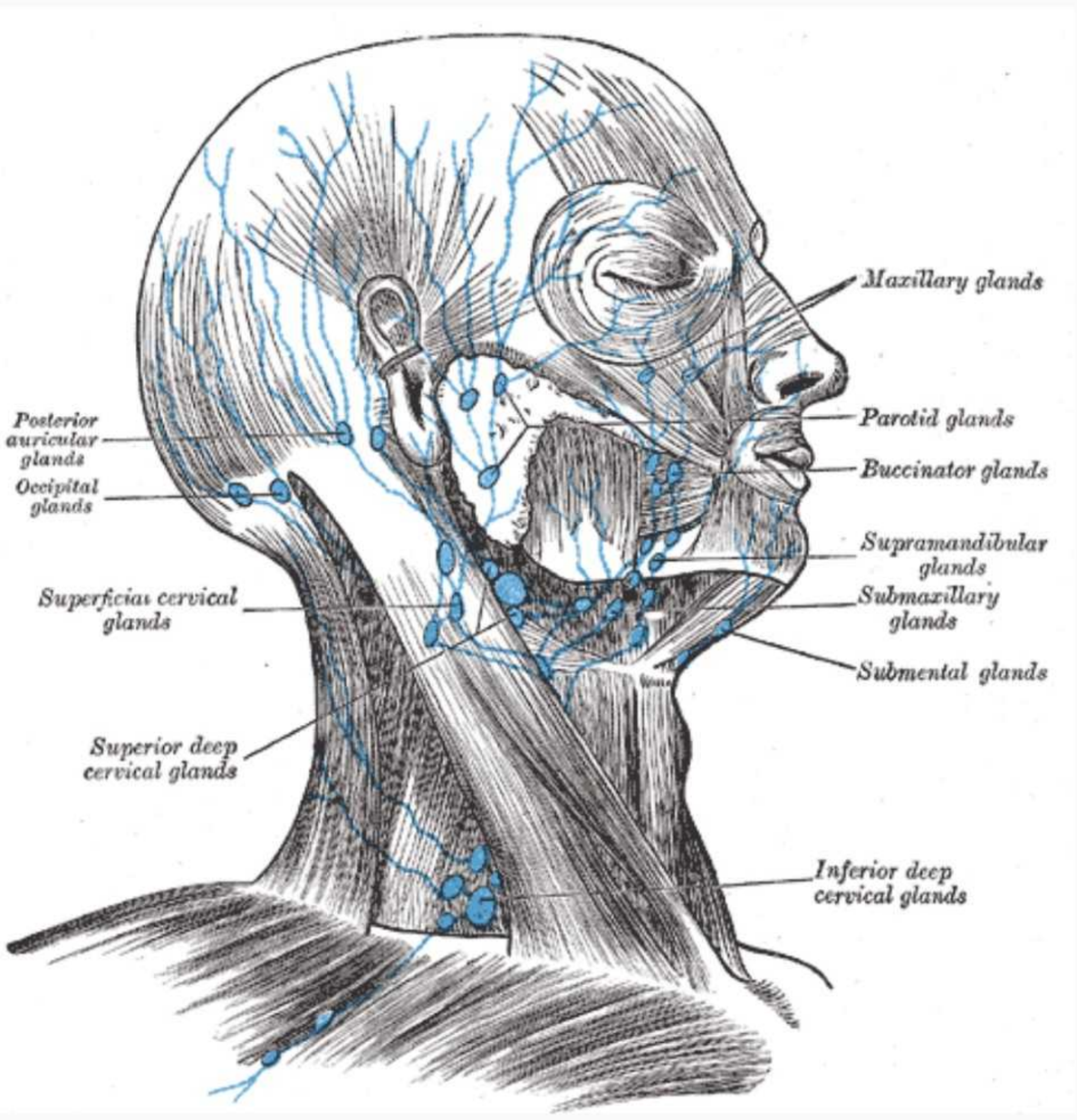

By Henry Vandyke Carter [Public domain], via Wikimedia Commons

< Previous | Next >

Something wrong?

Question Navigator

1 Answered
2 Current Question
3 ...
4 ...
5 ...
6 ...
7 ...
8 ...
9 ...
10 ...
11 ...
12 ...

©2014 - 2017 FRCEM Success | Website designed & hosted by Cyberfrog Design

Anatomy: Neck

Question 3 of 78

The intrinsic laryngeal muscles (except for the cricothyroid) are primarily innervated by which of the following nerves:

a Superior laryngeal nerve

b Recurrent laryngeal nerve

c Internal laryngeal nerve

d External laryngeal nerve

e Glossopharyngeal nerve

< Previous | Next > | See Answer

Something wrong?

Question Navigator

1 Answered
2 Answered
3 Current Question
4 ...
5 ...
6 ...
7 ...
8 ...
9 ...
10 ...
11 ...
12 ...

©2014 - 2017 FRCEM Success | Website designed & hosted by Cyberfrog Design

Anatomy: Neck

Question 3 of 78

The intrinsic laryngeal muscles (except for the cricothyroid) are primarily innervated by which of the following nerves:

a) Superior laryngeal nerve ✗
b) Recurrent laryngeal nerve ✓
c) Internal laryngeal nerve
d) External laryngeal nerve
e) Glossopharyngeal nerve

Answer

The recurrent laryngeal nerves are sensory to the laryngeal cavity below the level of the vocal folds and motor to all intrinsic muscles of the larynx except for the cricothyroid muscle (innervated by the superior laryngeal branch of the vagus nerve).

Notes

The larynx is suspended from the superior hyoid bone and attached to the trachea below by membranes and ligaments. It opens above into the pharynx immediately posterior and slightly inferior to the tongue and the oropharyngeal isthmus of the oral cavity, and blends inferiorly with the trachea at the vertebral level C6.

Function

There are four principal roles of the larynx:

- phonation
- sphincteric to close the lower respiratory tract (for example during swallowing)
- coughing
- breath-holding while straining (vocal cord adduction).

Laryngeal muscles

The laryngeal muscles are divided into intrinsic and extrinsic groups.

The intrinsic muscles alter the size and shape of the laryngeal inlet and move the vocal folds.

The extrinsic muscles are involved in elevation and depression of the larynx to produce swallowing.

Innervation

Motor and sensory innervation of the larynx is provided by the vagus nerve via its superior laryngeal and recurrent laryngeal branches.

The recurrent laryngeal nerves are sensory to the laryngeal cavity below the level of the vocal folds and motor to all intrinsic muscles of the larynx except for the cricothyroid muscle (innervated by the superior laryngeal branch of the vagus nerve).

A lesion of the recurrent laryngeal nerve may cause respiratory obstruction, hoarseness, inability to speak and loss of sensation below the vocal cord.

The superior laryngeal nerve supplies sensation to the mucous membrane above the vocal cord and the taste buds on the epiglottis, and motor innervation to the cricothyroid and the inferior pharyngeal constrictor muscles.

A lesion of the superior laryngeal nerve may cause loss of sensation above the vocal cord and taste on the epiglottis, and a weak hoarse voice.

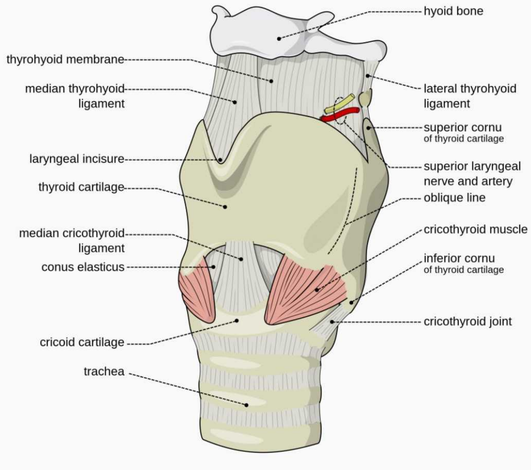

By Olek Remesz (wiki-pl: Orem, commons: Orem) [CC BY-SA 2.5-2.0-1.0], via Wikimedia Commons

< Previous | Next >

Something wrong?

Question Navigator

1 Answered
2 Answered
3 Current Question
4 ...
5 ...
6 ...
7 ...
8 ...
9 ...
10 ...
11 ...
12 ...

©2014 - 2017 FRCEM Success | Website designed & hosted by Cyberfrog Design

Anatomy: Neck

Question 4 of 78

A 34 year old woman presents to ED complaining of a hoarse voice. She underwent a thyroidectomy 2 weeks ago. Which of the following nerves was most likely injured during the procedure:

a External laryngeal nerve

b Glossopharyngeal nerve

c Recurrent laryngeal nerve

d Superior laryngeal nerve

e Internal laryngeal nerve

< Previous | Next > | See Answer

Something wrong?

Question Navigator

1 Answered
2 Answered
3 Answered
4 Current Question
5 ...
6 ...
7 ...
8 ...
9 ...
10 ...
11 ...
12 ...

©2014 - 2017 FRCEM Success | Website designed & hosted by Cyberfrog Design

Anatomy: Neck

Question 4 of 78

A 34 year old woman presents to ED complaining of a hoarse voice. She underwent a thyroidectomy 2 weeks ago. Which of the following nerves was most likely injured during the procedure:

a) External laryngeal nerve ✖
b) Glossopharyngeal nerve
c) Recurrent laryngeal nerve ✔
d) Superior laryngeal nerve
e) Internal laryngeal nerve

Answer

The thyroid gland and the recurrent laryngeal nerve are in close proximity and thus this nerve is most likely injured in thyroid surgery. The recurrent laryngeal nerve supplies most of the motor innervation to the larynx and sensation below the true vocal folds.

Notes

The thyroid gland is anterior in the neck, below and lateral to the thyroid cartilage, and spanning between the C5 and T1 vertebrae.

It has two lateral lobes (which cover the anterolateral surfaces of the trachea, cricoid cartilage and the lower part of the thyroid cartilage) connected by the isthmus which crosses the anterior surface of the second and third tracheal cartilages.

Relations

It lies deep to the sternohyoid, sternothyroid and omohyoid muscles, in the visceral compartment of the neck, together with and anterior to the pharynx, trachea and oesophagus, and surrounded by the pretracheal fascia.

Structures vulnerable in thyroid surgery include:

- Thyroidea ima artery
- Inferior thyroid vein
- Anterior jugular vein
- Recurrent laryngeal nerve
- Cervical dome of the pleura
- Oesophagus
- Parathyroid glands

Blood supply

The thyroid gland is supplied predominantly by the superior thyroid artery (branch of the external carotid artery) and the inferior thyroid artery (branch of the thyrocervical trunk from the subclavian artery). Occasionally a small thyroidea ima artery arises from the brachiocephalic trunk or the arch of the aorta and ascends to supply the thyroid gland.

Venous supply

The venous drainage of the thyroid is to the superior and middle thyroid veins (draining to the internal jugular vein) and the inferior thyroid veins (draining to the brachiocephalic veins).

Lymphatics

Lymphatic drainage of the thyroid gland is to nodes beside the trachea (paratracheal nodes) and to deep cervical nodes inferior to the omohyoid muscle along the internal jugular vein.

Recurrent laryngeal nerve

The thyroid gland is closely related to the recurrent laryngeal nerves. After branching from the vagus nerve and looping around the subclavian artery on the right and the arch of the aorta on the left, the recurrent laryngeal nerves ascend in the neck in a groove between the trachea and oesophagus. They pass deep to the posteromedial surface of the lateral lobes of the thyroid gland and enter the larynx by passing deep to the lower margin of the inferior constrictor of the pharynx.

The recurrent laryngeal nerve is the most commonly injured nerve during thyroid surgery. The recurrent laryngeal nerves supply sensory innervation to the laryngeal cavity below the level of the vocal folds and motor innervation to all intrinsic muscles of the larynx except for the cricothyroid muscle.

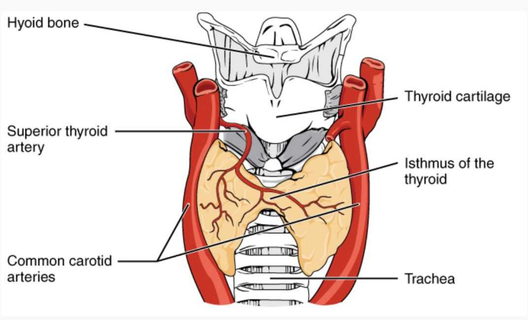

By CFCF (Own work) [CC BY-SA 3.0 (http://creativecommons.org/licenses/by-sa/3.0)], via Wikimedia Commons

< Previous | Next >

Something wrong?

Question Navigator

1 Answered
2 Answered
3 Answered
4 Current Question
5 ...
6 ...
7 ...
8 ...
9 ...
10 ...
11 ...
12 ...

©2014 - 2017 FRCEM Success | Website designed & hosted by Cyberfrog Design

Anatomy: Neck

Question 5 of 78

Regarding the pharynx, which of the following statements is CORRECT:

a The pharynx is continuous with the oesophagus at vertebral level C4.

b The pharyngotympanic tubes open into the lateral walls of the oropharynx.

c The pharyngeal wall is formed by two sheet-like constrictor muscles.

d All of the muscles of the pharynx are innervated by the glossopharyngeal nerve.

e The lymphatics of the pharynx drain to the deep cervical lymph nodes.

< Previous | Next > | See Answer

Something wrong?

Question Navigator

1 Answered
2 Answered
3 Answered
4 Answered
5 Current Question
6 ...
7 ...
8 ...
9 ...
10 ...
11 ...
12 ...

©2014 - 2017 FRCEM Success | Website designed & hosted by Cyberfrog Design

Anatomy: Neck

Question 5 of 78

Regarding the pharynx, which of the following statements is CORRECT:

a) **The pharynx is continuous with the oesophagus at vertebral level C4.** ✗
b) The pharyngotympanic tubes open into the lateral walls of the oropharynx.
c) The pharyngeal wall is formed by two sheet-like constrictor muscles.
d) All of the muscles of the pharynx are innervated by the glossopharyngeal nerve.
e) The lymphatics of the pharynx drain to the deep cervical lymph nodes. ✓

Answer

Lymphatic vessels from the pharynx drain into the deep cervical lymph nodes.

Notes

The pharynx is a musculofascial structure that connects the oral and nasal cavities in the head to the larynx and the oesophagus in the neck.

The pharynx is attached above to the base of the skull, and is continuous below, approximately at the level of vertebra C6, with the top of the oesophagus.

The pharynx is separated from the posterior vertebral column by a thin retropharyngeal space, bordered anteriorly by the buccopharyngeal fascia and posteriorly by the prevertebral fascia.

Arrangement

The walls of the pharynx are attached anteriorly to the margins of the nasal cavities, oral cavity and larynx, dividing the pharynx into the continuous nasopharynx, oropharynx and laryngopharynx respectively.

The posterior apertures of the nasal cavities open into the nasopharynx, the oropharyngeal isthmus opens into the oropharynx and the superior aperture of the larynx opens into the laryngopharynx.

The pharyngotympanic tubes (from the middle ear) open into the lateral walls of the nasopharynx.

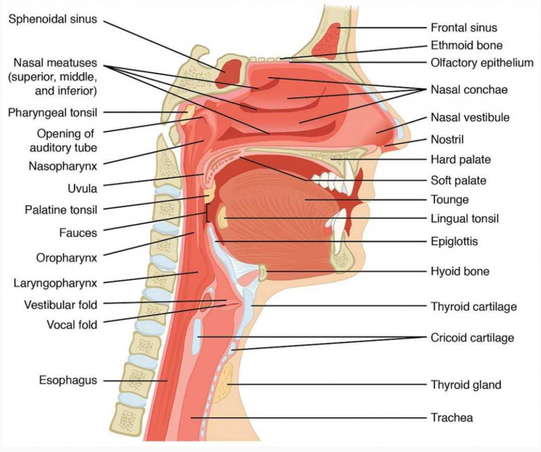

By OpenStax College [CC BY 3.0], via Wikimedia Commons

Muscles

The muscles of the pharyngeal wall are organised into two groups.

The three sheet-like constrictor muscles constrict the pharyngeal cavity sequentially to move a bolus of food through the pharynx and into the oesophagus during swallowing.

The three longitudinal muscles elevate the pharyngeal wall, or during swallowing, pull the pharyngeal wall up and over a bolus of food being moved through the pharynx into the oesophagus.

Nerve supply

The muscles of the pharynx are all innervated by the vagus nerve except for the stylopharyngeus muscle, innervated by the glossopharyngeal nerve. The branches of the vagus and glossopharyngeal nerves form a pharyngeal plexus in the outer fascia of the pharyngeal wall.

Each subdivision of the pharynx has a different sensory innervation:

- the nasopharynx is innervated by the maxillary nerve
- the oropharynx is innervated by the glossopharyngeal nerve
- the laryngopharynx is innervated by the vagus nerve.

Lymphatics

Lymphatic vessels from the pharynx drain into the deep cervical lymph nodes.

< Previous | Next >

Something wrong?

Question Navigator

1 Answered
2 Answered
3 Answered
4 Answered
5 Current Question
6 ...
7 ...
8 ...
9 ...
10 ...
11 ...
12 ...

©2014 - 2017 FRCEM Success | Website designed & hosted by Cyberfrog Design

Anatomy: Neck

Question 6 of 78

A 18 year old female is brought to ED with a fever, headache and neck stiffness. Meningitis is suspected, and your consultant asks you to perform a lumbar puncture. CSF is withdrawn from which of the following spaces:

a Epidural space

b Subarachnoid space

c Subdural space

d Space between the spinal cord and the pia mater

e Space between the dura mater and the spinal canal

< Previous | Next > | See Answer

Something wrong?

Question Navigator

1 Answered
2 Answered
3 Answered
4 Answered
5 Answered
6 Current Question
7 ...
8 ...
9 ...
10 ...
11 ...
12 ...

©2014 - 2017 FRCEM Success | Website designed & hosted by Cyberfrog Design

Anatomy: Neck

Question 6 of 78

A 18 year old female is brought to ED with a fever, headache and neck stiffness. Meningitis is suspected, and your consultant asks you to perform a lumbar puncture. CSF is withdrawn from which of the following spaces:

a) Epidural space ✗
b) Subarachnoid space ✓
c) Subdural space
d) Space between the spinal cord and the pia mater
e) Space between the dura mater and the spinal canal

Answer

CSF is withdrawn from the subarachnoid space between the arachnoid mater and the pia mater.

Notes

The vertebral canal extends from the first cervical vertebra (C1) to the last sacral vertebra (S5). Superiorly the vertebral canal is continuous, through the foramen magnum of the skull, with the cranial cavity.

The vertebral canal is bounded anteriorly by the vertebral bodies, intervertebral discs and the posterior longitudinal ligament, laterally by the vertebral pedicles and posteriorly by the vertebral laminae.

The vertebral canal contains the spinal cord and its protective membranes, together with blood vessels, connective tissue, fat and spinal nerve roots. The conus medullaris is the point below which the canal contains only the cauda equina and filum terminale.

Meninges

The spinal cord is surrounded by a series of three spinal meninges consisting of a dura, arachnoid and pia mater.

The bony walls of the spinal canal are separated from the meninges by the epidural (extradural) space.

The subarachnoid space, containing CSF, is found between the arachnoid and pia mater. The subarachnoid space around the spinal cord is continuous at the foramen magnum with the subarachnoid space surrounding the brain.

Lumbar puncture

In adults, the spinal cord typically ends between L1/L2 whereas the subarachnoid space extends to approximately the lower border of vertebra S2. As a result of this, CSF can be withdrawn from the subarachnoid space in the lower lumbar region without endangering the spinal cord.

When performing a lumbar puncture, the needle passes between adjacent vertebral spinous processes, through the supraspinous and interspinous ligaments and through the ligamentum flavum to enter the extradural space. The needle then continues through the dura and the arachnoid mater to enter the subarachnoid space.

Layers penetrated during lumbar puncture:

- Skin
- Superficial fascia
- Supraspinous ligament
- Interspinous ligament
- Ligamentum flavum (first 'give')
- Extradural space
- Dura mater (second 'give')
- Subdural space
- Arachnoid mater
- Subarachnoid space (containing CSF)

< Previous | Next >

Something wrong?

Question Navigator

1 Answered
2 Answered
3 Answered
4 Answered
5 Answered
6 Current Question
7 ...
8 ...
9 ...
10 ...
11 ...
12 ...

©2014 - 2017 FRCEM Success | Website designed & hosted by Cyberfrog Design

Anatomy: Neck

Question 7 of 78

The phrenic nerve receives contributions from which of the following:

a Anterior rami of C1 – C3

b Anterior rami of C3 – C5

c Anterior rami of C5 – C7

d Posterior rami of C2 – C6

e Posterior rami of C1 – C4

< Previous | Next > | See Answer

Something wrong?

Question Navigator

1 Answered
2 Answered
3 Answered
4 Answered
5 Answered
6 Answered
7 Current Question
8 ...
9 ...
10 ...
11 ...
12 ...

©2014 - 2017 FRCEM Success | Website designed & hosted by Cyberfrog Design

Anatomy: Neck

Question 7 of 78

The phrenic nerve receives contributions from which of the following:

a) **Anterior rami of C1 – C3** ✗
b) Anterior rami of C3 – C5 ✓
c) Anterior rami of C5 – C7
d) Posterior rami of C2 – C6
e) Posterior rami of C1 – C4

Answer

The phrenic nerves are branches of the cervical plexus, arising on each side as contributions from the anterior rami of C3 – C5 come together.

Notes

The phrenic nerves are branches of the cervical plexus, arising on each side as contributions from the anterior rami of C3 – C5 come together.

Passing around the upper lateral border of each anterior scalene muscle, the phrenic nerves continue inferiorly across the anterior surface of the anterior scalene muscle within the prevertebral fascia.

Leaving the lower edge of the anterior scalene muscle, each phrenic nerve passes between the subclavian vein and artery to enter the thorax to continue to the diaphragm.

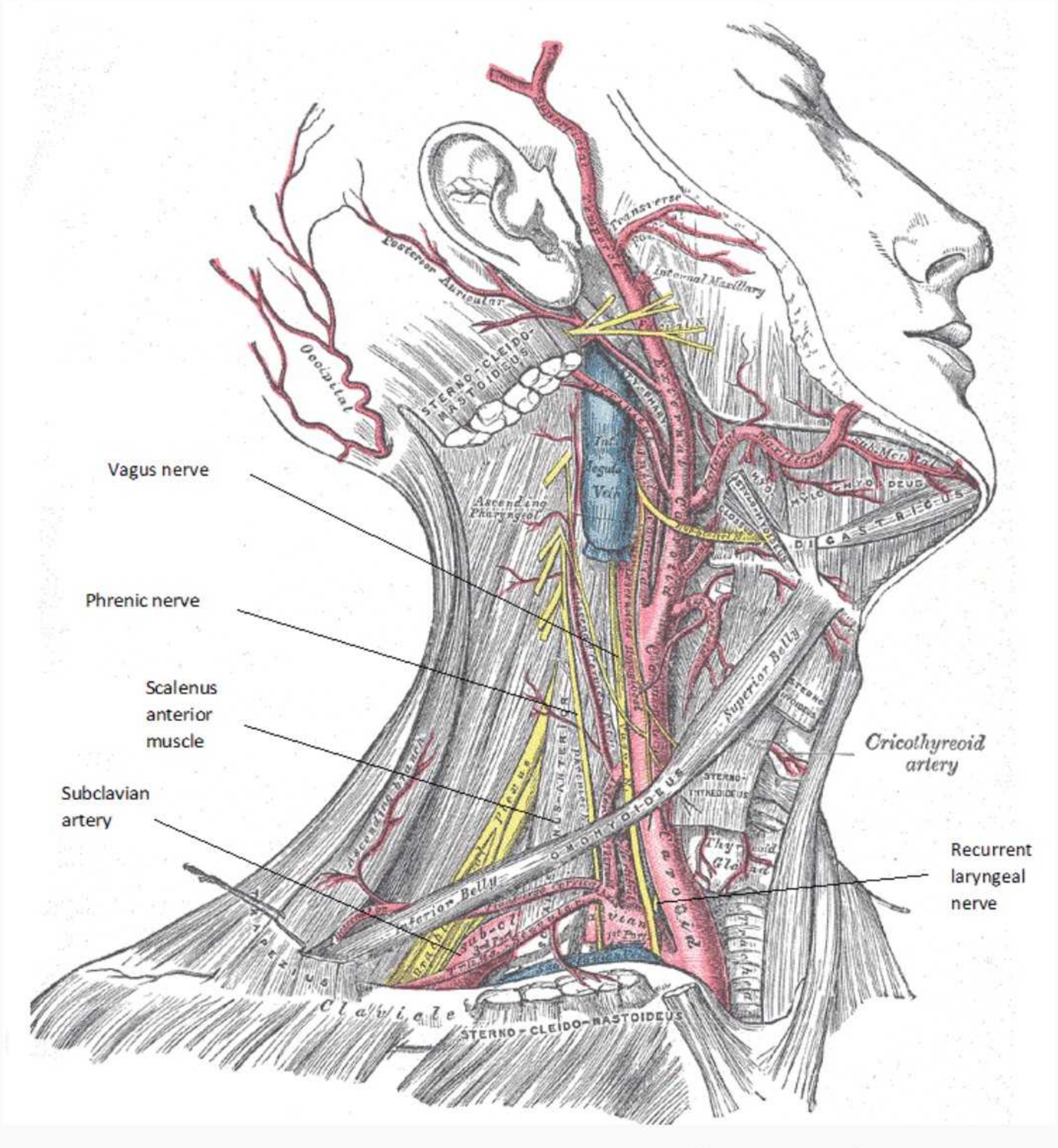

Modified by FRCEM Success. Original by Henry Vandyke Carter [Public domain], via Wikimedia Commons

< Previous | Next >

Something wrong?

Question Navigator

1 Answered
2 Answered
3 Answered
4 Answered
5 Answered
6 Answered
7 Current Question
8 ...
9 ...
10 ...
11 ...
12 ...

©2014 - 2017 FRCEM Success | Website designed & hosted by Cyberfrog Design

Anatomy: Neck

Question 8 of 78

Regarding the recurrent laryngeal nerve, which of the following statements is CORRECT:

a The recurrent laryngeal nerves are branches of the phrenic nerve.

b Damage to the recurrent laryngeal nerve classically causes uvula deviation.

c The right recurrent laryngeal nerve passes beneath and curves around the subclavian artery before ascending in the root of the neck.

d The left recurrent laryngeal nerve originates in the root of the neck.

e The recurrent laryngeal nerves ascend anterior to the trachea.

< Previous | Next > | See Answer

Something wrong?

Question Navigator

1 Answered
2 Answered
3 Answered
4 Answered
5 Answered
6 Answered
7 Answered
8 Current Question
9 ...
10 ...
11 ...
12 ...

©2014 - 2017 FRCEM Success | Website designed & hosted by Cyberfrog Design

Anatomy: Neck

Question 8 of 78

Regarding the recurrent laryngeal nerve, which of the following statements is CORRECT:

a) **The recurrent laryngeal nerves are branches of the phrenic nerve.** ✖

b) Damage to the recurrent laryngeal nerve classically causes uvula deviation.

c) ✔
The right recurrent laryngeal nerve passes beneath and curves around the subclavian artery before ascending in the root of the neck.

d) The left recurrent laryngeal nerve originates in the root of the neck.

e) The recurrent laryngeal nerves ascend anterior to the trachea.

Answer

The right recurrent laryngeal nerve originates in the root of the neck, as a branch of the right vagus nerve as it reaches the lower edge of the first part of the subclavian artery. It passes around the subclavian artery and travels upwards and medially in a groove between the trachea and the oesophagus as it heads to the larynx.

Notes

The right recurrent laryngeal nerve originates in the root of the neck, as a branch of the right vagus nerve as it reaches the lower edge of the first part of the subclavian artery. It passes around the subclavian artery and travels upwards and medially in a groove between the trachea and the oesophagus as it heads to the larynx.

The left recurrent laryngeal nerve originates more inferiorly, from the left vagus nerve as it crosses the arch of the aorta in the superior mediastinum. It passes below and behind the arch of the aorta and then ascends beside the trachea to the larynx.

Damage to the recurrent laryngeal nerves may result in hoarseness, respiratory obstruction, inability to speak and loss of sensation below the vocal cord.

Causes of damage include:

- thyroid/parathyroid surgery
- mediastinal lymphadenopathy
- cricothyroidotomy
- aneurysm of the aortic arch
- lung cancer in the apex of the right lung
- malignancy infiltrating into the 'aortopulmonary window'.

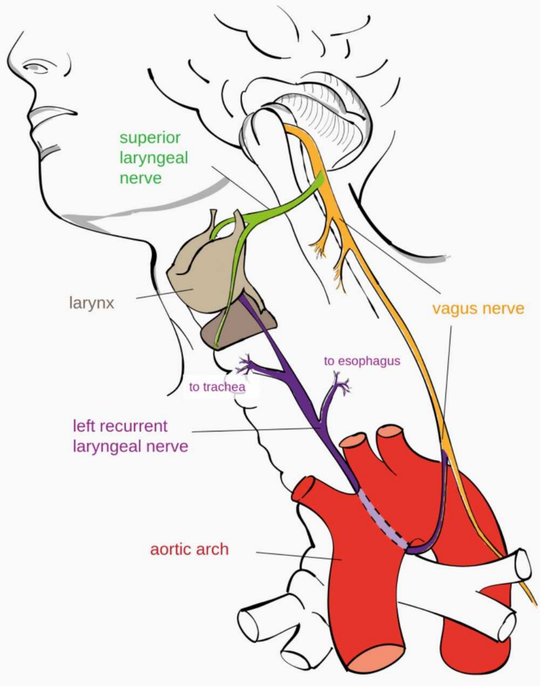

By Jkwchui (Based on drawing by Truth-seeker2004) [CC BY-SA 3.0 (http://creativecommons.org/licenses/by-sa/3.0)], via Wikimedia Commons

< Previous | Next > | Something wrong?

Question Navigator

1 Answered
2 Answered
3 Answered
4 Answered
5 Answered
6 Answered
7 Answered
8 Current Question
9 ...
10 ...
11 ...
12 ...

©2014 - 2017 FRCEM Success | Website designed & hosted by Cyberfrog Design

Anatomy: Neck

Question 9 of 78

The scalenus anterior muscle is innervated by which of the following:

a Thoracodorsal nerve

b Long thoracic nerve

c Accessory nerve

d Cervical nerves C4 – C7

e Cervical nerves C2 – C3

< Previous | Next > | See Answer

Something wrong?

Question Navigator

1 Answered
2 Answered
3 Answered
4 Answered
5 Answered
6 Answered
7 Answered
8 Answered
9 Current Question
10 ...
11 ...
12 ...

©2014 - 2017 FRCEM Success | Website designed & hosted by Cyberfrog Design

Anatomy: Neck

Question 9 of 78

The scalenus anterior muscle is innervated by which of the following:

a) **Thoracodorsal nerve** ✗
b) Long thoracic nerve
c) Accessory nerve
d) Cervical nerves C4 – C7 ✓
e) Cervical nerves C2 – C3

Answer

The scalenus anterior is innervated by the anterior rami of C4 – C7.

Notes

The scalenus anterior is a synergistic stabiliser of the neck and acts together with the other scalene muscles to elevate rib I.

It originates from the anterior tubercles of the transverse processes of vertebrae C3 – C6 and inserts onto the scalene tubercle and upper surface of rib I.

It is innervated by the anterior rami of C4 – C7.

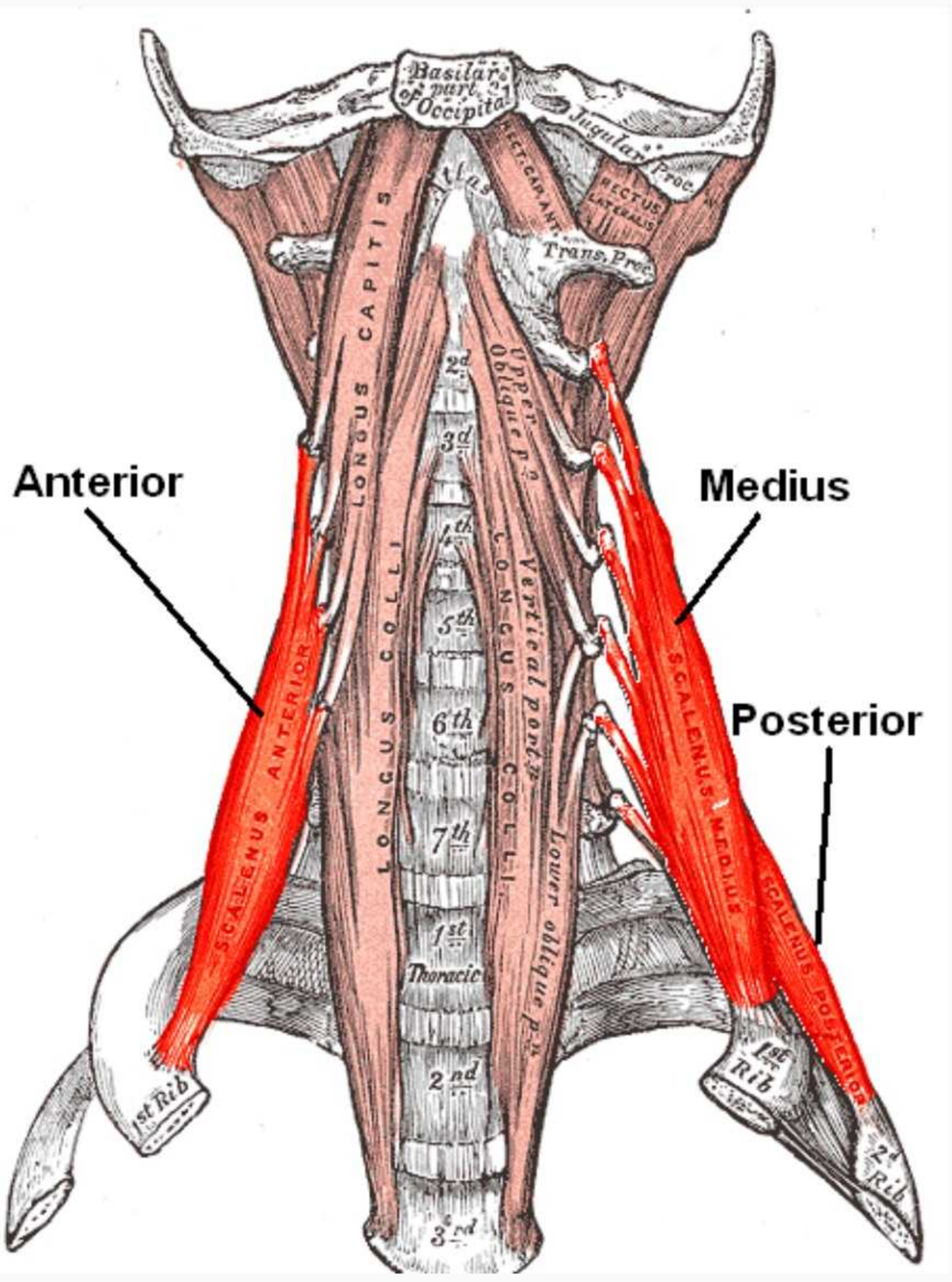

By User:Mikael Häggström (Image:Gray387.png) [Public domain, Public domain or Public domain], via Wikimedia Commons

Question Navigator

1 Answered
2 Answered
3 Answered
4 Answered
5 Answered
6 Answered
7 Answered
8 Answered
9 Current Question
10 Unanswered
11 Unanswered
12 Unanswered

Clear Exam

< Previous | Next >

Something wrong?

©2014 - 2017 FRCEM Success | Website designed & hosted by Cyberfrog Design

Anatomy: Neck

Question 10 of 78

A 28 year old male patient is brought to ED following a motorbike accident. On performing a full neurological examination you note that the patient has weakness of the right side of the body with an extensor reflex and hyperreflexia, loss of fine-touch and vibration on the right side of the body and loss of pain and temperature and the left side of the body. These clinical features are most likely caused by which of the following lesions:

a Central cord syndrome

b Hemisection of the right cervical spinal cord

c Hemisection of the left cervical spinal cord

d Anterior cord syndrome

e Complete transection of the cervical spinal cord

< Previous | Next > | See Answer

Something wrong?

Question Navigator

1 Answered
2 Answered
3 Answered
4 Answered
5 Answered
6 Answered
7 Answered
8 Answered
9 Answered
10 Current Question
11 Unanswered
12 Unanswered

Clear Exam

©2014 - 2017 FRCEM Success | Website designed & hosted by Cyberfrog Design

Anatomy: Neck

Question 10 of 78

A 28 year old male patient is brought to ED following a motorbike accident. On performing a full neurological examination you note that the patient has weakness of the right side of the body with an extensor reflex and hyperreflexia, loss of fine-touch and vibration on the right side of the body and loss of pain and temperature and the left side of the body. These clinical features are most likely caused by which of the following lesions:

a) Central cord syndrome ✗
b) Hemisection of the right cervical spinal cord ✓
c) Hemisection of the left cervical spinal cord
d) Anterior cord syndrome
e) Complete transection of the cervical spinal cord

Answer

This is the classical Brown-Sequard syndrome caused by hemisection of the spinal cord. There is ipsilateral motor loss (corticospinal tract) and loss of fine-touch/vibration/proprioception sensation (posterior column) with contralateral loss of pain/temperature sensation (spinothalamic tract) due to decussation of the spinothalamic tract fibres within the spinal cord. Therefore in this case the lesion must be on the right side of the spinal cord.

Notes

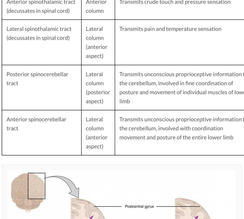

By Pularlys and Mikael Häggström [CC BY-SA 3.0 (http://creativecommons.org/licenses/by-sa/3.0) or GFDL (http://www.gnu.org/copyleft/fdl.html)], via Wikimedia Commons

Ascending tracts

The ascending spinal cord tracts represent functional pathways that convey sensory information from the periphery to higher levels.

Tract	Location	Function
Posterior column-medial lemniscus pathway (fasciculus gracilis and fasciculus cuneatus)	Posterior column	Transmits proprioception, vibration and fine-touch sensation
Anterior spinothalamic tract (decussates in spinal cord)	Anterior column	Transmits crude touch and pressure sensation
Lateral spinothalamic tract (decussates in spinal cord)	Lateral column (anterior aspect)	Transmits pain and temperature sensation
Posterior spinocerebellar tract	Lateral column (posterior aspect)	Transmits unconscious proprioceptive information to the cerebellum, involved in fine coordination of posture and movement of individual muscles of lower limb
Anterior spinocerebellar tract	Lateral column (anterior aspect)	Transmits unconscious proprioceptive information to the cerebellum, involved with coordination movement and posture of the entire lower limb

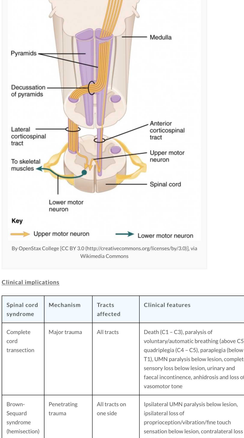

By OpenStax College [CC BY 3.0 (http://creativecommons.org/licenses/by/3.0)], via Wikimedia Commons

Descending tracts

The descending tracts are functional pathways concerned with somatic and visceral motor activities.

Tract	Location	Function
Lateral corticospinal tract	Lateral column (posterior aspect)	Involved in voluntary skilled motor activity of limbs
Anterior corticospinal tract (decussates in spinal cord)	Anterior column	Involved with control of axial muscles

By OpenStax College [CC BY 3.0 (http://creativecommons.org/licenses/by/3.0)], via Wikimedia Commons

Clinical implications

Spinal cord syndrome	Mechanism	Tracts affected	Clinical features
Complete cord transection	Major trauma	All tracts	Death (C1 – C3), paralysis of voluntary/automatic breathing (above C5), quadriplegia (C4 – C5), paraplegia (below T1), UMN paralysis below lesion, complete sensory loss below lesion, urinary and faecal incontinence, arhidrosis and loss of vasomotor tone
Brown-Sequard syndrome (hemisection)	Penetrating trauma	All tracts on one side	Ipsilateral UMN paralysis below lesion, Ipsilateral loss of proprioception/vibration/fine touch sensation below lesion, contralateral loss of crude touch/pain/temperature sensation below lesion, bilateral lower limb ataxia
Central cord syndrome	Hyperextension injury of cervical spine in patient with pre-existing cervical stenosis	Lateral corticospinal tract, spinothalamic tract	Bilateral sensory loss and UMN motor loss below lesion with greater loss in upper limbs than lower limbs, and greater loss of motor function than sensory function
Anterior cord syndrome	Occlusion of anterior spinal artery with infarction of territory supplied	Corticospinal, spinothalamic and spinocerebellar	Paralysis of voluntary/automatic breathing, faecal and urinary incontinence, bilateral Horner's syndrome, bilateral flaccid paralysis at level of lesion, bilateral spastic paralysis below lesion, bilateral loss of crude touch/pain/temperature sensation below lesion, cerebellar incoordination

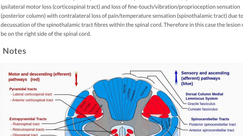

By Fyjacquot, via Wikimedia Commons

Question Navigator

1 Answered
2 Answered
3 Answered
4 Answered
5 Answered
6 Answered
7 Answered
8 Answered
9 Answered
10 Current Question
11 Unanswered
12 Unanswered

Clear Exam

< Previous | Next >
Something wrong?

©2014 - 2017 FRCEM Success | Website designed & hosted by Cyberfrog Design

Anatomy: Neck

Question 11 of 78

A 18 year old presents to ED complaining of a sore throat and painful swallowing. On examination you note that his palatine tonsils are swollen and exudative. Which of the following best describes the location of the palatine tonsils:

a Lateral wall of oropharynx posterior to the palatopharyngeal arch

b Pharyngeal surface of tongue

c Lateral wall of oropharynx anterior to the palatoglossal arch

d Roof of the nasopharynx

e Lateral wall of oropharynx between palatoglossal arch and palatopharyngeal arch

< Previous | Next > | See Answer

Something wrong?

Question Navigator

1 Answered
2 Answered
3 Answered
4 Answered
5 Answered
6 Answered
7 Answered
8 Answered
9 Answered
10 Answered
11 Current Question
12 Unanswered

Clear Exam

©2014 - 2017 FRCEM Success | Website designed & hosted by Cyberfrog Design

Anatomy: Neck

Question 11 of 78

A 18 year old presents to ED complaining of a sore throat and painful swallowing. On examination you note that his palatine tonsils are swollen and exudative. Which of the following best describes the location of the palatine tonsils:

a) **Lateral wall of oropharynx posterior to the palatopharyngeal arch** ✗
b) Pharyngeal surface of tongue
c) Lateral wall of oropharynx anterior to the palatoglossal arch
d) Roof of the nasopharynx
e) Lateral wall of oropharynx between palatoglossal arch and palatopharyngeal arch ✓

Answer

The palatine tonsils are on the lateral walls of the oropharynx. On each side there is a large ovoid collection of lymphoid tissue in the mucosa lining the superior constrictor muscle, between the palatoglossal and palatopharyngeal arches and just posterior to the oropharyngeal isthmus.

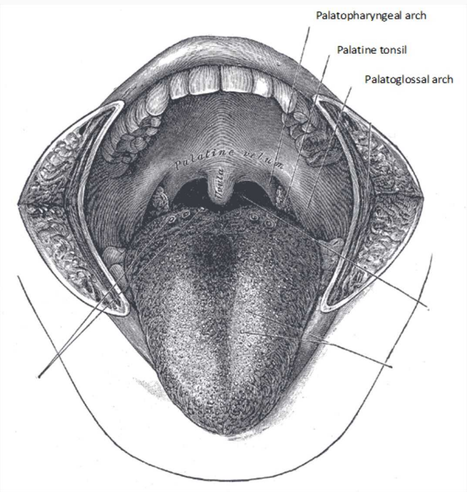

Modified by FRCEM Success. Original by Henry Vandyke Carter [Public domain], via Wikimedia Commons

Notes

Large collections of lymphoid tissue are found on the pharyngeal surface (posterior one-third) of the tongue and collectively known as the lingual tonsil.

The adenoid (pharyngeal) tonsil is a large collection of lymphoid tissue in the mucosa covering the roof of the nasopharynx.

The palatine tonsils are on the lateral walls of the oropharynx. On each side there is a large ovoid collection of lymphoid tissue in the mucosa lining the superior constrictor muscle, between the palatoglossal and palatopharyngeal arches and just posterior to the oropharyngeal isthmus.

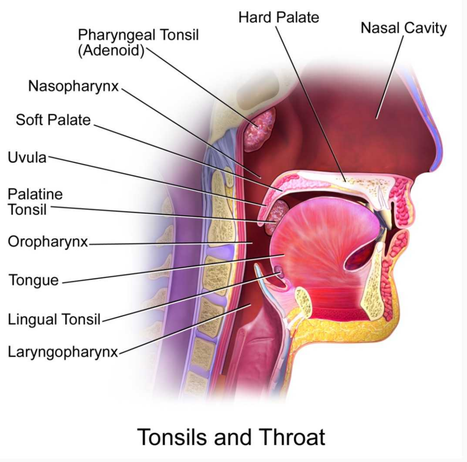

By Blausen.com staff. "Blausen gallery 2014". Wikiversity Journal of Medicine. DOI:10.15347/wjm/2014.010. ISSN 20018762. (Own work) [CC BY 3.0 (http://creativecommons.org/licenses/by/3.0)], via Wikimedia Commons

Blood supply

The palatine tonsils are highly vascular, receiving blood from the ascending palatine and tonsillar branches of the facial artery, the descending palatine branch of the maxillary artery, a palatine branch of the ascending pharyngeal artery and a branch of the lingual artery.

Tonsillectomy may result in severe haemorrhage, which may occur from the branches of the facial, ascending pharyngeal, maxillary and lingual arteries, or from paratonsillar veins.

Lymphatics

The lymphatic drainage of the palatine tonsils drains through the pharyngeal wall into the jugulodigastric nodes in the region where the facial vein drains into the internal jugular vein, inferior to the posterior belly of the digastric muscle.

< Previous | Next >

Something wrong?

Question Navigator

1 Answered
2 Answered
3 Answered
4 Answered
5 Answered
6 Answered
7 Answered
8 Answered
9 Answered
10 Answered
11 Current Question
12 Unanswered

Clear Exam

©2014 - 2017 FRCEM Success | Website designed & hosted by Cyberfrog Design

Anatomy: Neck

Question 12 of 78

A 73 year old man presents to ED with a longstanding ulceration to the tip of his tongue. Biopsy demonstrates squamous cell carcinoma. Which lymph nodes will most likely be involved in spread of the cancer cells:

a Pre-auricular

b Mastoid

c Jugulodigastric

d Jugulo-omohyoid

e Supraclavicular

< Previous | Next > | See Answer

Something wrong?

Question Navigator

1 Answered
2 Answered
3 Answered
4 Answered
5 Answered
6 Answered
7 Answered
8 Answered
9 Answered
10 Answered
11 Answered
12 Current Question

Clear Exam

©2014 - 2017 FRCEM Success | Website designed & hosted by Cyberfrog Design

Anatomy: Neck

Question 12 of 78

A 73 year old man presents to ED with a longstanding ulceration to the tip of his tongue. Biopsy demonstrates squamous cell carcinoma. Which lymph nodes will most likely be involved in spread of the cancer cells:

a) Pre-auricular ✗
b) Mastoid
c) Jugulodigastric
d) Jugulo-omohyoid ✓
e) Supraclavicular

Answer

The tip of the tongue drains either directly into or via superficial submental nodes into the jugulo-omohyoid deep cervical lymph node.

Notes

The deep cervical nodes form a chain along the internal jugular vein and are divided into upper and lower groups.

The most superior node in the upper group (lying where the posterior belly of the digastric muscle crosses the internal jugular vein) is the jugulodigastric node which receives lymphatic drainage from the tonsils and tonsillar region.

The most superior node in the lower group (lying just inferior to the intermediate tendon of the omohyoid muscle) is the jugulo-omohyoid node which receives lymphatic drainage from the tongue.

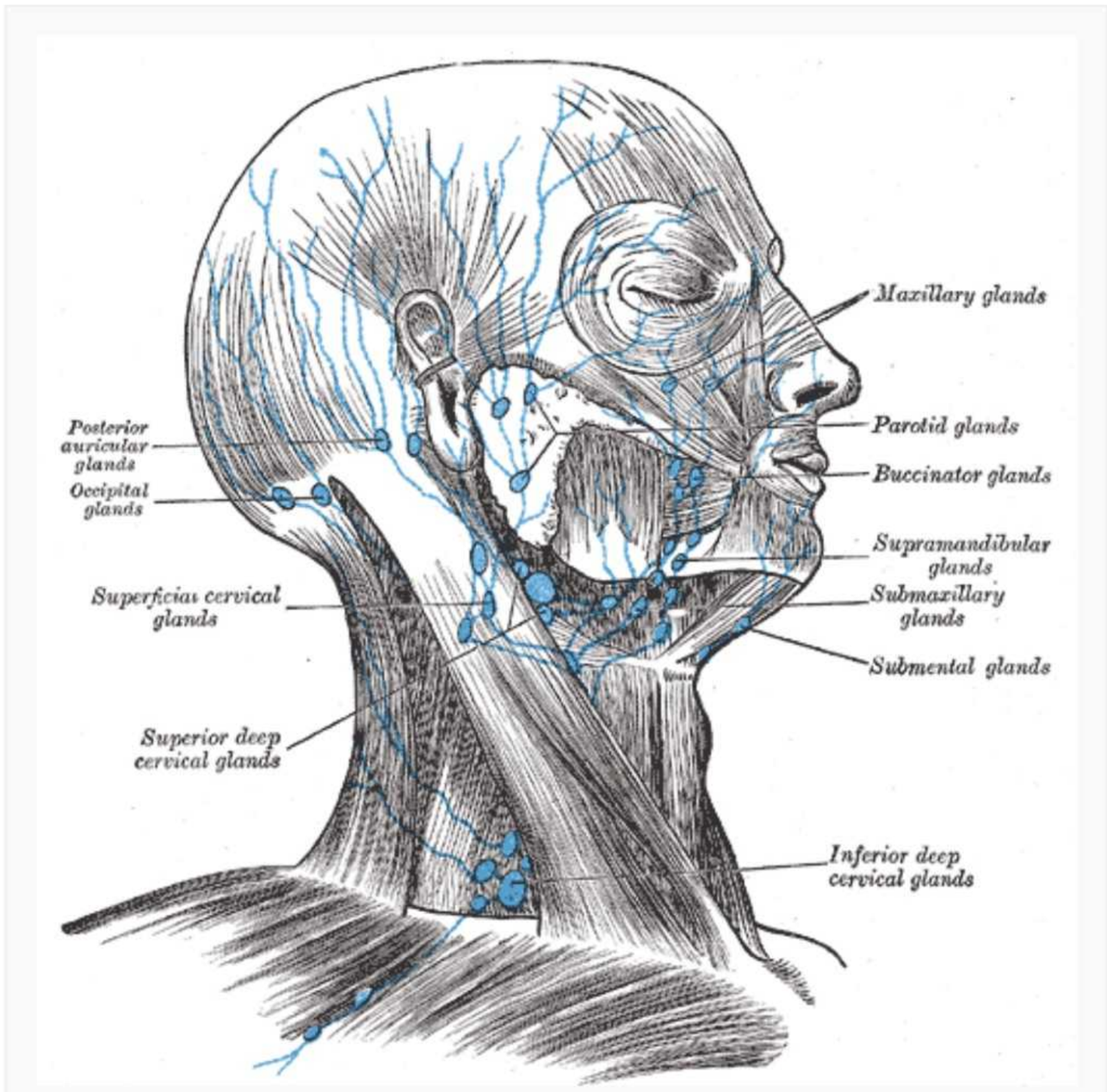

By Henry Vandyke Carter [Public domain], via Wikimedia Commons

< Previous | Next >

Something wrong?

Question Navigator

1 Answered
2 Answered
3 Answered
4 Answered
5 Answered
6 Answered
7 Answered
8 Answered
9 Answered
10 Answered
11 Answered
12 Current Question

Clear Exam

©2014 - 2017 FRCEM Success | Website designed & hosted by Cyberfrog Design

Anatomy: Neck

Question 13 of 78

Transection of the anterolateral tract of the spinal cord results in which of the following clinical features:

a Cerebellar incoordination

b Loss of pain and temperature sensation

c Loss of proprioception

d Loss of vibration and fine-touch sensation

e Complete flaccid paralysis

< Previous | Next > | See Answer

Something wrong?

Question Navigator

1 Answered
2 Answered
3 Answered
4 Answered
5 Answered
6 Answered
7 Answered
8 Answered
9 Answered
10 Answered
11 Answered
12 Answered

Clear Exam

©2014 - 2017 FRCEM Success | Website designed & hosted by Cyberfrog Design

Anatomy: Neck

Question 13 of 78

Transection of the anterolateral tract of the spinal cord results in which of the following clinical features:

a) **Cerebellar incoordination** ✗
b) Loss of pain and temperature sensation ✓
c) Loss of proprioception
d) Loss of vibration and fine-touch sensation
e) Complete flaccid paralysis

Answer

Transection of the anterolateral tract results in contralateral loss of pain and temperature sensations, starting one segment below the lesion.

Notes

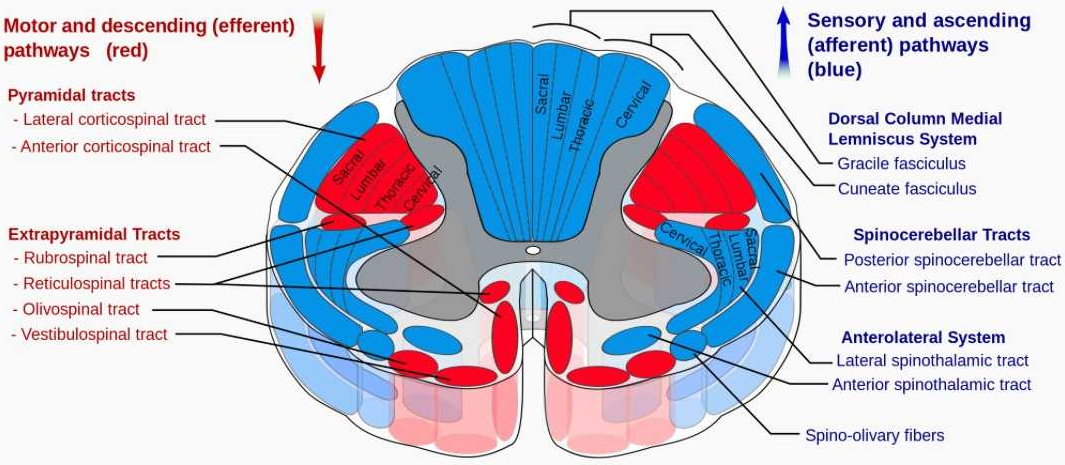

By Polarlys and Mikael Häggström [CC BY-SA 3.0 (http://creativecommons.org/licenses/by-sa/3.0) or GFDL (http://www.gnu.org/copyleft/fdl.html)], via Wikimedia Commons

Ascending tracts

The ascending spinal cord tracts represent functional pathways that convey sensory information from the periphery to higher levels.

Tract	Location	Function
Posterior column-medial lemniscus pathway (fasciculus gracilis and fasciculus cuneatus)	Posterior column	Transmits proprioception, vibration and fine-touch sensation
Anterior spinothalamic tract (decussates in spinal cord)	Anterior column	Transmits crude touch and pressure sensation
Lateral spinothalamic tract (decussates in spinal cord)	Lateral column (anterior aspect)	Transmits pain and temperature sensation

Question Navigator

1 Answered
2 Answered
3 Answered
4 Answered
5 Answered
6 Answered
7 Answered
8 Answered
9 Answered
10 Answered
11 Answered
12 Answered

Clear Exam

Posterior spinocerebellar tract	Lateral column (posterior aspect)	Transmits unconscious proprioceptive information to the cerebellum, involved in fine coordination of posture and movement of individual muscles of lower limb
Anterior spinocerebellar tract	Lateral column (anterior aspect)	Transmits unconscious proprioceptive information to the cerebellum, involved with coordination movement and posture of the entire lower limb

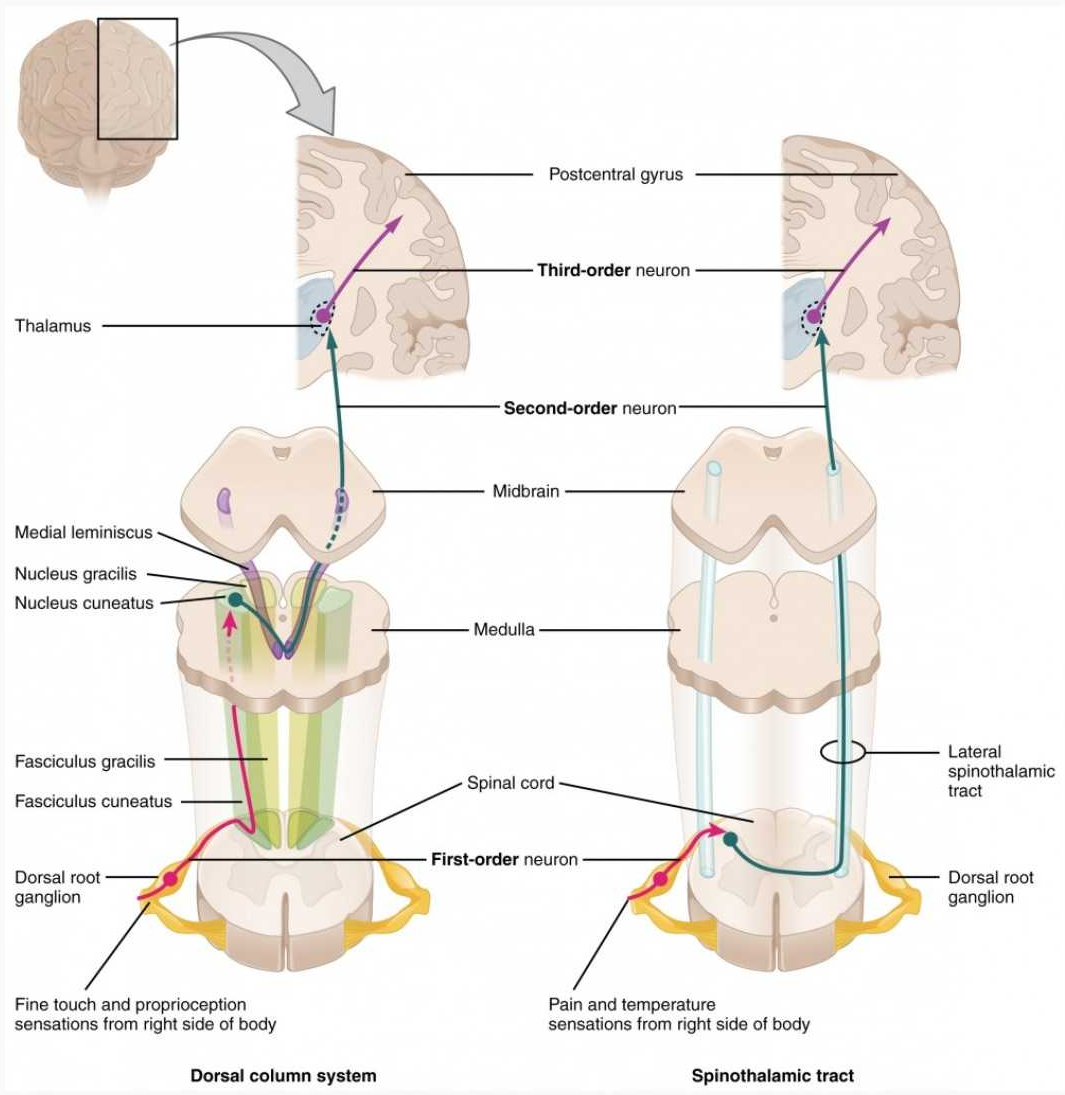

By OpenStax College [CC BY 3.0 (http://creativecommons.org/licenses/by/3.0)], via Wikimedia Commons

Descending tracts

The descending tracts are functional pathways concerned with somatic and visceral motor activities.

Tract	Location	Function
Lateral corticospinal tract	Lateral column (posterior aspect)	Involved in voluntary skilled motor activity of limbs
Anterior corticospinal tract (decussates in spinal cord)	Anterior column	Involved with control of axial muscles

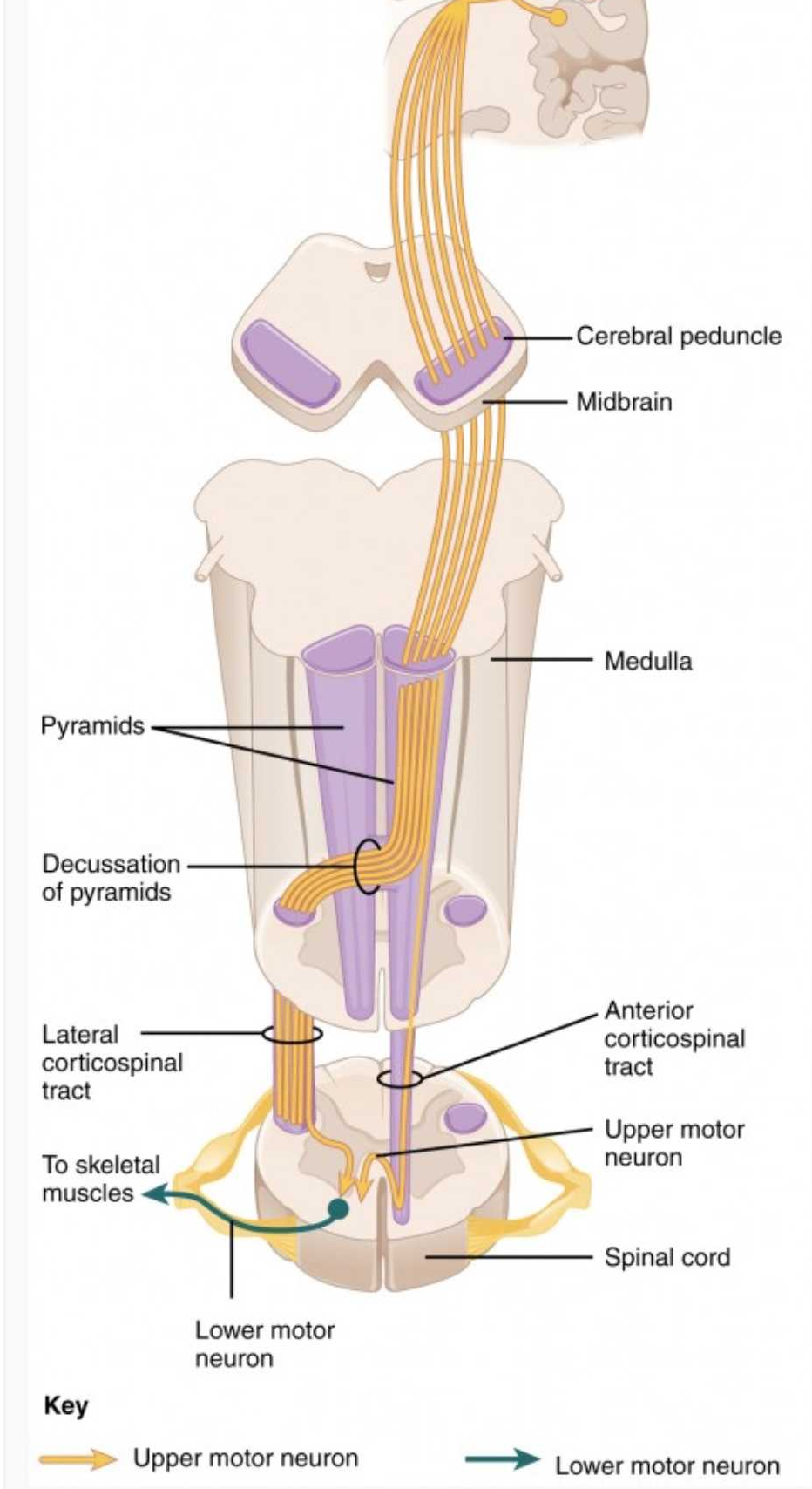

By OpenStax College [CC BY 3.0 (http://creativecommons.org/licenses/by/3.0)], via Wikimedia Commons

Clinical implications

Spinal cord syndrome	Mechanism	Tracts affected	Clinical features
Complete cord transection	Major trauma	All tracts	Death (C1 – C3), paralysis of voluntary/automatic breathing (above C5), quadriplegia (C4 – C5), paraplegia (below T1), UMN paralysis below lesion, complete sensory loss below lesion, urinary and faecal incontinence, anhidrosis and loss of vasomotor tone

Brown-Sequard syndrome (hemisection)	Penetrating trauma	All tracts on one side	Ipsilateral UMN paralysis below lesion, ipsilateral loss of proprioception/vibration/fine touch sensation below lesion, contralateral loss of crude touch/pain/temperature sensation below lesion, bilateral lower limb ataxia
Central cord syndrome	Hyperextension injury of cervical spine in patient with pre-existing cervical stenosis	Lateral corticospinal tract, spinothalamic tract	Bilateral sensory loss and UMN motor loss below lesion with greater loss in upper limbs than lower limbs, and greater loss of motor function than sensory function
Anterior cord syndrome	Occlusion of anterior spinal artery with infarction of territory supplied	Corticospinal, spinothalamic and spinocerebellar	Paralysis of voluntary/automatic breathing, faecal and urinary incontinence, bilateral Horner's syndrome, bilateral flaccid paralysis at level of lesion, bilateral spastic paralysis below lesion, bilateral loss of crude touch/pain/temperature sensation below lesion, cerebellar incoordination

Incomplete lesions of the spinal cord

Central Cord Syndrome

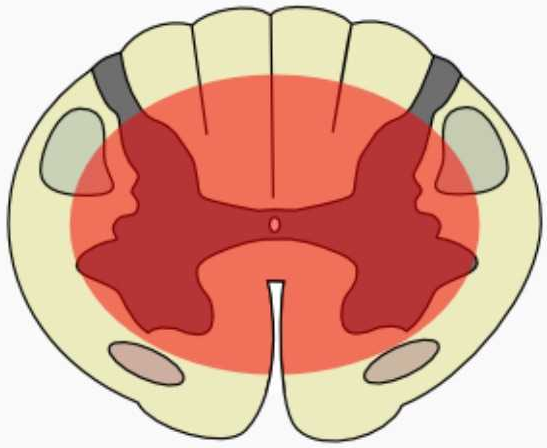

Anterior Cord Syndrome

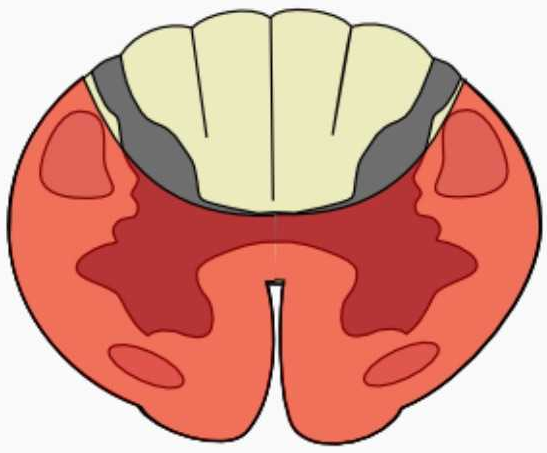

Brown-Séquard Syndrome

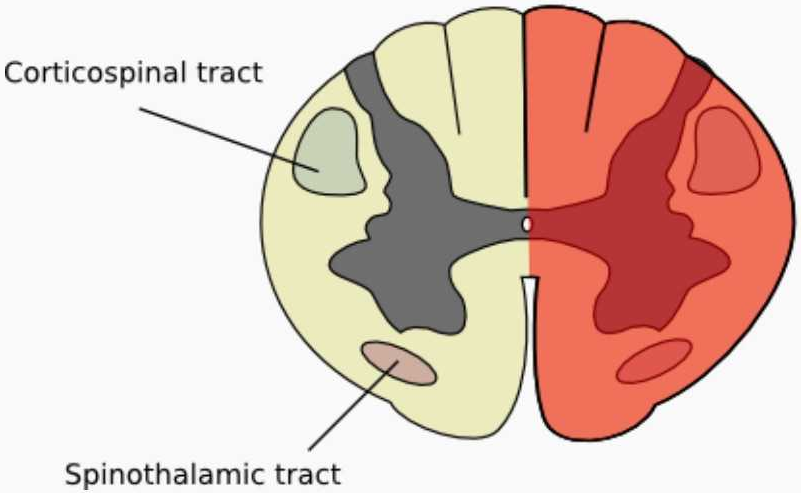

by Fpjacquot, via Wikimedia Commons

< Previous | Next >

Something wrong?

FRCEM Success

We are an online revision resource for FRCEM Primary and Intermediate exam preparation.

Terms & Conditions
Get in Touch

Resources

- The Royal College of Emergency Medicine
- Irish Association for Emergency Medicine
- Advanced Trauma Life Support
- Resuscitation Council (UK)
- TeachMeAnatomy
- Trauma.org
- Radiopaedia
- Advanced Life Support Group
- Emergency Medicine Journal
- Lifeinthefastlane
- Instant Anatomy
- Patient.co.uk

FRCEMSuccess

©2014 - 2017 FRCEM Success | Website designed & hosted by Cyberfrog Design

Anatomy: Neck

Question 14 of 78

Which of the following spinal tracts is involved with the control of trunk muscles:

a Anterior spinothalamic tract

b Lateral spinothalamic tract

c Posterior column

d Anterior corticospinal tract

e Posterior corticospinal tract

< Previous | Next > | See Answer

Something wrong?

Question Navigator

1 Answered
2 Answered
3 Answered
4 Answered
5 Answered
6 Answered
7 Answered
8 Answered
9 Answered
10 Answered
11 Answered
12 Answered

Clear Exam

©2014 - 2017 FRCEM Success | Website designed & hosted by Cyberfrog Design

Anatomy: Neck

Question 14 of 78

Which of the following spinal tracts is involved with the control of trunk muscles:

a) **Anterior spinothalamic tract** ✗
b) Lateral spinothalamic tract
c) Posterior column
d) Anterior corticospinal tract ✓
e) Posterior corticospinal tract

Question Navigator

1 Answered
2 Answered
3 Answered
4 Answered
5 Answered
6 Answered
7 Answered
8 Answered
9 Answered
10 Answered
11 Answered
12 Answered

Clear Exam

Answer

The anterior corticospinal tract is involved with the control of axial muscles.

Notes

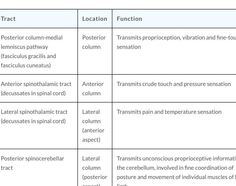

By Polarlys and Mikael Häggström [CC BY-SA 3.0 (http://creativecommons.org/licenses/by-sa/3.0) or GFDL (http://www.gnu.org/copyleft/fdl.html)], via Wikimedia Commons

Ascending tracts

The ascending spinal cord tracts represent functional pathways that convey sensory information from the periphery to higher levels.

Tract	Location	Function
Posterior column-medial lemniscus pathway (fasciculus gracilis and fasciculus cuneatus)	Posterior column	Transmits proprioception, vibration and fine-touch sensation
Anterior spinothalamic tract (decussates in spinal cord)	Anterior column	Transmits crude touch and pressure sensation
Lateral spinothalamic tract (decussates in spinal cord)	Lateral column (anterior aspect)	Transmits pain and temperature sensation
Posterior spinocerebellar tract	Lateral column (posterior aspect)	Transmits unconscious proprioceptive information to the cerebellum, involved in fine coordination of posture and movement of individual muscles of lower limb
Anterior spinocerebellar tract	Lateral column (anterior aspect)	Transmits unconscious proprioceptive information to the cerebellum, involved with coordination movement and posture of the entire lower limb

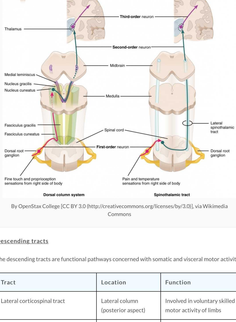

By OpenStax College [CC BY 3.0 (http://creativecommons.org/licenses/by/3.0)], via Wikimedia Commons

Descending tracts

The descending tracts are functional pathways concerned with somatic and visceral motor activities.

Tract	Location	Function
Lateral corticospinal tract	Lateral column (posterior aspect)	Involved in voluntary skilled motor activity of limbs
Anterior corticospinal tract (decussates in spinal cord)	Anterior column	Involved with control of axial muscles

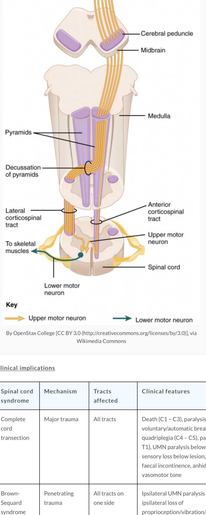

By OpenStax College [CC BY 3.0 (http://creativecommons.org/licenses/by/3.0)], via Wikimedia Commons

Clinical implications

Spinal cord syndrome	Mechanism	Tracts affected	Clinical features
Complete cord transection	Major trauma	All tracts	Death (C1 – C3), paralysis of voluntary/automatic breathing (above C5), quadriplegia (C4 – C5), paraplegia (below T1), UMN paralysis below lesion, complete sensory loss below lesion, urinary and faecal incontinence, anhidrosis and loss of vasomotor tone
Brown-Sequard syndrome (hemisection)	Penetrating trauma	All tracts on one side	Ipsilateral UMN paralysis below lesion, ipsilateral loss of proprioception/vibration/fine touch sensation below lesion, contralateral loss of crude touch/pain/temperature sensation below lesion, bilateral lower limb ataxia
Central cord syndrome	Hyperextension injury of cervical spine in patient with pre-existing cervical stenosis	Lateral corticospinal tract, spinothalamic tract	Bilateral sensory loss and UMN motor loss below lesion with greater loss in upper limbs than lower limbs, and greater loss of motor function than sensory function
Anterior cord syndrome	Occlusion of anterior spinal artery with infarction of territory supplied	Corticospinal, spinothalamic and spinocerebellar	Paralysis of voluntary/automatic breathing, faecal and urinary incontinence, bilateral Horner's syndrome, bilateral flaccid lesion below lesion, urinary and faecal incontinence, anhidrosis and loss of vasomotor tone

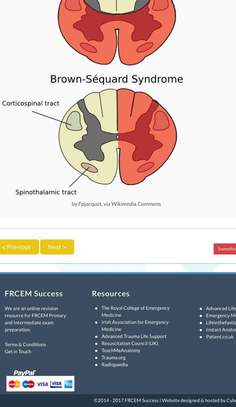

by Fjdacquot, via Wikimedia Commons

< Previous | Next >

Something wrong?

©2014 - 2017 FRCEM Success | Website designed & hosted by Cyberfrog Design

Anatomy: Neck

Question 15 of 78

Regarding Horner's syndrome, which of the following statements is CORRECT:

a Ptosis occurs due to paralysis of the levator palpebrae superioris muscle.

b Mydriasis is a typical feature.

c Miosis occurs due to paralysis of the dilator pupillae muscle.

d Horner's syndrome results from damage to secretomotor parasympathetic fibres.

e Horner's syndrome results from damage to the oculomotor nerve.

< Previous | Next > | See Answer

Something wrong?

Question Navigator

1 Answered
2 Answered
3 Answered
4 Answered
5 Answered
6 Answered
7 Answered
8 Answered
9 Answered
10 Answered
11 Answered
12 Answered

Clear Exam

©2014 - 2017 FRCEM Success | Website designed & hosted by Cyberfrog Design

Anatomy: Neck

Question 15 of 78

Regarding Horner's syndrome, which of the following statements is CORRECT:

a Ptosis occurs due to paralysis of the levator palpebrae superioris muscle.

b Mydriasis is a typical feature.

c Miosis occurs due to paralysis of the dilator pupillae muscle.

d Horner's syndrome results from damage to secretomotor parasympathetic fibres.

e Horner's syndrome results from damage to the oculomotor nerve.

< Previous | Next > | See Answer

Something wrong?

Question Navigator

1 Answered
2 Answered
3 Answered
4 Answered
5 Answered
6 Answered
7 Answered
8 Answered
9 Answered
10 Answered
11 Answered
12 Answered

Clear Exam

©2014 - 2017 FRCEM Success | Website designed & hosted by Cyberfrog Design

Anatomy: Neck

Question 15 of 78

Regarding Horner's syndrome, which of the following statements is CORRECT:

a) Ptosis occurs due to paralysis of the levator palpebrae superioris muscle. ✗

b) Mydriasis is a typical feature.

c) Miosis occurs due to paralysis of the dilator pupillae muscle. ✓

d) Horner's syndrome results from damage to secretomotor parasympathetic fibres.

e) Horner's syndrome results from damage to the oculomotor nerve.

Answer

Horner's syndrome is characterised by pupil constriction, partial ptosis and anhidrosis.

Notes

The sympathetic trunks are two parallel cords that run from the base of the skull to the coccyx. Along the way they are punctuated by ganglia, collections of neuronal cell bodies outside of the CNS. The cervical part of the sympathetic trunk is anterior to the longus colli and longus capitis muscles and posterior to the common carotid artery in the carotid sheath.

There are three ganglia along the course of the sympathetic trunk in the cervical region within which ascending preganglionic sympathetic fibres from upper thoracic spinal cord levels synapse with postganglionic sympathetic fibres. The postganglionic fibres are distributed from these ganglia in branches, called grey rami communicantes, which connect with cervical spinal nerves C1 – C8.

Superior cervical ganglion

The superior cervical ganglion is responsible for sympathetic innervation to the structures in the head and neck. The superior cervical ganglion lies in the area of vertebrae C1 – C2 and has branches to:

- the internal and external carotid arteries
- the cervical spinal nerves C1 – C4
- the pharynx
- the heart.

Middle cervical ganglion

The middle cervical ganglion lies in the area of vertebra C6 and has branches to:

- cervical spinal nerves C5 – C6
- the heart.

Inferior cervical ganglion

The inferior cervical ganglion lies in the area of vertebra C7 (anterior to the neck of rib I, posterior to the first part of the subclavian artery), combines with the first thoracic ganglion to form the cervicothoracic ganglion and has branches to:

- spinal nerves C7 – T1
- the vertebral and subclavian artery
- the heart.

This ganglion may also receive white rami communicantes from thoracic spinal nerves T1 – T2.

Horner's syndrome

The sympathetic fibres can be stretched or damage along their course and if unilaterally disturbed may produce Horner's syndrome, a triad of partial ptosis (due to paralysis of the superior tarsal muscle), miosis (due to paralysis of the dilator pupillae muscle) and anhidrosis (due to loss of innervation to the sweat glands).

Secondary changes may also include ipsilateral vasodilation (due to loss of sympathetic control of subcutaneous blood vessels) and enophthalmos (due to paralysis of the orbitalis muscle).

Possible causes of Horner's syndrome include:

- Apical lung tumour (Pancoast's tumour) eroding the cervicothoracic ganglion
- Thyroid carcinoma
- Penetrating injury to neck
- Lymphadenopathy
- Cervical rib
- Injury to carotid arteries

< Previous | Next >

Something wrong?

Question Navigator

1 Answered
2 Answered
3 Answered
4 Answered
5 Answered
6 Answered
7 Answered
8 Answered
9 Answered
10 Answered
11 Answered
12 Answered

Clear Exam

©2014 - 2017 FRCEM Success | Website designed & hosted by Cyberfrog Design

Anatomy: Neck

Question 16 of 78

The sensory innervation of the laryngopharynx is provided by which of the following nerves:

a Glossopharyngeal nerve

b Maxillary nerve

c Mandibular nerve

d Facial nerve

e Vagus nerve

< Previous | Next > | See Answer

Something wrong?

Question Navigator

1 Answered
2 Answered
3 Answered
4 Answered
5 Answered
6 Answered
7 Answered
8 Answered
9 Answered
10 Answered
11 Answered
12 Answered

Clear Exam

©2014 - 2017 FRCEM Success | Website designed & hosted by Cyberfrog Design

Anatomy: Neck

Question 16 of 78

The sensory innervation of the laryngopharynx is provided by which of the following nerves:

a) Glossopharyngeal nerve
b) Maxillary nerve
c) **Mandibular nerve** ✖
d) Facial nerve
e) Vagus nerve ✔

Answer

Each subdivision of the pharynx has a different sensory innervation:

- the nasopharynx is innervated by the maxillary nerve
- the oropharynx is innervated by the glossopharyngeal nerve
- the laryngopharynx is innervated by the vagus nerve.

Notes

The pharynx is a musculofascial structure that connects the oral and nasal cavities in the head to the larynx and the oesophagus in the neck.

The pharynx is attached above to the base of the skull, and is continuous below, approximately at the level of vertebra C6, with the top of the oesophagus.

The pharynx is separated from the posterior vertebral column by a thin retropharyngeal space, bordered anteriorly by the buccopharyngeal fascia and posteriorly by the prevertebral fascia.

Arrangement

The walls of the pharynx are attached anteriorly to the margins of the nasal cavities, oral cavity and larynx, dividing the pharynx into the continuous nasopharynx, oropharynx and laryngopharynx respectively.

The posterior apertures of the nasal cavities open into the nasopharynx, the oropharyngeal isthmus opens into the oropharynx and the superior aperture of the larynx opens into the laryngopharynx.

The pharyngotympanic tubes (from the middle ear) open into the lateral walls of the nasopharynx.

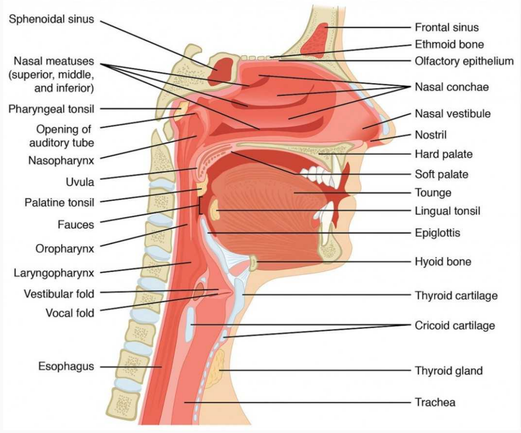

By OpenStax College [CC BY 3.0], via Wikimedia Commons

Muscles

The muscles of the pharyngeal wall are organised into two groups.

The three sheet-like constrictor muscles constrict the pharyngeal cavity sequentially to move a bolus of food through the pharynx and into the oesophagus during swallowing.

The three longitudinal muscles elevate the pharyngeal wall, or during swallowing, pull the pharyngeal wall up and over a bolus of food being moved through the pharynx into the oesophagus.

Nerve supply

The muscles of the pharynx are all innervated by the vagus nerve except for the stylopharyngeus muscle, innervated by the glossopharyngeal nerve. The branches of the vagus and glossopharyngeal nerves form a pharyngeal plexus in the outer fascia of the pharyngeal wall.

Each subdivision of the pharynx has a different sensory innervation:

- the nasopharynx is innervated by the maxillary nerve
- the oropharynx is innervated by the glossopharyngeal nerve
- the laryngopharynx is innervated by the vagus nerve.

Lymphatics

Lymphatic vessels from the pharynx drain into the deep cervical lymph nodes.

< Previous | Next >

Something wrong?

Question Navigator

1 Answered
2 Answered
3 Answered
4 Answered
5 Answered
6 Answered
7 Answered
8 Answered
9 Answered
10 Answered
11 Answered
12 Answered

Clear Exam

©2014 - 2017 FRCEM Success | Website designed & hosted by Cyberfrog Design

Anatomy: Neck

Question 17 of 78

Regarding the vertebrae, which of the following statements is CORRECT:

a There are 28 vertebrae in the human spine.

b There are 8 cervical vertebrae.

c The vertebral arch is anchored to the posterior surface of the vertebral body by two laminae.

d The transverse process is the site of articulation with the ribs in the thoracic region.

e The spinous process projects posteriorly and inferiorly from the vertebral body.

< Previous | Next > | See Answer

Something wrong?

Question Navigator

1 Answered
2 Answered
3 Answered
4 Answered
5 Answered
6 Answered
7 Answered
8 Answered
9 Answered
10 Answered
11 Answered
12 Answered

Clear Exam

©2014 - 2017 FRCEM Success | Website designed & hosted by Cyberfrog Design

Anatomy: Neck

Question 17 of 78

Regarding the vertebrae, which of the following statements is CORRECT:

a) There are 28 vertebrae in the human spine.

b) There are 8 cervical vertebrae.

c) ✖

The vertebral arch is anchored to the posterior surface of the vertebral body by two laminae.

d) The transverse process is the site of articulation with the ribs in the thoracic region. ✔

e) The spinous process projects posteriorly and inferiorly from the vertebral body.

Answer

On each side of the vertebral arch, a transverse process extends laterally from the region where a lamina meets a pedicle and is a site for articulation with ribs in the thoracic region.

Notes

The vertebral column consists of 33 vertebrae: seven cervical, twelve thoracic, five lumbar, five fused sacral and four fused coccygeal vertebrae.

A typical vertebra consists of a vertebral body and a vertebral arch.

The vertebral body is anterior and is separated from adjacent vertebral bodies by fibrocartilaginous intervertebral discs. The size of the vertebral body increases inferiorly as the amount of weight supported increases.

The vertebral arch is anchored to the posterior surface of the vertebral body by two pedicles, which form the lateral pillars of the arch. The roof of the vertebral arch is formed by the right and left laminae which fuse at the midline.

A spinous process projects posteriorly and inferiorly from the roof of the vertebral arch and is a site for muscle and ligament attachment.

On each side of the vertebral arch, a transverse process extends laterally from the region where a lamina meets a pedicle and is a site for articulation with ribs in the thoracic region. From the same region, a superior articular process and an inferior articular process articulate with similar processes on adjacent vertebrae.

The vertebral arches are aligned to form the lateral and posterior walls of the vertebral foramen; the vertebral foramina of all the vertebrae together form the vertebral canal.

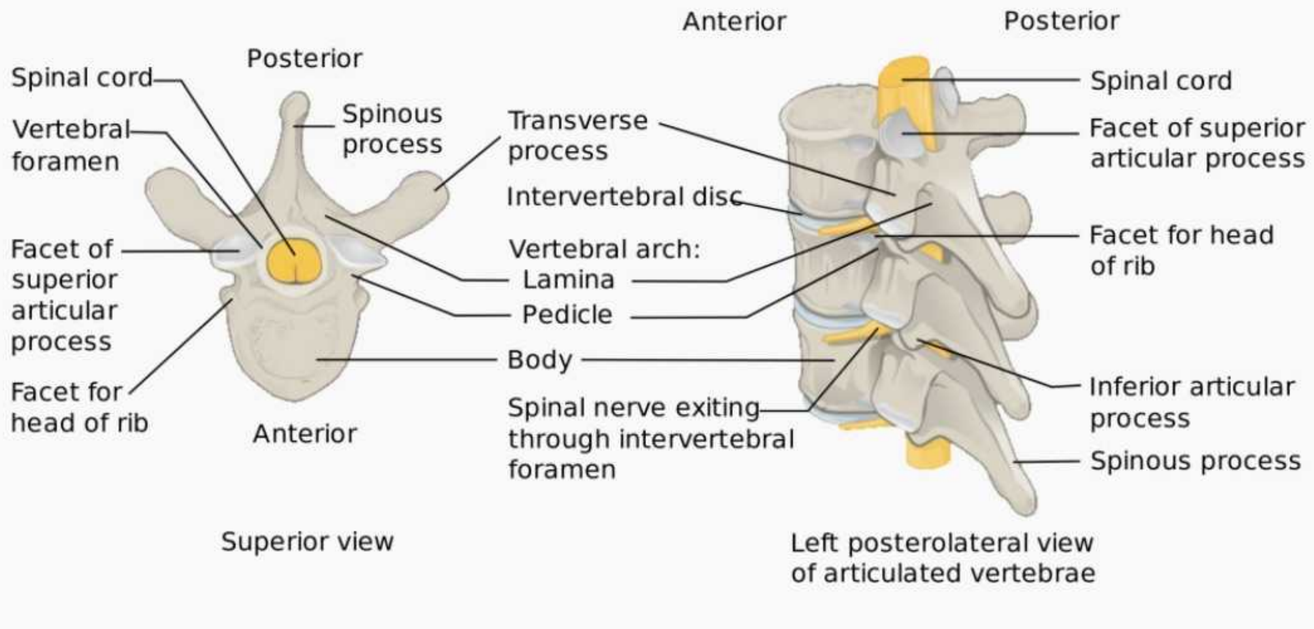

By Jmarchn (Own work) [CC BY-SA 3.0], via Wikimedia Commons

< Previous | Next >

Something wrong?

Question Navigator

1 Answered
2 Answered
3 Answered
4 Answered
5 Answered
6 Answered
7 Answered
8 Answered
9 Answered
10 Answered
11 Answered
12 Answered

Clear Exam

©2014 - 2017 FRCEM Success | Website designed & hosted by Cyberfrog Design

Anatomy: Neck

Question 18 of 78

Regarding the neck fascia, which of the following statements is CORRECT:

a The investing layer of the deep fascia lies deep to the pretracheal layer.

b The thyroid gland lies anterior to the pretracheal layer.

c The deep fascia is further divided into two layers.

d The vagus nerve is contained within the carotid sheath.

e The pretracheal space communicates directly with the posterior mediastinum.

< Previous | Next > | See Answer

Something wrong?

Question Navigator

1 Answered
2 Answered
3 Answered
4 Answered
5 Answered
6 Answered
7 Answered
8 Answered
9 Answered
10 Answered
11 Answered
12 Answered

Clear Exam

©2014 - 2017 FRCEM Success | Website designed & hosted by Cyberfrog Design

Anatomy: Neck

Question 18 of 78

Regarding the neck fascia, which of the following statements is CORRECT:

a) The investing layer of the deep fascia lies deep to the pretracheal layer.
b) The thyroid gland lies anterior to the pretracheal layer.
c) **The deep fascia is further divided into two layers.** ✘
d) The vagus nerve is contained within the carotid sheath. ✔
e) The pretracheal space communicates directly with the posterior mediastinum.

Answer

The carotid sheath contains the common carotid artery, the internal carotid artery, the internal jugular vein and the vagus nerve.

Notes

Neck fascia

The neck fascia is divided into the superficial and deep fascia.

The deep fascia is further divided into:

- 1) an investing layer (blue) which lies deep to the superficial fascia and surrounds all structures in the neck
- 2) the prevertebral layer (green) which surrounds the vertebral column and the deep muscles associated with the back
- 3) the pretracheal layer (yellow) which encloses the viscera of the neck (the trachea, oesophagus and thyroid)
- 4) the carotid sheaths (red) which receive a contribution from the other three fascial layers and surround the two major neurovascular bundles on either side of the neck (containing the common carotid artery, the internal carotid artery, the internal jugular vein and the vagus nerve).

The trapezius and sternocleidomastoid muscles lie within the investing layer of the deep cervical fascia.

The viscera of the neck lie anterior to the prevertebral fascia, within the pretracheal layer.

The prevertebral muscles lie within the prevertebral fascial layer and act as weak neck flexors.

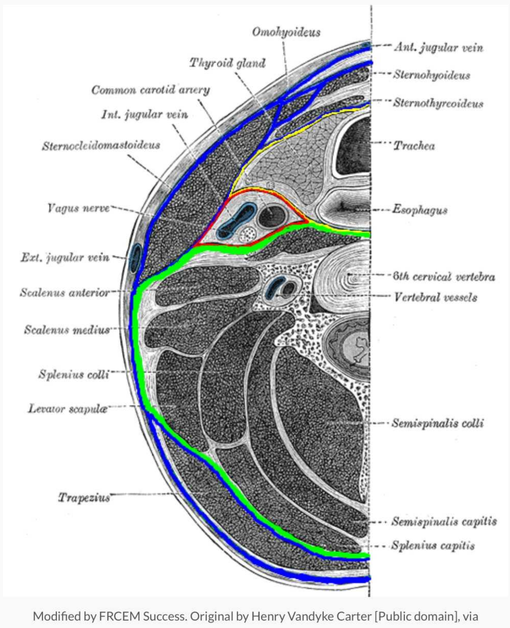

Modified by FRCEM Success. Original by Henry Vandyke Carter [Public domain], via Wikimedia Commons

Neck spaces

Between the fascial layers in the neck are spaces that may provide a conduit for the spread of infections from the neck to the mediastinum:

The pretracheal space lies between the investing layer of cervical fascia and the pretracheal fascia and passes between the neck and the anterior part of the superior mediastinum.

The retropharyngeal space lies between the buccopharyngeal fascia (the part of the pretracheal fascia posterior to the pharynx) and the prevertebral fascia and extends from the base of the skull to the upper part of the posterior mediastinum.

The prevertebral space is within the prevertebral layer as it splits into two laminae, extending from the base of the skull and extends through the posterior mediastinum to the diaphragm.

< Previous | Next >

Something wrong?

Question Navigator

1 Answered
2 Answered
3 Answered
4 Answered
5 Answered
6 Answered
7 Answered
8 Answered
9 Answered
10 Answered
11 Answered
12 Answered

Clear Exam

©2014 - 2017 FRCEM Success | Website designed & hosted by Cyberfrog Design

Anatomy: Neck

Question 19 of 78

Regarding the cervical sympathetic trunk, which of the following statements is CORRECT:

a The preganglionic sympathetic fibres originate from spinal cord segments C4 – C8.

b The sympathetic trunk lies anterior to the carotid sheath in the neck.

c The postganglionic sympathetic fibres pass from the sympathetic trunk in gray rami communicantes to connect with the cervical spinal nerves.

d There are five main ganglia along the course of the sympathetic trunk in the cervical region.

e Horner's syndrome is characterised by pupil constriction and complete ptosis.

< Previous | Next > | See Answer

Something wrong?

Question Navigator

1 Answered
2 Answered
3 Answered
4 Answered
5 Answered
6 Answered
7 Answered
8 Answered
9 Answered
10 Answered
11 Answered
12 Answered

Clear Exam

©2014 - 2017 FRCEM Success | Website designed & hosted by Cyberfrog Design

Anatomy: Neck

Question 19 of 78

Regarding the cervical sympathetic trunk, which of the following statements is CORRECT:

a) The preganglionic sympathetic fibres originate from spinal cord segments C4 – C8.
b) The sympathetic trunk lies anterior to the carotid sheath in the neck.
c) ✔
The postganglionic sympathetic fibres pass from the sympathetic trunk in gray rami communicantes to connect with the cervical spinal nerves.
d) There are five main ganglia along the course of the sympathetic trunk in the cervical region.
e) Horner's syndrome is characterised by pupil constriction and complete ptosis.

Answer

There are three ganglia along the course of the sympathetic trunk in the cervical region within which ascending preganglionic sympathetic fibres from upper thoracic spinal cord levels synapse with postganglionic sympathetic fibres. The postganglionic fibres are distributed from these ganglia in branches, called grey rami communicantes, which connect with cervical spinal nerves C1 – C8. Horner's syndrome is characterised by constant partial ptosis due to paralysis of the superior tarsal muscle (not complete ptosis as the levator palpebrae superioris muscle function is preserved).

Notes

The sympathetic trunks are two parallel cords that run from the base of the skull to the coccyx. Along the way they are punctuated by ganglia, collections of neuronal cell bodies outside of the CNS. The cervical part of the sympathetic trunk is anterior to the longus colli and longus capitis muscles and posterior to the common carotid artery in the carotid sheath.

There are three ganglia along the course of the sympathetic trunk in the cervical region within which ascending preganglionic sympathetic fibres from upper thoracic spinal cord levels synapse with postganglionic sympathetic fibres. The postganglionic fibres are distributed from these ganglia in branches, called grey rami communicantes, which connect with cervical spinal nerves C1 – C8.

Superior cervical ganglion

The superior cervical ganglion is responsible for sympathetic innervation to the structures in the head and neck. The superior cervical ganglion lies in the area of vertebrae C1 – C2 and has branches to:

- the internal and external carotid arteries
- the cervical spinal nerves C1 – C4
- the pharynx
- the heart.

Middle cervical ganglion

The middle cervical ganglion lies in the area of vertebra C6 and has branches to:

- cervical spinal nerves C5 – C6
- the heart.

Inferior cervical ganglion

The inferior cervical ganglion lies in the area of vertebra C7 (anterior to the neck of rib I, posterior to the first part of the subclavian artery), combines with the first thoracic ganglion to form the cervicothoracic ganglion and has branches to:

- spinal nerves C7 – T1
- the vertebral and subclavian artery
- the heart.

This ganglion may also receive white rami communicantes from thoracic spinal nerves T1 – T2.

Horner's syndrome

The sympathetic fibres can be stretched or damage along their course and if unilaterally disturbed may produce Horner's syndrome, a triad of partial ptosis (due to paralysis of the superior tarsal muscle), miosis (due to paralysis of the dilator pupillae muscle) and anhidrosis (due to loss of innervation to the sweat glands).

Secondary changes may also include ipsilateral vasodilation (due to loss of sympathetic control of subcutaneous blood vessels) and enophthalmos (due to paralysis of the orbitalis muscle).

Possible causes of Horner's syndrome include:

- Apical lung tumour (Pancoast's tumour) eroding the cervicothoracic ganglion
- Thyroid carcinoma
- Penetrating injury to neck
- Lymphadenopathy
- Cervical rib
- Injury to carotid arteries

< Previous | Next >

Something wrong?

Question Navigator

1 Answered
2 Answered
3 Answered
4 Answered
5 Answered
6 Answered
7 Answered
8 Answered
9 Answered
10 Answered
11 Answered
12 Answered

Clear Exam

©2014 - 2017 FRCEM Success | Website designed & hosted by Cyberfrog Design

Anatomy: Neck

Question 20 of 78

The larynx blends inferiorly with the trachea at which of the following vertebral levels:

a C3

b C4

c C5

d C6

e C7

< Previous | Next > | See Answer

Something wrong?

Question Navigator

1 Answered
2 Answered
3 Answered
4 Answered
5 Answered
6 Answered
7 Answered
8 Answered
9 Answered
10 Answered
11 Answered
12 Answered

Clear Exam

©2014 - 2017 FRCEM Success | Website designed & hosted by Cyberfrog Design

Anatomy: Neck

Question 20 of 78

The larynx blends inferiorly with the trachea at which of the following vertebral levels:

a) C3
b) C4 ✗
c) C5
d) C6 ✓
e) C7

Answer

The larynx is suspended from the superior hyoid bone and attached to the trachea below by membranes and ligaments. It opens above into the pharynx immediately posterior and slightly inferior to the tongue and the oropharyngeal isthmus of the oral cavity, and blends inferiorly with the trachea at the vertebral level C6.

Notes

The larynx is suspended from the superior hyoid bone and attached to the trachea below by membranes and ligaments. It opens above into the pharynx immediately posterior and slightly inferior to the tongue and the oropharyngeal isthmus of the oral cavity, and blends inferiorly with the trachea at the vertebral level C6.

Function

There are four principal roles of the larynx:

- phonation
- sphincteric to close the lower respiratory tract (for example during swallowing)
- coughing
- breath-holding while straining (vocal cord adduction).

Laryngeal muscles

The laryngeal muscles are divided into intrinsic and extrinsic groups.

The intrinsic muscles alter the size and shape of the laryngeal inlet and move the vocal folds.

The extrinsic muscles are involved in elevation and depression of the larynx to produce swallowing.

Innervation

Motor and sensory innervation of the larynx is provided by the vagus nerve via its superior laryngeal and recurrent laryngeal branches.

The recurrent laryngeal nerves are sensory to the laryngeal cavity below the level of the vocal folds and motor to all intrinsic muscles of the larynx except for the cricothyroid muscle (innervated by the superior laryngeal branch of the vagus nerve).

A lesion of the recurrent laryngeal nerve may cause respiratory obstruction, hoarseness, inability to speak and loss of sensation below the vocal cord.

The superior laryngeal nerve supplies sensation to the mucous membrane above the vocal cord and the taste buds on the epiglottis, and motor innervation to the cricothyroid and the inferior pharyngeal constrictor muscles.

A lesion of the superior laryngeal nerve may cause loss of sensation above the vocal cord and taste on the epiglottis, and a weak hoarse voice.

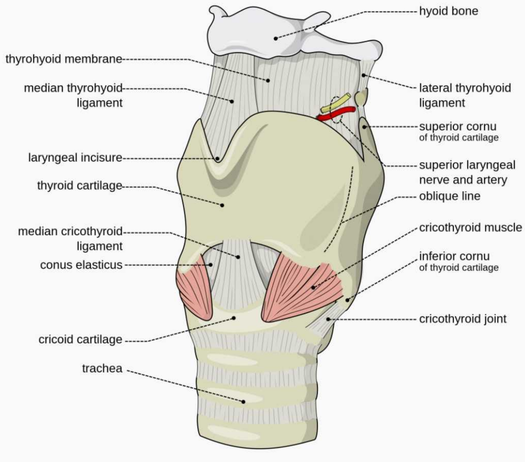

By Olek Remesz (wiki-pl: Orem, commons: Orem) [CC BY-SA 2.5-2.0-1.0], via Wikimedia Commons

< Previous | Next > | Something wrong?

Question Navigator

1 Answered
2 Answered
3 Answered
4 Answered
5 Answered
6 Answered
7 Answered
8 Answered
9 Answered
10 Answered
11 Answered
12 Answered

Clear Exam

©2014 - 2017 FRCEM Success | Website designed & hosted by Cyberfrog Design

Anatomy: Neck

Question 21 of 78

Regarding the subclavian artery, which of the following statement is INCORRECT:

a The right subclavian artery begins posterior to the sternoclavicular joint.

b The left and right subclavian arteries are direct branches of the arch of the aorta.

c The subclavian artery passes anterior to the extension of the pleural cavity in the root of the neck.

d The subclavian artery passes posterior to the scalenus anterior muscle.

e The subclavian artery becomes the axillary artery as it crosses the lateral border of rib I.

< Previous | Next > | See Answer

Something wrong?

Question Navigator

1 Answered
2 Answered
3 Answered
4 Answered
5 Answered
6 Answered
7 Answered
8 Answered
9 Answered
10 Answered
11 Answered
12 Answered

Clear Exam

©2014 - 2017 FRCEM Success | Website designed & hosted by Cyberfrog Design

Anatomy: Neck

Question 21 of 78

Regarding the subclavian artery, which of the following statement is INCORRECT:

a) **The right subclavian artery begins posterior to the sternoclavicular joint.** ✗
b) The left and right subclavian arteries are direct branches of the arch of the aorta. ✓
c) The subclavian artery passes anterior to the extension of the pleural cavity in the root of the neck.
d) The subclavian artery passes posterior to the scalenus anterior muscle.
e) The subclavian artery becomes the axillary artery as it crosses the lateral border of rib I.

Answer

The right subclavian artery begins posterior to the sternoclavicular joint as a branch of the brachiocephalic trunk. The left subclavian artery begins more inferiorly as a direct branch of the arch of the aorta and ascends posterior to the left common carotid artery.

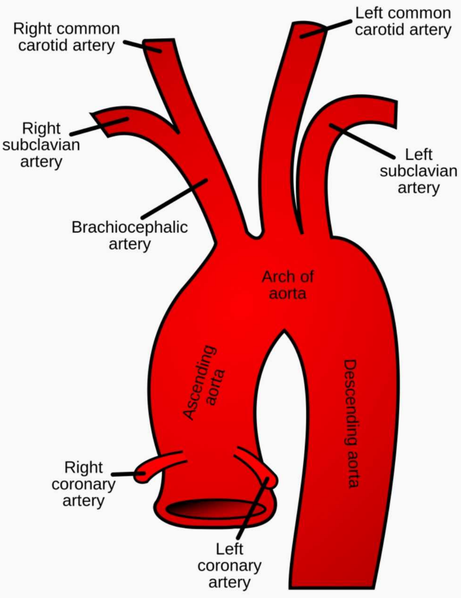

By Henry Vandyke Carter [Public domain or Public domain], via Wikimedia Commons

Notes

The subclavian arteries on both sides arch upward out of the thorax to enter the root of the neck.

The right subclavian artery begins posterior to the sternoclavicular joint as a branch of the brachiocephalic trunk.

The left subclavian artery begins more inferiorly as a direct branch of the arch of the aorta and ascends posterior to the left common carotid artery.

Each subclavian artery arches superiorly and laterally to pass anterior to the extension of the pleural cavity in the root of the neck and posterior to the anterior scalene muscle, becoming the axillary artery as it crosses the lateral border of rib I.

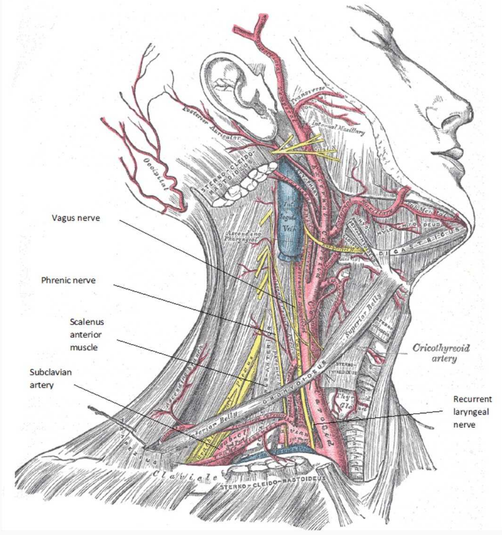

Modified by FRCEM Success. Original by Henry Vandyke Carter [Public domain], via Wikimedia Commons

< Previous | Next >

Something wrong?

Question Navigator

1 Answered
2 Answered
3 Answered
4 Answered
5 Answered
6 Answered
7 Answered
8 Answered
9 Answered
10 Answered
11 Answered
12 Answered

Clear Exam

©2014 - 2017 FRCEM Success | Website designed & hosted by Cyberfrog Design

Anatomy: Neck

Question 22 of 78

The sternocleidomastoid muscle is primarily innervated by which of the following nerves:

a Long thoracic nerve

b Accessory nerve (CN XI)

c Thoracodorsal nerve

d Transverse cervical nerve

e Lesser occipital nerve

< Previous | Next > | See Answer

Something wrong?

Question Navigator

1 Answered
2 Answered
3 Answered
4 Answered
5 Answered
6 Answered
7 Answered
8 Answered
9 Answered
10 Answered
11 Answered
12 Answered

Clear Exam

©2014 - 2017 FRCEM Success | Website designed & hosted by Cyberfrog Design

Anatomy: Neck

Question 22 of 78

The sternocleidomastoid muscle is primarily innervated by which of the following nerves:

a) **Long thoracic nerve** ✗
b) Accessory nerve (CN XI) ✓
c) Thoracodorsal nerve
d) Transverse cervical nerve
e) Lesser occipital nerve

Answer

The sternocleidomastoid is innervated by the accessory nerve (CN XI) and by branches of anterior rami of C2 – C3.

Notes

Muscle	Sternocleidomastoid
Origin	• Sternal head: anterior manubrium of sternum • Clavicular head: medial one-third of clavicle
Insertion	• Sternal head: lateral one-half of superior nuchal line • Clavicular head: lateral mastoid process
Innervation	Accessory nerve (and by branches of anterior rami of C2 – C3)
Action	• Acting unilaterally: lateral rotation of head towards same side and rotation of head towards opposite side • Acting bilaterally: dorsal extension of head

The sternocleidomastoid muscle has two heads; the sternal head originates from the upper part of the anterior manubrium of the sternum and inserts onto the lateral one-half of the superior nuchal line (occipital bone) and the clavicular head originates from the superior surface of the medial one-third of the clavicle and inserts onto the lateral surface of the mastoid process (temporal bone).

The sternocleidomastoid is innervated by the accessory nerve (CN XI) and by branches of anterior rami of C2 – C3.

Individually each muscle will tilt the head towards the shoulder on the same side (lateral flexion) and rotate the head to turn to face the opposite side. Acting together the muscles draw the head forward, through extension of the neck at the atlanto-occipital joints (dorsal extension).

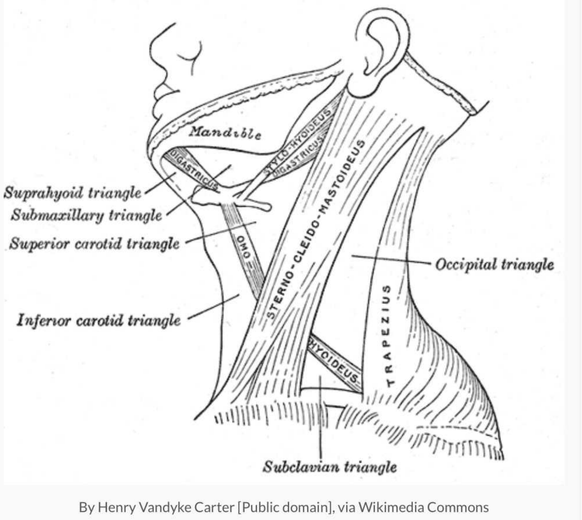

By Henry Vandyke Carter [Public domain], via Wikimedia Commons

< Previous | Next >

Something wrong?

Question Navigator

1 Answered
2 Answered
3 Answered
4 Answered
5 Answered
6 Answered
7 Answered
8 Answered
9 Answered
10 Answered
11 Answered
12 Answered

Clear Exam

©2014 - 2017 FRCEM Success | Website designed & hosted by Cyberfrog Design

Anatomy: Neck

Question 23 of 78

A 23 year old man is involved in a road traffic collision and sustains a lumbar fracture. On examination you note he is unable to extend his big toe. Which of the following spinal nerve roots has most likely been affected:

a L3

b L4

c L5

d S1

e S2

< Previous | Next > | See Answer

Something wrong?

Question Navigator

1 Answered
2 Answered
3 Answered
4 Answered
5 Answered
6 Answered
7 Answered
8 Answered
9 Answered
10 Answered
11 Answered
12 Answered

Clear Exam

©2014 - 2017 FRCEM Success | Website designed & hosted by Cyberfrog Design

Anatomy: Neck

Question 23 of 78

A 23 year old man is involved in a road traffic collision and sustains a lumbar fracture. On examination you note he is unable to extend his big toe. Which of the following spinal nerve roots has most likely been affected:

a) L3 ✗
b) L4
c) L5 ✓
d) S1
e) S2

Answer

The L5 nerve root has most likely been affected.

Notes

Upper limb

Myotome	Movement most strongly associated with myotome
C5	Shoulder abduction
C6	Elbow flexion/wrist extension
C7	Elbow extension/wrist flexion
C8	Finger flexion
T1	Finger abduction

Muscle movement	Nerve root(s)
Shoulder abduction	C5
Shoulder adduction	C5 – C7
Elbow flexion	C5 – C6
Elbow extension	C7
Wrist flexion	C7 – C8
Wrist extension	C6 – C7
Finger flexion	C8
Finger extension	C7
Finger abduction	T1

Lower limb

Myotome	Movement most strongly associated with myotome
L2	Hip flexion
L3	Knee extension
L4	Ankle dorsiflexion
L5	Great toe extension
S1	Ankle plantarflexion
S2	Knee flexion

Muscle movement	Nerve root(s)
Hip flexion	L1 – L2
Hip adduction	L2 – L3
Hip extension	L5 – S1
Knee flexion	L5 – S2
Knee extension	L3 – L4
Ankle dorsiflexion	L4
Ankle plantarflexion	S1 – S2
Great toe extension	L5

Reflexes

Reflex	Nerve root(s)
Biceps reflex	C5 – C6
Supinator reflex	C6 – C7
Triceps reflex	C7 – C8
Patella reflex	L3 – L4
Ankle reflex	S1 – S2

< Previous | Next >

Something wrong?

Question Navigator

1 Answered
2 Answered
3 Answered
4 Answered
5 Answered
6 Answered
7 Answered
8 Answered
9 Answered
10 Answered
11 Answered
12 Answered

Clear Exam

©2014 - 2017 FRCEM Success | Website designed & hosted by Cyberfrog Design

Anatomy: Neck

A 21 year old presents to ED with a headache and neck stiffness. You are asked to perform a lumbar puncture. After penetrating the skin and subcutaneous tissue, what is the next layer that is penetrated:

a Interspinous ligament

b Supraspinous ligament

c Posterior longitudinal ligament

d Ligamentum flavum

e Dura mater

< Previous | Next > | See Answer

Something wrong?

Question Navigator

1 Answered
2 Answered
3 Answered
4 Answered
5 Answered
6 Answered
7 Answered
8 Answered
9 Answered
10 Answered
11 Answered
12 Answered

Clear Exam

©2014 - 2017 FRCEM Success | Website designed & hosted by Cyberfrog Design

Anatomy: Neck

Question 24 of 78

A 21 year old presents to ED with a headache and neck stiffness. You are asked to perform a lumbar puncture. After penetrating the skin and subcutaneous tissue, what is the next layer that is penetrated:

a) **Interspinous ligament** ✗
b) Supraspinous ligament ✓
c) Posterior longitudinal ligament
d) Ligamentum flavum
e) Dura mater

Answer

When performing a lumbar puncture, the needle passes between adjacent vertebral spinous processes, through the supraspinous and interspinous ligaments and through the ligamentum flavum to enter the extradural space. The needle then continues through the dura and the arachnoid mater to enter the subarachnoid space.

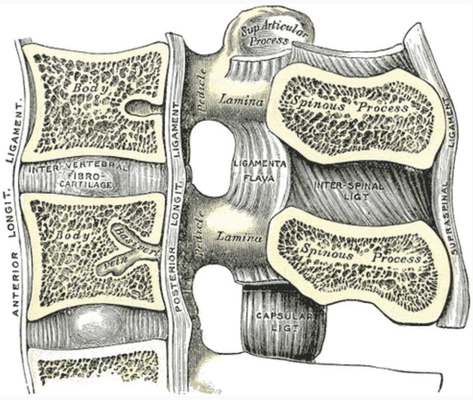

By Henry Vandyke Carter [Public domain], via Wikimedia Commons

Notes

The vertebral canal extends from the first cervical vertebra (C1) to the last sacral vertebra (S5). Superiorly the vertebral canal is continuous, through the foramen magnum of the skull, with the cranial cavity.

The vertebral canal is bounded anteriorly by the vertebral bodies, intervertebral discs and the posterior longitudinal ligament, laterally by the vertebral pedicles and posteriorly by the vertebral laminae.

The vertebral canal contains the spinal cord and its protective membranes, together with blood vessels, connective tissue, fat and spinal nerve roots. The conus medullaris is the point below which the canal contains only the cauda equina and filum terminale.

Meninges

The spinal cord is surrounded by a series of three spinal meninges consisting of a dura, arachnoid and pia mater.

The bony walls of the spinal canal are separated from the meninges by the epidural (extradural) space.

The subarachnoid space, containing CSF, is found between the arachnoid and pia mater. The subarachnoid space around the spinal cord is continuous at the foramen magnum with the subarachnoid space surrounding the brain.

Lumbar puncture

In adults, the spinal cord typically ends between L1/L2 whereas the subarachnoid space extends to approximately the lower border of vertebra S2. As a result of this, CSF can be withdrawn from the subarachnoid space in the lower lumbar region without endangering the spinal cord.

When performing a lumbar puncture, the needle passes between adjacent vertebral spinous processes, through the supraspinous and interspinous ligaments and through the ligamentum flavum to enter the extradural space. The needle then continues through the dura and the arachnoid mater to enter the subarachnoid space.

Layers penetrated during lumbar puncture:

- Skin
- Superficial fascia
- Supraspinous ligament
- Interspinous ligament
- Ligamentum flavum (first 'give')
- Extradural space
- Dura mater (second 'give')
- Subdural space
- Arachnoid mater
- Subarachnoid space (containing CSF)

< Previous | Next >

Something wrong?

Question Navigator

1 Answered
2 Answered
3 Answered
4 Answered
5 Answered
6 Answered
7 Answered
8 Answered
9 Answered
10 Answered
11 Answered
12 Answered

Clear Exam

©2014 - 2017 FRCEM Success | Website designed & hosted by Cyberfrog Design

Anatomy: Neck

Question 25 of 78

The spinal cord is continuous superiorly with the:

a Midbrain

b Thalamus

c Pons

d Medulla oblongata

e Corpus callosum

< Previous | Next > | See Answer

Something wrong?

Question Navigator

1 Answered
2 Answered
3 Answered
4 Answered
5 Answered
6 Answered
7 Answered
8 Answered
9 Answered
10 Answered
11 Answered
12 Answered

Clear Exam

©2014 - 2017 FRCEM Success | Website designed & hosted by Cyberfrog Design

Anatomy: Neck

Question 25 of 78

The spinal cord is continuous superiorly with the:

a) Midbrain ✖
b) Thalamus
c) Pons
d) Medulla oblongata ✔
e) Corpus callosum

Answer

The spinal cord arises cranially as a continuation of the medulla oblongata at the foramen magnum.

Notes

Spinal cord extent

The spinal cord arises cranially as a continuation of the medulla oblongata at the foramen magnum. It then travels inferiorly within the vertebral canal, surrounded by the spinal meninges, before terminating as the conus medullaris. The filum terminale is an extension of pia mater that extends from the conus medullaris to the dural sac, and from the dural sac to the coccyx.

At birth, the conus medullaris lies at L3. By the age of 21, it sits at L1/L2, thus the spinal cord only occupies about 2/3s of the space available to it in the vertebral canal. The lower a nerve root, therefore, the more steeply it slopes down and the further it has to travel before gaining its intervertebral foramen. The lumbosacral nerve roots that arise from the end of the spinal cord and descend through the subarachnoid space to exit through their respective intervertebral or sacral foramina are bundled together forming the cauda equina.

Spinal cord enlargements

During the course of the spinal cord, there are two points of enlargement:

- The cervical enlargement is located at the C3 – T1 level and represents the origin of the brachial plexus.
- The lumbar enlargement is located at the T9 – L1 level and represents the origin of the lumbar and sacral plexuses.

Spinal nerve roots

The spinal nerves are formed by the union of posterior and anterior roots.

Spinal rootlets emerge from the spinal cord in the subarachnoid space and amalgamate shortly afterwards into roots. Anterior roots (containing motor nerve fibres) and posterior roots (containing the processes of sensory neurons) then emerge from their individual intervertebral foramina.

After invaginating the dura, the roots combine into mixed spinal nerves which divide into a posterior ramus (innervating intrinsic back muscles and an associated strip of skin on the back) and an anterior ramus (innervating the remaining muscles and skin of the trunk and limbs and the visceral organs).

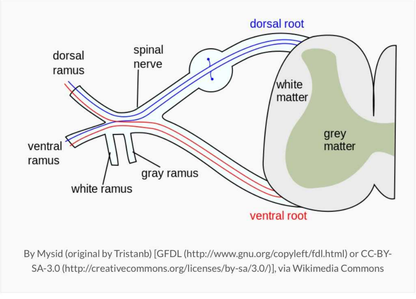

By Mysid (original by Tristanb) [GFDL (http://www.gnu.org/copyleft/fdl.html) or CC-BY-SA-3.0 (http://creativecommons.org/licenses/by-sa/3.0/)], via Wikimedia Commons

Internal anatomy

Internally the spinal cord has a small central canal (containing CSF) surrounded by grey and white matter. The central grey matter is rich in nerve cell bodies which are divided into three divisions (the anterior, posterior and lateral horns), which in cross-section form the characteristic H-shaped appearance in the central regions of the cord. The peripheral white matter surrounds the grey matter and is rich in myelinated nerve cell processes, which form large bundles or tracts that ascend and descend in the cord to other spinal cord levels or the brain. The white matter is divided bilaterally by sulci into three major divisions (the anterior, posterior and lateral columns).

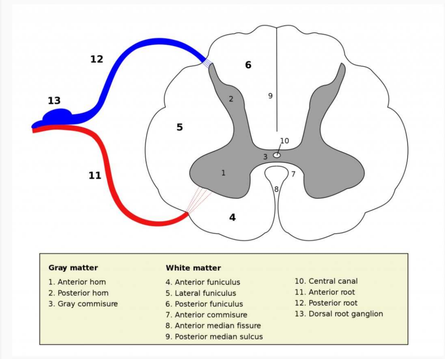

By User:Polarlys (Own work) [GFDL (http://www.gnu.org/copyleft/fdl.html), CC-BY-SA-3.0 (http://creativecommons.org/licenses/by-sa/3.0/) or CC BY 2.5 (http://creativecommons.org/licenses/by/2.5)], via Wikimedia Commons

Spinal cord blood supply

The spinal cord is supplied primarily by branches of the vertebral artery:

- The single anterior spinal artery is formed from the left and right vertebral arteries and supplies the anterior two-thirds of the spinal cord, including the anterior and lateral horns and the anterior and lateral columns.
- The paired posterior spinal arteries arise from either the posterior inferior cerebellar artery or directly from the vertebral artery and supply the posterior third of the spinal cord including the posterior horns and columns.

< Previous | Next >

Something wrong?

Question Navigator

1 Answered
2 Answered
3 Answered
4 Answered
5 Answered
6 Answered
7 Answered
8 Answered
9 Answered
10 Answered
11 Answered
12 Answered

Clear Exam

©2014 - 2017 FRCEM Success | Website designed & hosted by Cyberfrog Design

Anatomy: Neck

Question 26 of 78

The scalenus anterior muscle acts to produce which of the following movements:

a Lateral flexion of the neck

b Extension of the neck

c Elevation of the shoulders

d Depression of the shoulders

e Elevation of rib I

< Previous | Next > | See Answer

Something wrong?

Question Navigator

1 Answered
2 Answered
3 Answered
4 Answered
5 Answered
6 Answered
7 Answered
8 Answered
9 Answered
10 Answered
11 Answered
12 Answered

Clear Exam

©2014 - 2017 FRCEM Success | Website designed & hosted by Cyberfrog Design

Anatomy: Neck

Question 26 of 78

The scalenus anterior muscle acts to produce which of the following movements:

a) **Lateral flexion of the neck** ✖
b) Extension of the neck
c) Elevation of the shoulders
d) Depression of the shoulders
e) Elevation of rib I ✔

Answer

The scalenus anterior is a synergistic stabiliser of the neck and acts together with the other scalene muscles to elevate rib I.

Notes

The scalenus anterior is a synergistic stabiliser of the neck and acts together with the other scalene muscles to elevate rib I.

It originates from the anterior tubercles of the transverse processes of vertebrae C3 – C6 and inserts onto the scalene tubercle and upper surface of rib I.

It is innervated by the anterior rami of C4 – C7.

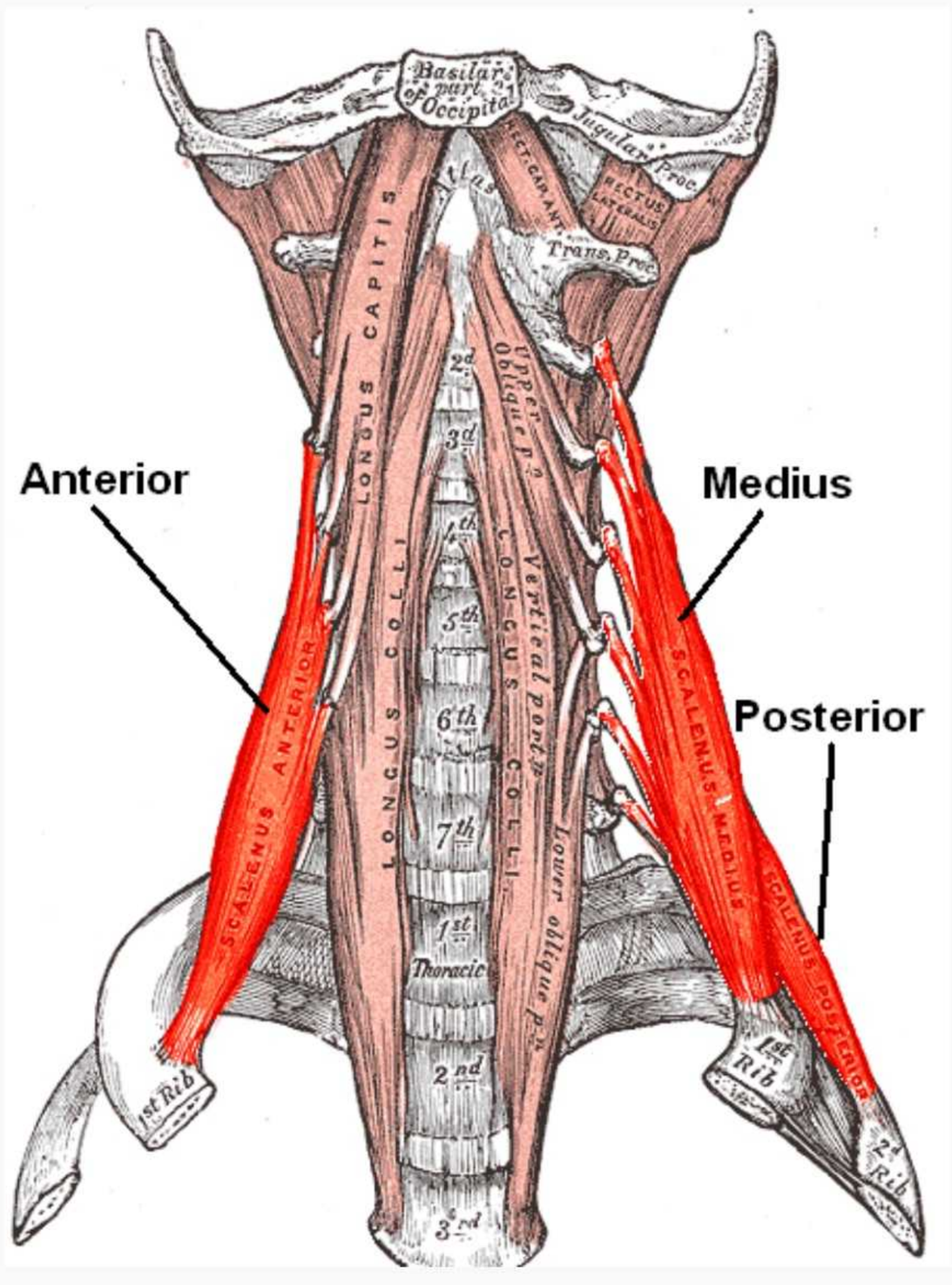

By User:Mikael Häggström (Image:Gray387.png) [Public domain, Public domain or Public domain], via Wikimedia Commons

< Previous | Next >

Something wrong?

Question Navigator

1 Answered
2 Answered
3 Answered
4 Answered
5 Answered
6 Answered
7 Answered
8 Answered
9 Answered
10 Answered
11 Answered
12 Answered

Clear Exam

©2014 - 2017 FRCEM Success | Website designed & hosted by Cyberfrog Design

Anatomy: Neck

Question 27 of 78

The anaesthetist is attempting to intubate an unconscious patient who is unable to maintain their airway. The anaesthetist finds himself in a 'can't intubate, can't ventilate' situation and proceeds to perform an emergency tracheotomy. Which of the following structures are most likely damaged in this procedure:

a Middle and inferior thyroid veins

b Inferior thyroid vein and thyroidea ima artery

c Middle and superior thyroid veins

d Inferior thyroid vein and artery

e Cricothyroid artery and inferior thyroid vein

< Previous | Next > | See Answer

Something wrong?

Question Navigator

1 Answered
2 Answered
3 Answered
4 Answered
5 Answered
6 Answered
7 Answered
8 Answered
9 Answered
10 Answered
11 Answered
12 Answered

Clear Exam

©2014 - 2017 FRCEM Success | Website designed & hosted by Cyberfrog Design

Anatomy: Neck

Question 27 of 78

The anaesthetist is attempting to intubate an unconscious patient who is unable to maintain their airway. The anaesthetist finds himself in a 'can't intubate, can't ventilate' situation and proceeds to perform an emergency tracheotomy. Which of the following structures are most likely damaged in this procedure:

a) **Middle and inferior thyroid veins** ✖
b) Inferior thyroid vein and thyroidea ima artery ✔
c) Middle and superior thyroid veins
d) Inferior thyroid vein and artery
e) Cricothyroid artery and inferior thyroid vein

Answer

Structures particularly vulnerable in tracheostomy include the isthmus of the thyroid, the jugular arch connecting the anterior jugular veins, the inferior thyroid vein, the left brachiocephalic vein, the thyroidea ima artery, and the recurrent laryngeal nerve (less commonly).

Notes

The trachea begins at vertebral level C6, where it is continuous with the larynx above. The trachea lies directly anterior to the oesophagus and travels inferiorly to pass through the thoracic inlet.

Cricothyrotomy

A cricothyrotomy is performed to provide a temporary emergency airway in situations where there is obstruction at or above the level of the larynx, such that oral/nasal endotracheal intubation is impossible e.g. as a result of inhalation of a foreign body, severe oedema secondary to anaphylactic reaction, or severe head and neck trauma.

Compared with an emergency tracheostomy, it is quicker and easier to perform and associated with fewer complications. It involves making an opening in the median cricothyroid ligament (the medial part of the cricothyroid ligament), between the cricoid and thyroid cartilages of the larynx. The ligament can be palpated in the midline and usually there are only small blood vessels, connective tissue and skin overlying it.

Tracheostomy

At a lower level, the airway can be accessed surgically (or percutaneously) through the anterior wall of the trachea by tracheostomy. Tracheostomy is usually performed in non-emergency situations.

A small transverse incision is placed in the lower third of the neck anteriorly. The strap (infrahyoid) muscles are deviated laterally and the trachea can be easily visualised. Occasionally it is necessary to divide the isthmus of the thyroid. An incision is typically made between the second and third or the third and fourth tracheal rings and a small tracheostomy tube inserted.

This route of entry is complicated because large veins and part of the thyroid gland overlie this region. Structures particularly vulnerable include the isthmus of the thyroid, the jugular arch connecting the anterior jugular veins, the inferior thyroid vein, the left brachiocephalic vein, the thyroidea ima artery, and the recurrent laryngeal nerve (less commonly).

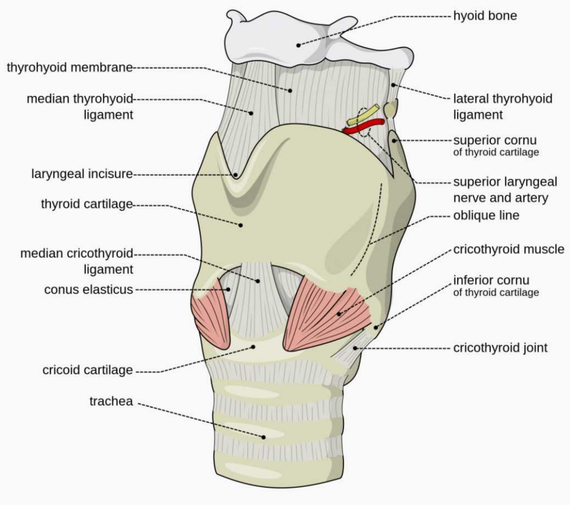

By Olek Remesz (wiki-pl: Orem, commons: Orem) [CC BY-SA 2.5-2.0-1.0], via Wikimedia Commons

< Previous | Next >

Something wrong?

Question Navigator

1 Answered
2 Answered
3 Answered
4 Answered
5 Answered
6 Answered
7 Answered
8 Answered
9 Answered
10 Answered
11 Answered
12 Answered

Clear Exam

©2014 - 2017 FRCEM Success | Website designed & hosted by Cyberfrog Design

Anatomy: Neck

Question 28 of 78

The scalenus anterior muscle inserts onto which of the following structures:

a Medial clavicle

b Lateral clavicle

c First rib

d Manubrium of the sternum

e Coracoid process

< Previous | Next > | See Answer

Something wrong?

Question Navigator

1 Answered
2 Answered
3 Answered
4 Answered
5 Answered
6 Answered
7 Answered
8 Answered
9 Answered
10 Answered
11 Answered
12 Answered

Clear Exam

©2014 - 2017 FRCEM Success | Website designed & hosted by Cyberfrog Design

Anatomy: Neck

Question 28 of 78

The scalenus anterior muscle inserts onto which of the following structures:

a) Medial clavicle ✗
b) Lateral clavicle
c) First rib ✓
d) Manubrium of the sternum
e) Coracoid process

Answer

The scalenus anterior originates from the anterior tubercles of the transverse processes of vertebrae C3 – C6 and inserts onto the scalene tubercle and upper surface of rib I.

Notes

The scalenus anterior is a synergistic stabiliser of the neck and acts together with the other scalene muscles to elevate rib I.

It originates from the anterior tubercles of the transverse processes of vertebrae C3 – C6 and inserts onto the scalene tubercle and upper surface of rib I.

It is innervated by the anterior rami of C4 – C7.

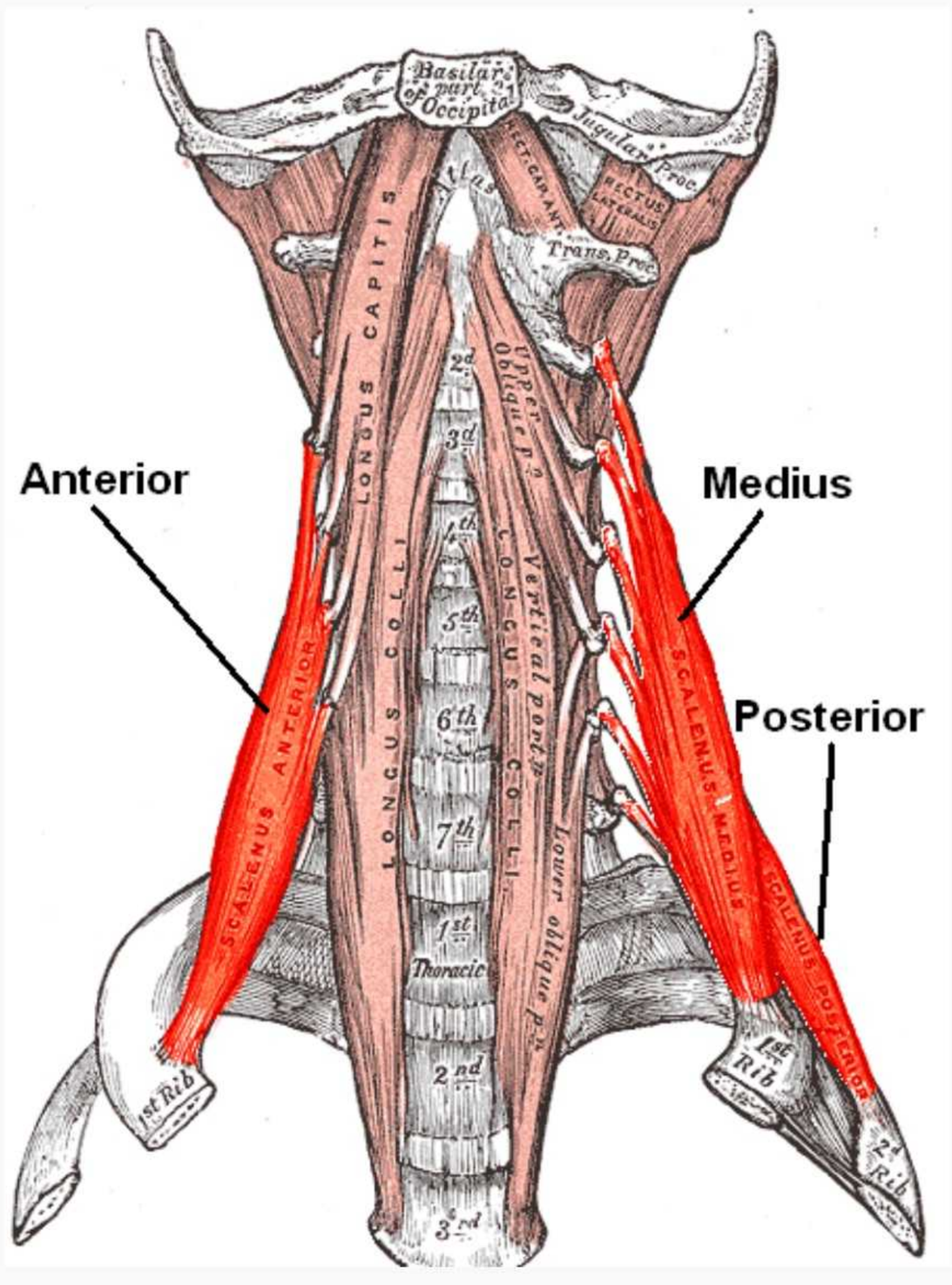

By User:Mikael Häggström (Image:Gray387.png) [Public domain, Public domain or Public domain], via Wikimedia Commons

< Previous | Next >

Something wrong?

Question Navigator

1 Answered
2 Answered
3 Answered
4 Answered
5 Answered
6 Answered
7 Answered
8 Answered
9 Answered
10 Answered
11 Answered
12 Answered

Clear Exam

©2014 - 2017 FRCEM Success | Website designed & hosted by Cyberfrog Design

Anatomy: Neck

Question 29 of 78

Regarding the subclavian vein, which of the following statements is INCORRECT:

a The subclavian vein begins at the lateral margin of rib I.

b The subclavian vein is a continuation of the axillary vein.

c The subclavian vein is joined by the internal jugular vein to form the brachiocephalic vein just posterior to the anterior scalene muscle.

d Central venous cannulation may be performed in the internal jugular vein or subclavian vein.

e Subclavian vein cannulation carries a risk of pneumothorax.

< Previous | Next > | See Answer

Something wrong?

Question Navigator

1 Answered
2 Answered
3 Answered
4 Answered
5 Answered
6 Answered
7 Answered
8 Answered
9 Answered
10 Answered
11 Answered
12 Answered

Clear Exam

©2014 - 2017 FRCEM Success | Website designed & hosted by Cyberfrog Design

Anatomy: Neck

Question 29 of 78

Regarding the subclavian vein, which of the following statements is INCORRECT:

a) **The subclavian vein begins at the lateral margin of rib I.** ✗

b) The subclavian vein is a continuation of the axillary vein.

c) ✓

The subclavian vein is joined by the internal jugular vein to form the brachiocephalic vein just posterior to the anterior scalene muscle.

d) Central venous cannulation may be performed in the internal jugular vein or subclavian vein.

e) Subclavian vein cannulation carries a risk of pneumothorax.

Answer

The brachiocephalic vein is formed from the union of the subclavian and internal jugular vein just anterior to the anterior scalene muscle.

Notes

The subclavian veins begin at the lateral margin of rib I as continuations of the axillary veins. Passing medially on each side, just anterior to the anterior scalene muscles, each subclavian vein is joined by the internal jugular vein to form the brachiocephalic vein.

Central venous cannulation may be performed via the internal jugular vein or subclavian vein.

To gain subclavian access, the clavicle is identified and the needle placed in the infraclavicular region (in the midclavicular line or lateral to this line), aiming superomedially. As the subclavian vein passes inferiorly, posterior to the clavicle, it passes over the apex of the lung. Any misplacement of a needle into or through this structure may puncture the apical pleura, producing a pneumothorax. Inadvertent arterial puncture and vein laceration may also produce a haemopneumothorax.

A puncture of the internal jugular vein carries fewer risks but local haematoma and damage to the carotid artery are important considerations.

< Previous | Next >

Something wrong?

Question Navigator

1 Answered
2 Answered
3 Answered
4 Answered
5 Answered
6 Answered
7 Answered
8 Answered
9 Answered
10 Answered
11 Answered
12 Answered

Clear Exam

©2014 - 2017 FRCEM Success | Website designed & hosted by Cyberfrog Design

Anatomy: Neck

Question 30 of 78

The stylopharyngeus muscle of the pharynx is innervated by which of the following nerves:

a Facial nerve

b Glossopharyngeal nerve

c Vagus nerve

d Hypoglossal nerve

e Mandibular nerve

< Previous | Next > | See Answer

Something wrong?

Question Navigator

1 Answered
2 Answered
3 Answered
4 Answered
5 Answered
6 Answered
7 Answered
8 Answered
9 Answered
10 Answered
11 Answered
12 Answered

Clear Exam

©2014 - 2017 FRCEM Success | Website designed & hosted by Cyberfrog Design

Anatomy: Neck

Question 30 of 78

The stylopharyngeus muscle of the pharynx is innervated by which of the following nerves:

a) Facial nerve ✗
b) Glossopharyngeal nerve ✓
c) Vagus nerve
d) Hypoglossal nerve
e) Mandibular nerve

Answer

The muscles of the pharynx are all innervated by the vagus nerve except for the stylopharyngeus muscle, innervated by the glossopharyngeal nerve.

Notes

The pharynx is a musculofascial structure that connects the oral and nasal cavities in the head to the larynx and the oesophagus in the neck.

The pharynx is attached above to the base of the skull, and is continuous below, approximately at the level of vertebra C6, with the top of the oesophagus.

The pharynx is separated from the posterior vertebral column by a thin retropharyngeal space, bordered anteriorly by the buccopharyngeal fascia and posteriorly by the prevertebral fascia.

Arrangement

The walls of the pharynx are attached anteriorly to the margins of the nasal cavities, oral cavity and larynx, dividing the pharynx into the continuous nasopharynx, oropharynx and laryngopharynx respectively.

The posterior apertures of the nasal cavities open into the nasopharynx, the oropharyngeal isthmus opens into the oropharynx and the superior aperture of the larynx opens into the laryngopharynx.

The pharyngotympanic tubes (from the middle ear) open into the lateral walls of the nasopharynx.

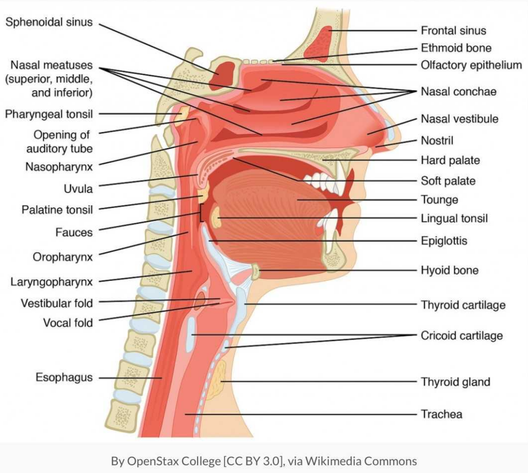

By OpenStax College [CC BY 3.0], via Wikimedia Commons

Muscles

The muscles of the pharyngeal wall are organised into two groups.

The three sheet-like constrictor muscles constrict the pharyngeal cavity sequentially to move a bolus of food through the pharynx and into the oesophagus during swallowing.

The three longitudinal muscles elevate the pharyngeal wall, or during swallowing, pull the pharyngeal wall up and over a bolus of food being moved through the pharynx into the oesophagus.

Nerve supply

The muscles of the pharynx are all innervated by the vagus nerve except for the stylopharyngeus muscle, innervated by the glossopharyngeal nerve. The branches of the vagus and glossopharyngeal nerves form a pharyngeal plexus in the outer fascia of the pharyngeal wall.

Each subdivision of the pharynx has a different sensory innervation:

- the nasopharynx is innervated by the maxillary nerve
- the oropharynx is innervated by the glossopharyngeal nerve
- the laryngopharynx is innervated by the vagus nerve.

Lymphatics

Lymphatic vessels from the pharynx drain into the deep cervical lymph nodes.

< Previous | Next >

Something wrong?

Question Navigator

1 Answered
2 Answered
3 Answered
4 Answered
5 Answered
6 Answered
7 Answered
8 Answered
9 Answered
10 Answered
11 Answered
12 Answered

Clear Exam

©2014 - 2017 FRCEM Success | Website designed & hosted by Cyberfrog Design

Anatomy: Neck

Question 31 of 78

The jugulodigastric lymph node receives lymph drainage primarily from which of the following territories:

a Tongue

b Tonsils

c Lower teeth

d Upper teeth

e Nasopharynx

< Previous | Next > | See Answer

Something wrong?

Question Navigator

1 Answered
2 Answered
3 Answered
4 Answered
5 Answered
6 Answered
7 Answered
8 Answered
9 Answered
10 Answered
11 Answered
12 Answered

Clear Exam

©2014 - 2017 FRCEM Success | Website designed & hosted by Cyberfrog Design

Anatomy: Neck

Question 31 of 78

The jugulodigastric lymph node receives lymph drainage primarily from which of the following territories:

a) Tongue ✗
b) Tonsils ✓
c) Lower teeth
d) Upper teeth
e) Nasopharynx

Answer

The jugulodigastric node receives lymphatic drainage from the tonsils and tonsillar region.

Notes

The deep cervical nodes form a chain along the internal jugular vein and are divided into upper and lower groups.

The most superior node in the upper group (lying where the posterior belly of the digastric muscle crosses the internal jugular vein) is the jugulodigastric node which receives lymphatic drainage from the tonsils and tonsillar region.

The most superior node in the lower group (lying just inferior to the intermediate tendon of the omohyoid muscle) is the jugulo-omohyoid node which receives lymphatic drainage from the tongue.

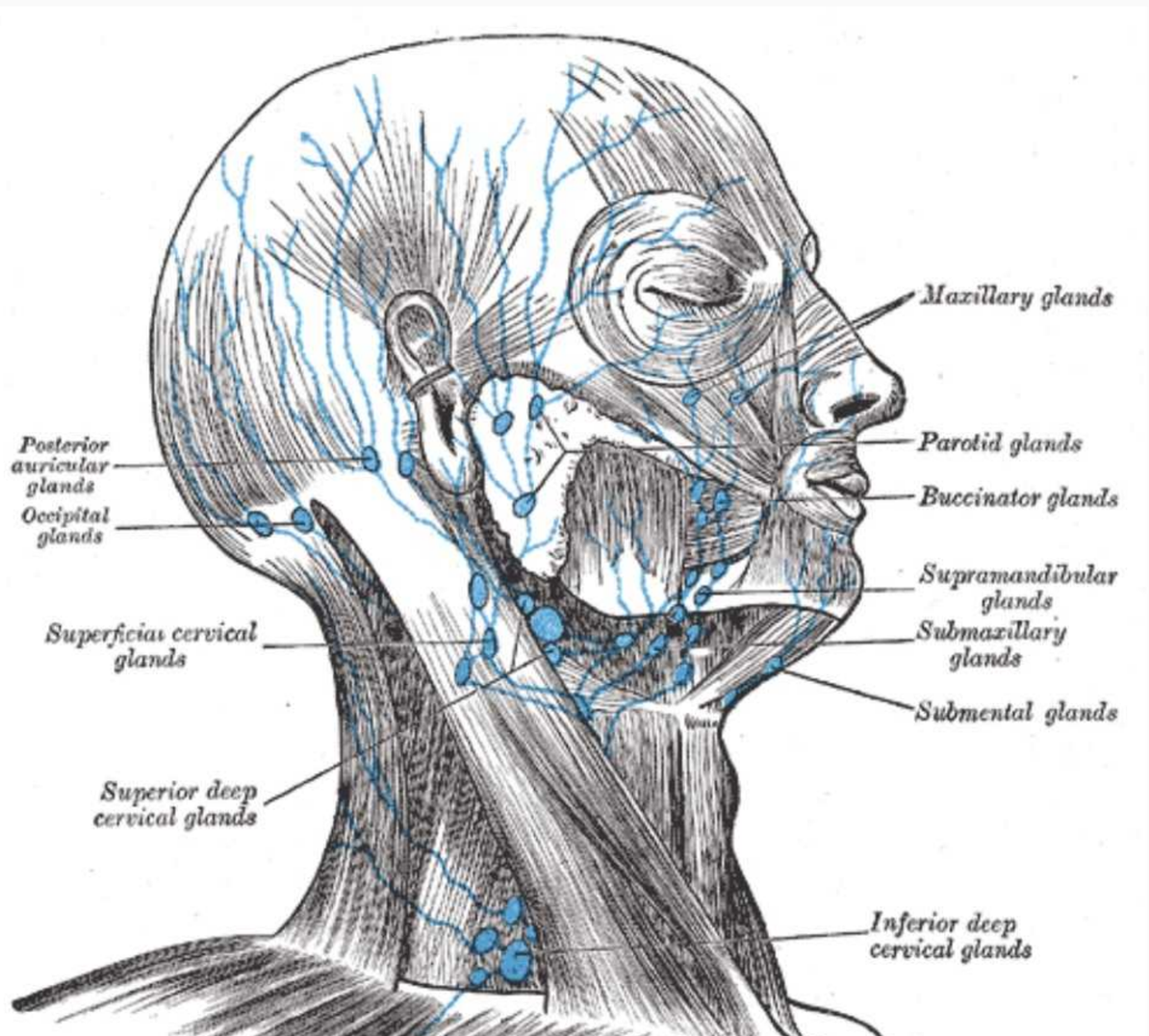

By Henry Vandyke Carter [Public domain], via Wikimedia Commons

< Previous | Next >

Something wrong?

Question Navigator

1 Answered
2 Answered
3 Answered
4 Answered
5 Answered
6 Answered
7 Answered
8 Answered
9 Answered
10 Answered
11 Answered
12 Answered

Clear Exam

©2014 - 2017 FRCEM Success | Website designed & hosted by Cyberfrog Design

Anatomy: Neck

Question 32 of 78

The cricoid cartilage articulates with which of the following structures:

a Arytenoid and corniculate cartilages

b Thyroid cartilage and epiglottis

c Arytenoid and thyroid cartilages

d Corniculate and cuneiform cartilages

e Thyroid cartilage and hyoid bone

< Previous | Next > | See Answer

Something wrong?

Question Navigator

1 Answered
2 Answered
3 Answered
4 Answered
5 Answered
6 Answered
7 Answered
8 Answered
9 Answered
10 Answered
11 Answered
12 Answered

Clear Exam

©2014 - 2017 FRCEM Success | Website designed & hosted by Cyberfrog Design

Anatomy: Neck

Question 32 of 78

The cricoid cartilage articulates with which of the following structures:

a) **Arytenoid and corniculate cartilages** ✗
b) Thyroid cartilage and epiglottis
c) Arytenoid and thyroid cartilages ✓
d) Corniculate and cuneiform cartilages
e) Thyroid cartilage and hyoid bone

Answer

The cricoid cartilage articulates with the base of the arytenoid cartilages superiorly (forming the cricoarytenoid joint) and the inferior horns of the thyroid cartilage laterally (forming the cricothyroid joint).

Notes

The structure of the larynx is formed from three large unpaired cartilages (cricoid, thyroid, and epiglottis), three smaller paired cartilages (arytenoid, corniculate and cuneiform), joints, ligaments, a fibroelastic membrane and numerous intrinsic muscles.

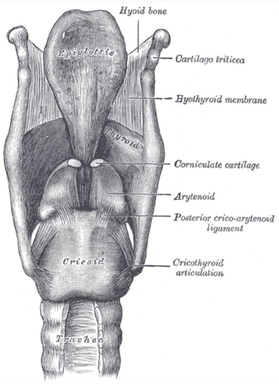

By Henry Vandyke Carter [Public domain], via Wikimedia Commons

Cartilages

The cricoid cartilage is the most inferior of the laryngeal cartilages and completely encircles the airway. The cricoid cartilage articulates with the base of the arytenoid cartilages superiorly (forming the cricoarytenoid joint) and the inferior horns of the thyroid cartilage posterolaterally (forming the cricothyroid joint).

The thyroid cartilage is the largest of the laryngeal cartilages. The thyroid cartilage articulates with the cricoid cartilage inferiorly and the hyoid bone superiorly.

The epiglottis is attached to the posterior aspect of the thyroid cartilage and projects posterosuperiorly. The upper margin of the epiglottis is behind the pharyngeal part of the tongue.

The two arytenoid cartilages articulate inferiorly with the cricoid cartilage and superiorly with the corniculate cartilages.

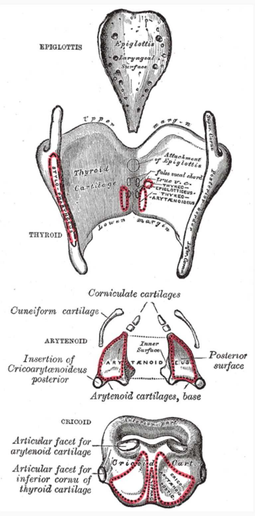

By Henry Vandyke Carter [Public domain], via Wikimedia Commons

Joints

The cricothyroid and cricoarytenoid joints are the main laryngeal joints allowing normal function.

Movements at the cricoarytenoid joints abduct and adduct the vocal ligaments.

Movements at the cricothyroid joint enable the thyroid cartilage to move forward and tilt downwards on the cricoid cartilage which effectively lengthens and puts tension on the vocal ligaments.

Cricothyroid membrane

The cricothyroid membrane (conus elasticus) is attached to the arch of the cricoid cartilage and extends superiorly to end in a free upper margin within the space enclosed by the thyroid cartilage. This upper free margin attaches on each side anteriorly to the thyroid cartilage and posteriorly to the vocal processes of the arytenoid cartilage. The free margin between these two points is thickened to form the vocal ligament which is under the vocal fold of the larynx.

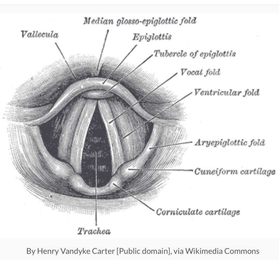

By Henry Vandyke Carter [Public domain], via Wikimedia Commons

The cricothyroid membrane is also thickened anteriorly in the midline to form the distinct median cricothyroid ligament, which spans the distance between the arch of the cricoid cartilage and the thyroid cartilage up to the attachments of the vocal ligaments. In emergency situations, when the airway is blocked above the level of the vocal folds, the median cricothyroid ligament can be perforated to establish an airway (cricothyrotomy).

< Previous | Next >

Something wrong?

Question Navigator

1 Answered
2 Answered
3 Answered
4 Answered
5 Answered
6 Answered
7 Answered
8 Answered
9 Answered
10 Answered
11 Answered
12 Answered

Clear Exam

©2014 - 2017 FRCEM Success | Website designed & hosted by Cyberfrog Design

Anatomy: Neck

Question 33 of 78

Regarding the cervical vertebrae, which of the following statements is INCORRECT:

a The atlas is distinguished by its lack of vertebral body.

b The atlas articulates with the occipital condyles of the skull superiorly.

c The dens of the axis articulates with the posterior arch of the atlas.

d The axis has a bifid spinous process.

e The atlantoaxial joints allow the head to rotate from side to side.

< Previous | Next > | See Answer

Something wrong?

Question Navigator

1 Answered
2 Answered
3 Answered
4 Answered
5 Answered
6 Answered
7 Answered
8 Answered
9 Answered
10 Answered
11 Answered
12 Answered

Clear Exam

©2014 - 2017 FRCEM Success | Website designed & hosted by Cyberfrog Design

Anatomy: Neck

Question 33 of 78

Regarding the cervical vertebrae, which of the following statements is INCORRECT:

a) **The atlas is distinguished by its lack of vertebral body.** ✖
b) The atlas articulates with the occipital condyles of the skull superiorly.
c) The dens of the axis articulates with the posterior arch of the atlas. ✔
d) The axis has a bifid spinous process.
e) The atlantoaxial joints allow the head to rotate from side to side.

Answer

The dens of the axis extends superiorly from its vertebral body to articulate with the anterior arch of the atlas.

Notes

Vertebra C1 (the atlas) is distinguished by its lack of vertebral body, essentially being composed of two lateral masses interconnected by an anterior and posterior arch. Each lateral mass articulates above with an occipital condyle of the skull and below with the superior articular facet of vertebra C2 (the axis). The posterior surface of the anterior arch has an articular facet for the dens of the axis.

The axis is characterised by the large dens, which extends superiorly from its vertebral body to articulate with the anterior arch of the atlas, and by its bifid spinous process. The dens is held in position by the strong transverse ligament of atlas posterior to it and spanning the distance between the lateral masses of the atlas.

The atlanto-occipital joints allow the head to nod up and down on the vertebral column.

The atlanto-axial joints allow the head to rotate from side to side.

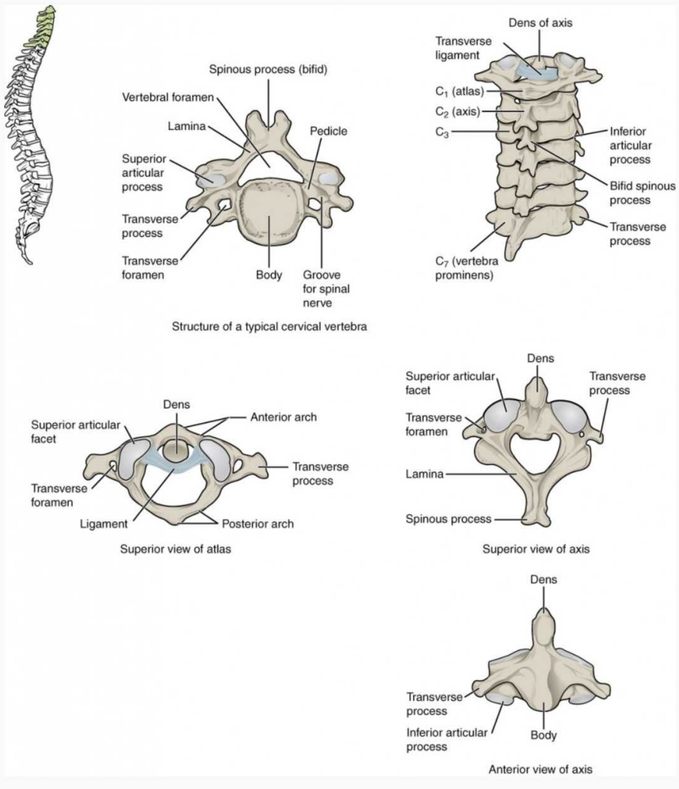

By OpenStax College [CC BY 3.0], via Wikimedia Commons

< Previous | Next >

Something wrong?

Question Navigator

1 Answered
2 Answered
3 Answered
4 Answered
5 Answered
6 Answered
7 Answered
8 Answered
9 Answered
10 Answered
11 Answered
12 Answered

Clear Exam

©2014 - 2017 FRCEM Success | Website designed & hosted by Cyberfrog Design

Anatomy: Neck

Question 34 of 78

A 74 year old man presents with a three month history of worsening left shoulder and arm pain. On examination there is weakness of shoulder abduction and reduced sensation over the deltoid. You suspect cervical radiculopathy. What level of the cervical spine is most likely to be affected:

a C1

b C3

c C5

d C7

e C8

< Previous | Next > | See Answer

Something wrong?

Question Navigator

1 Answered
2 Answered
3 Answered
4 Answered
5 Answered
6 Answered
7 Answered
8 Answered
9 Answered
10 Answered
11 Answered
12 Answered

Clear Exam

©2014 - 2017 FRCEM Success | Website designed & hosted by Cyberfrog Design

Anatomy: Neck

Question 34 of 78

A 74 year old man presents with a three month history of worsening left shoulder and arm pain. On examination there is weakness of shoulder abduction and reduced sensation over the deltoid. You suspect cervical radiculopathy. What level of the cervical spine is most likely to be affected:

a) C1 ✗
b) C3
c) C5 ✓
d) C7
e) C8

Answer

The C5 nerve root is most likely affected.

Notes

Upper limb

Myotome	Movement most strongly associated with myotome
C5	Shoulder abduction
C6	Elbow flexion/wrist extension
C7	Elbow extension/wrist flexion
C8	Finger flexion
T1	Finger abduction

Muscle movement	Nerve root(s)
Shoulder abduction	C5
Shoulder adduction	C5 – C7
Elbow flexion	C5 – C6
Elbow extension	C7
Wrist flexion	C7 – C8
Wrist extension	C6 – C7
Finger flexion	C8
Finger extension	C7
Finger abduction	T1

Lower limb

Myotome	Movement most strongly associated with myotome
L2	Hip flexion
L3	Knee extension
L4	Ankle dorsiflexion
L5	Great toe extension
S1	Ankle plantarflexion
S2	Knee flexion

Muscle movement	Nerve root(s)
Hip flexion	L1 – L2
Hip adduction	L2 – L3
Hip extension	L5 – S1
Knee flexion	L5 – S2
Knee extension	L3 – L4
Ankle dorsiflexion	L4
Ankle plantarflexion	S1 – S2
Great toe extension	L5

Reflexes

Reflex	Nerve root(s)
Biceps reflex	C5 – C6
Supinator reflex	C6 – C7
Triceps reflex	C7 – C8
Patella reflex	L3 – L4
Ankle reflex	S1 – S2

< Previous | Next >

Something wrong?

Question Navigator

1 Answered
2 Answered
3 Answered
4 Answered
5 Answered
6 Answered
7 Answered
8 Answered
9 Answered
10 Answered
11 Answered
12 Answered

Clear Exam

©2014 - 2017 FRCEM Success | Website designed & hosted by Cyberfrog Design

Anatomy: Neck

Question 35 of 78

The muscles of the pharynx (other than the stylopharyngeus) are all innervated by which of the following nerves:

a Facial nerve

b Glossopharyngeal nerve

c Vagus nerve

d Hypoglossal nerve

e Mandibular nerve

< Previous | Next > | See Answer

Something wrong?

Question Navigator

1 Answered
2 Answered
3 Answered
4 Answered
5 Answered
6 Answered
7 Answered
8 Answered
9 Answered
10 Answered
11 Answered
12 Answered

Clear Exam

©2014 - 2017 FRCEM Success | Website designed & hosted by Cyberfrog Design

Anatomy: Neck

Question 35 of 78

The muscles of the pharynx (other than the stylopharyngeus) are all innervated by which of the following nerves:

a) Facial nerve ✗
b) Glossopharyngeal nerve
c) Vagus nerve ✓
d) Hypoglossal nerve
e) Mandibular nerve

Answer

The muscles of the pharynx are all innervated by the vagus nerve except for the stylopharyngeus muscle, innervated by the glossopharyngeal nerve.

Notes

The pharynx is a musculofascial structure that connects the oral and nasal cavities in the head to the larynx and the oesophagus in the neck.

The pharynx is attached above to the base of the skull, and is continuous below, approximately at the level of vertebra C6, with the top of the oesophagus.

The pharynx is separated from the posterior vertebral column by a thin retropharyngeal space, bordered anteriorly by the buccopharyngeal fascia and posteriorly by the prevertebral fascia.

Arrangement

The walls of the pharynx are attached anteriorly to the margins of the nasal cavities, oral cavity and larynx, dividing the pharynx into the continuous nasopharynx, oropharynx and laryngopharynx respectively.

The posterior apertures of the nasal cavities open into the nasopharynx, the oropharyngeal isthmus opens into the oropharynx and the superior aperture of the larynx opens into the laryngopharynx.

The pharyngotympanic tubes (from the middle ear) open into the lateral walls of the nasopharynx.

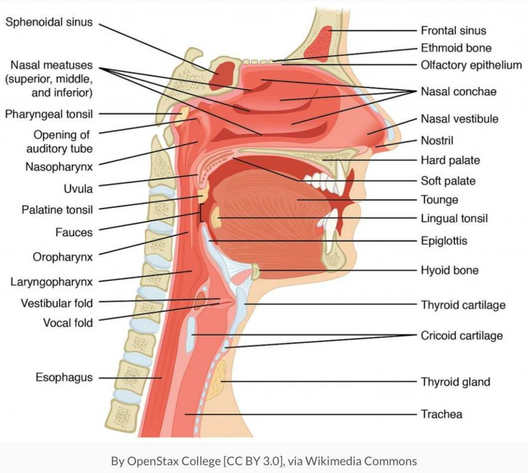

By OpenStax College [CC BY 3.0], via Wikimedia Commons

Muscles

The muscles of the pharyngeal wall are organised into two groups.

The three sheet-like constrictor muscles constrict the pharyngeal cavity sequentially to move a bolus of food through the pharynx and into the oesophagus during swallowing.

The three longitudinal muscles elevate the pharyngeal wall, or during swallowing, pull the pharyngeal wall up and over a bolus of food being moved through the pharynx into the oesophagus.

Nerve supply

The muscles of the pharynx are all innervated by the vagus nerve except for the stylopharyngeus muscle, innervated by the glossopharyngeal nerve. The branches of the vagus and glossopharyngeal nerves form a pharyngeal plexus in the outer fascia of the pharyngeal wall.

Each subdivision of the pharynx has a different sensory innervation:

- the nasopharynx is innervated by the maxillary nerve
- the oropharynx is innervated by the glossopharyngeal nerve
- the laryngopharynx is innervated by the vagus nerve.

Lymphatics

Lymphatic vessels from the pharynx drain into the deep cervical lymph nodes.

< Previous | Next >

Something wrong?

Question Navigator

1 Answered
2 Answered
3 Answered
4 Answered
5 Answered
6 Answered
7 Answered
8 Answered
9 Answered
10 Answered
11 Answered
12 Answered

Clear Exam

©2014 - 2017 FRCEM Success | Website designed & hosted by Cyberfrog Design

Anatomy: Neck

Question 36 of 78

A 29 year old male presents to ED with a penetrating injury to the neck. You suspect injury to the right sternocleidomastoid muscle. How would you best assess function of this muscle:

a Ask patient to shrug shoulder against resistance

b Ask patient to flex head against resistance

c Ask patient to extend head against resistance

d Ask patient to rotate head against resistance

e Ask patient to abduct shoulder against resistance

< Previous | Next > | See Answer

Something wrong?

Question Navigator

1 Answered
2 Answered
3 Answered
4 Answered
5 Answered
6 Answered
7 Answered
8 Answered
9 Answered
10 Answered
11 Answered
12 Answered

Clear Exam

©2014 - 2017 FRCEM Success | Website designed & hosted by Cyberfrog Design

Anatomy: Neck

Question 36 of 78

A 29 year old male presents to ED with a penetrating injury to the neck. You suspect injury to the right sternocleidomastoid muscle. How would you best assess function of this muscle:

a) **Ask patient to shrug shoulder against resistance** ✖
b) Ask patient to flex head against resistance
c) Ask patient to extend head against resistance
d) Ask patient to rotate head against resistance ✔
e) Ask patient to abduct shoulder against resistance

Answer

The sternocleidomastoid muscle is best assessed by testing rotation of head against resistance. The right sternocleidomastoid muscle acts to rotate the head towards the left and vice versa.

Notes

Muscle	Sternocleidomastoid
Origin	• Sternal head: anterior manubrium of sternum • Clavicular head: medial one-third of clavicle
Insertion	• Sternal head: lateral one-half of superior nuchal line • Clavicular head: lateral mastoid process
Innervation	Accessory nerve (and by branches of anterior rami of C2 – C3)
Action	• Acting unilaterally: lateral rotation of head towards same side and rotation of head towards opposite side • Acting bilaterally: dorsal extension of head

The sternocleidomastoid muscle has two heads; the sternal head originates from the upper part of the anterior manubrium of the sternum and inserts onto the lateral one-half of the superior nuchal line (occipital bone) and the clavicular head originates from the superior surface of the medial one-third of the clavicle and inserts onto the lateral surface of the mastoid process (temporal bone).

The sternocleidomastoid is innervated by the accessory nerve (CN XI) and by branches of anterior rami of C2 – C3.

Individually each muscle will tilt the head towards the shoulder on the same side (lateral flexion) and rotate the head to turn to face the opposite side. Acting together the muscles draw the head forward, through extension of the neck at the atlanto-occipital joints (dorsal extension).

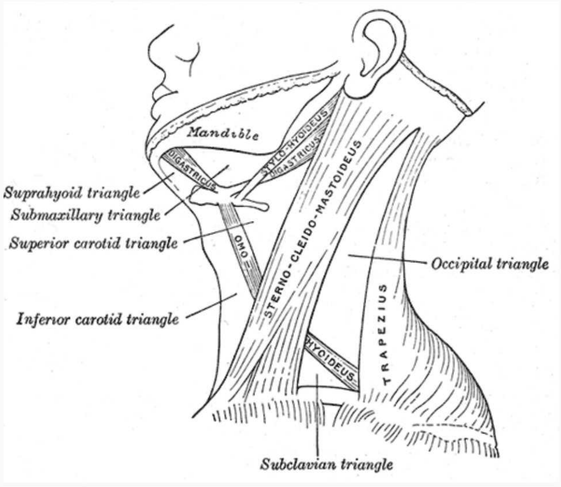

By Henry Vandyke Carter [Public domain], via Wikimedia Commons

< Previous | Next > | Something wrong?

Question Navigator

1 Answered
2 Answered
3 Answered
4 Answered
5 Answered
6 Answered
7 Answered
8 Answered
9 Answered
10 Answered
11 Answered
12 Answered

Clear Exam

©2014 - 2017 FRCEM Success | Website designed & hosted by Cyberfrog Design

Anatomy: Neck

Question 37 of 78

The two heads of the sternocleidomastoid muscle originate from which of the following structures:

a Coracoid process and medial one-third of the clavicle

b Medial clavicle and the xiphoid process of the sternum

c Medial one-third of the clavicle and the manubrium of the sternum

d Lateral one-half of the clavicle and the manubrium of the sternum

e Lateral clavicle and spine of the scapula

< Previous | Next > | See Answer

Something wrong?

Question Navigator

1 Answered
2 Answered
3 Answered
4 Answered
5 Answered
6 Answered
7 Answered
8 Answered
9 Answered
10 Answered
11 Answered
12 Answered

Clear Exam

©2014 - 2017 FRCEM Success | Website designed & hosted by Cyberfrog Design

Anatomy: Neck

Question 37 of 78

The two heads of the sternocleidomastoid muscle originate from which of the following structures:

a) **Coracoid process and medial one-third of the clavicle** ✖
b) Medial clavicle and the xiphoid process of the sternum
c) Medial one-third of the clavicle and the manubrium of the sternum ✔
d) Lateral one-half of the clavicle and the manubrium of the sternum
e) Lateral clavicle and spine of the scapula

Answer

The sternocleidomastoid muscle has two heads; the sternal head originates from the upper part of the anterior manubrium of the sternum and inserts onto the lateral one-half of the superior nuchal line (occipital bone) and the clavicular head originates from the superior surface of the medial one-third of the clavicle and inserts onto the lateral surface of the mastoid process (temporal bone).

Notes

Muscle	Sternocleidomastoid
Origin	• Sternal head: anterior manubrium of sternum • Clavicular head: medial one-third of clavicle
Insertion	• Sternal head: lateral one-half of superior nuchal line • Clavicular head: lateral mastoid process
Innervation	Accessory nerve (and by branches of anterior rami of C2 – C3)
Action	• Acting unilaterally: lateral rotation of head towards same side and rotation of head towards opposite side • Acting bilaterally: dorsal extension of head

The sternocleidomastoid muscle has two heads; the sternal head originates from the upper part of the anterior manubrium of the sternum and inserts onto the lateral one-half of the superior nuchal line (occipital bone) and the clavicular head originates from the superior surface of the medial one-third of the clavicle and inserts onto the lateral surface of the mastoid process (temporal bone).

The sternocleidomastoid is innervated by the accessory nerve (CN XI) and by branches of anterior rami of C2 – C3.

Individually each muscle will tilt the head towards the shoulder on the same side (lateral flexion) and rotate the head to turn to face the opposite side. Acting together the muscles draw the head forward, through extension of the neck at the atlanto-occipital joints (dorsal extension).

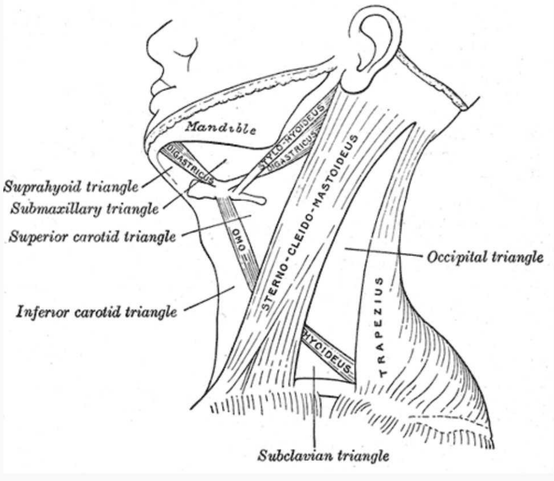

By Henry Vandyke Carter [Public domain], via Wikimedia Commons

< Previous | Next >

Something wrong?

Question Navigator

1 Answered
2 Answered
3 Answered
4 Answered
5 Answered
6 Answered
7 Answered
8 Answered
9 Answered
10 Answered
11 Answered
12 Answered

Clear Exam

©2014 - 2017 FRCEM Success | Website designed & hosted by Cyberfrog Design

Anatomy: Neck

Question 38 of 78

Regarding the musculature of the vertebral column, which of the following statements is INCORRECT:

a Rotation of the vertebral column occurs mainly in the thoracic region.

b Intrinsic back muscles are innervated by the anterior rami of spinal nerves.

c The erector spinae is the largest group of intrinsic back muscles.

d Flexion of the vertebral column is produced predominantly by the rectus abdominis muscle.

e Acting unilaterally, the erector spinae muscles act to produce lateral flexion of the vertebral column.

< Previous | Next > | See Answer

Something wrong?

Question Navigator

1 Answered
2 Answered
3 Answered
4 Answered
5 Answered
6 Answered
7 Answered
8 Answered
9 Answered
10 Answered
11 Answered
12 Answered

Clear Exam

©2014 - 2017 FRCEM Success | Website designed & hosted by Cyberfrog Design

Anatomy: Neck

Question 38 of 78

Regarding the musculature of the vertebral column, which of the following statements is INCORRECT:

a) **Rotation of the vertebral column occurs mainly in the thoracic region.** ✗
b) Intrinsic back muscles are innervated by the anterior rami of spinal nerves. ✓
c) The erector spinae is the largest group of intrinsic back muscles.
d) Flexion of the vertebral column is produced predominantly by the rectus abdominis muscle.
e) Acting unilaterally, the erector spinae muscles act to produce lateral flexion of the vertebral column.

Answer

The deep muscles of the back are classified as intrinsic back muscles and innervated by the posterior rami of spinal nerves.

Notes

Movements by the vertebral column include flexion, extension, lateral flexion and rotation. Rotation occurs predominantly in the thoracic column.

Muscles of the back are organised into superficial, intermediate and deep groups.

- Extrinsic muscles (innervated by anterior rami of spinal nerves)
  - The superficial group consists of muscles related to and involved with movements of the upper limb.
  - The intermediate group consists of muscles attached to the ribs and involved in respiratory function.
- Intrinsic muscles (innervated by posterior rami of spinal nerves)
  - The deep group consists of muscles directly related to movements of the vertebral column and head.

The deep muscles of the back include:

- the splenius capitis and cervicis (extensors and rotators of the head and neck)
- the erector spinae and transversospinalis (extensors and rotators of the vertebral column)
- the short segmental muscles.

The erector spinae (highlighted red) is the largest group of intrinsic back muscles, lying posterolateral to the vertebral column between the spinous processes medially and the angles of the ribs laterally. The muscles in the erector spinae group are the primary extensors of the vertebral column and head. Acting bilaterally, they straighten the back, returning it to the upright position from the flexed position, and pull the head posteriorly. Acting unilaterally, they bend the vertebral column laterally.

Flexion of the vertebral column is provided predominantly by the rectus abdominis muscle assisted for rotation by the obliques.

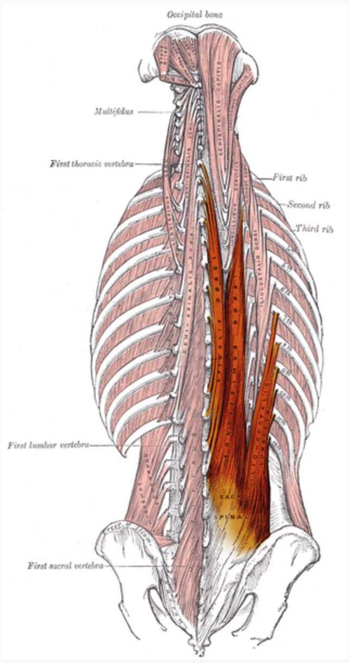

By Henry Vandyke Carter [Public domain], via Wikimedia Commons

< Previous | Next >

Something wrong?

Question Navigator

1 Answered
2 Answered
3 Answered
4 Answered
5 Answered
6 Answered
7 Answered
8 Answered
9 Answered
10 Answered
11 Answered
12 Answered

Clear Exam

©2014 - 2017 FRCEM Success | Website designed & hosted by Cyberfrog Design

Anatomy: Neck

Question 39 of 78

A 31 year old male presents to ED with a penetrating wound to the neck. Imaging shows damage to the structure which run along the course of the anterior scalenus muscle. Which of the following structures is most likely affected:

a Maxillary artery

b Subclavian artery

c Recurrent laryngeal nerve

d Phrenic nerve

e Brachial plexus

< Previous | Next > | See Answer

Something wrong?

Question Navigator

1 Answered
2 Answered
3 Answered
4 Answered
5 Answered
6 Answered
7 Answered
8 Answered
9 Answered
10 Answered
11 Answered
12 Answered

Clear Exam

©2014 - 2017 FRCEM Success | Website designed & hosted by Cyberfrog Design

Anatomy: Neck

Question 39 of 78

A 31 year old male presents to ED with a penetrating wound to the neck. Imaging shows damage to the structure which run along the course of the anterior scalenus muscle. Which of the following structures is most likely affected:

a) Maxillary artery ✗
b) Subclavian artery
c) Recurrent laryngeal nerve
d) Phrenic nerve ✓
e) Brachial plexus

Answer

Passing around the upper lateral border of each anterior scalene muscle, the phrenic nerves continue inferiorly across the anterior surface of the anterior scalene muscle within the prevertebral fascia.

Notes

The phrenic nerves are branches of the cervical plexus, arising on each side as contributions from the anterior rami of C3 – C5 come together.

Passing around the upper lateral border of each anterior scalene muscle, the phrenic nerves continue inferiorly across the anterior surface of the anterior scalene muscle within the prevertebral fascia.

Leaving the lower edge of the anterior scalene muscle, each phrenic nerve passes between the subclavian vein and artery to enter the thorax to continue to the diaphragm.

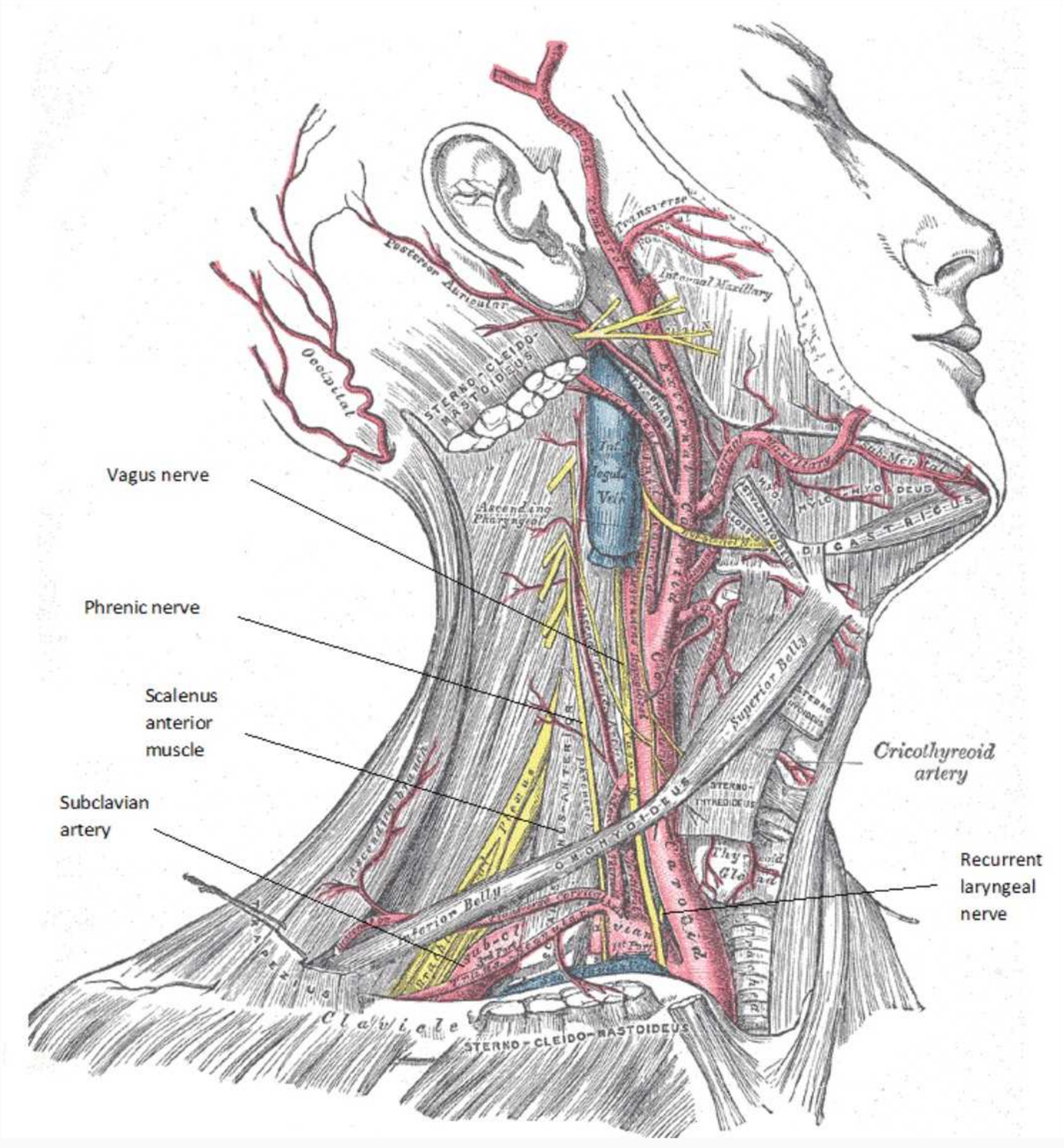

Modified by FRCEM Success. Original by Henry Vandyke Carter [Public domain], via Wikimedia Commons

< Previous | Next >

Something wrong?

Question Navigator

1 Answered
2 Answered
3 Answered
4 Answered
5 Answered
6 Answered
7 Answered
8 Answered
9 Answered
10 Answered
11 Answered
12 Answered

Clear Exam

©2014 - 2017 FRCEM Success | Website designed & hosted by Cyberfrog Design

Anatomy: Neck

Question 40 of 78

A 20 year old factory worker sustains a crush injury to her vertebral column whilst at work. Imaging shows swelling of the spinal cord. Which of the following structures will be trapped between the dura and the vertebral column:

a Anterior longitudinal ligament

b Posterior longitudinal ligament

c Ligamentum flava

d Interspinous ligament

e Supraspinous ligament

< Previous | Next > | See Answer

Something wrong?

Question Navigator

1 Answered
2 Answered
3 Answered
4 Answered
5 Answered
6 Answered
7 Answered
8 Answered
9 Answered
10 Answered
11 Answered
12 Answered

Clear Exam

©2014 - 2017 FRCEM Success | Website designed & hosted by Cyberfrog Design

Anatomy: Neck

Question 40 of 78

A 20 year old factory worker sustains a crush injury to her vertebral column whilst at work. Imaging shows swelling of the spinal cord. Which of the following structures will be trapped between the dura and the vertebral column:

a) Anterior longitudinal ligament ✗
b) Posterior longitudinal ligament ✓
c) Ligamentum flava
d) Interspinous ligament
e) Supraspinous ligament

Answer

The posterior longitudinal ligament interconnects the vertebral bodies and intervertebral discs posteriorly and runs anterior to the spinal cord within the vertebral canal.

Notes

Joints between vertebrae are reinforced by numerous ligaments.

Ligament	Location	Function
Anterior longitudinal ligament	Extends from base of skull to sacrum, attached along its length to vertebral bodies anteriorly	Limits extension of vertebral column, supports annulus fibrosus anteriorly, resists gravitational pull
Posterior longitudinal ligament	Extends from C2 to sacrum, attached along its length to vertebral bodies posteriorly	Limits flexion of vertebral column, supports annulus fibrosus posteriorly, resists gravitational pull
Ligamenta flava	Pass between laminae of adjacent vertebrae	Resist separation of laminae in flexion and assist in extension back to anatomical position
Supraspinous ligament	Passes between and connects tips of spinous processes, extending from C7 to sacrum	Limits flexion of vertebral column
Ligamentum nuchae	Passes between and connects tips of spinous processes, extending from skull to spinous process of C7	Supports head, resists flexion of neck and helps return head to anatomical position
Interspinous ligaments	Pass between spinous processes of adjacent vertebrae	Limit flexion of vertebral column

Ligaments

The anterior longitudinal ligament is attached superiorly to the base of the skull and extends inferiorly to attach to the anterior surface of the sacrum. Along its length it is attached to the vertebral bodies and intervertebral discs anteriorly. The anterior longitudinal ligament acts to limit extension of the vertebral column, support the annulus fibrosus anteriorly and resist gravitational pull.

The posterior longitudinal ligament is on the posterior surface of the vertebral bodies and lines the anterior surface of the vertebral canal. It is attached along its length to the vertebral bodies and intervertebral discs posteriorly. The posterior longitudinal ligament acts to support the posterior aspect of the vertebral bodies and the annulus fibrosus and limit flexion of the vertebral column.

The ligamenta flava, on each side, pass between the laminae of adjacent vertebrae, forming part of the posterior surface of the vertebral canal. The ligamenta flava resist separation of the laminae in flexion and assist in extension back to the anatomical position.

The supraspinous ligament connects and passes along the tips of the vertebral spinous processes from vertebra C7 to the sacrum. From vertebra C7 to the skull, the ligament is more structurally distinct and referred to as the ligamentum nuchae.

The ligamentum nuchae is attached superiorly to the skull (from the external occipital protuberance to the foramen magnum), inferiorly to the spinous process of C7 and between these two points to the spinous processes of the cervical vertebrae. The ligamentum nuchae supports the head, resists flexion and helps to return the head to the anatomical position. The ligament provides attachment for adjacent muscles.

The interspinous ligaments pass between adjacent vertebral spinous processes, blending posteriorly with the supraspinous ligament and anteriorly with the ligamenta flava on each side.

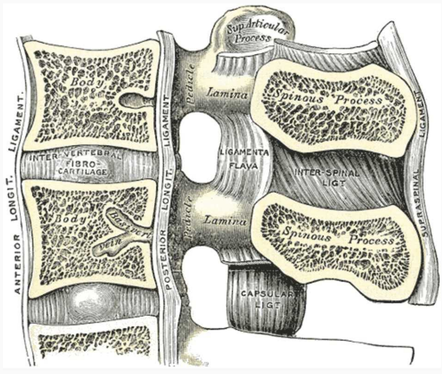

By Henry Vandyke Carter [Public domain], via Wikimedia Commons

< Previous | Next >

Something wrong?

Question Navigator

1 Answered
2 Answered
3 Answered
4 Answered
5 Answered
6 Answered
7 Answered
8 Answered
9 Answered
10 Answered
11 Answered
12 Answered

Clear Exam

©2014 - 2017 FRCEM Success | Website designed & hosted by Cyberfrog Design

Anatomy: Neck

Question 41 of 78

The scalenus anterior muscle originates from which of the following structures:

a Spinous processes of vertebrae C4 – C7.

b Transverse processes of vertebrae C3 – C6.

c Mandible

d Mastoid process

e Hyoid bone

< Previous | Next > | See Answer

Something wrong?

Question Navigator

1 Answered
2 Answered
3 Answered
4 Answered
5 Answered
6 Answered
7 Answered
8 Answered
9 Answered
10 Answered
11 Answered
12 Answered

Clear Exam

©2014 - 2017 FRCEM Success | Website designed & hosted by Cyberfrog Design

Anatomy: Neck

Question 41 of 78

The scalenus anterior muscle originates from which of the following structures:

a) **Spinous processes of vertebrae C4 – C7.** ✗
b) Transverse processes of vertebrae C3 – C6. ✓
c) Mandible
d) Mastoid process
e) Hyoid bone

Answer

The scalenus anterior originates from the anterior tubercles of the transverse processes of vertebrae C3 – C6 and inserts onto the scalene tubercle and upper surface of rib I.

Notes

The scalenus anterior is a synergistic stabiliser of the neck and acts together with the other scalene muscles to elevate rib I.

It originates from the anterior tubercles of the transverse processes of vertebrae C3 – C6 and inserts onto the scalene tubercle and upper surface of rib I.

It is innervated by the anterior rami of C4 – C7.

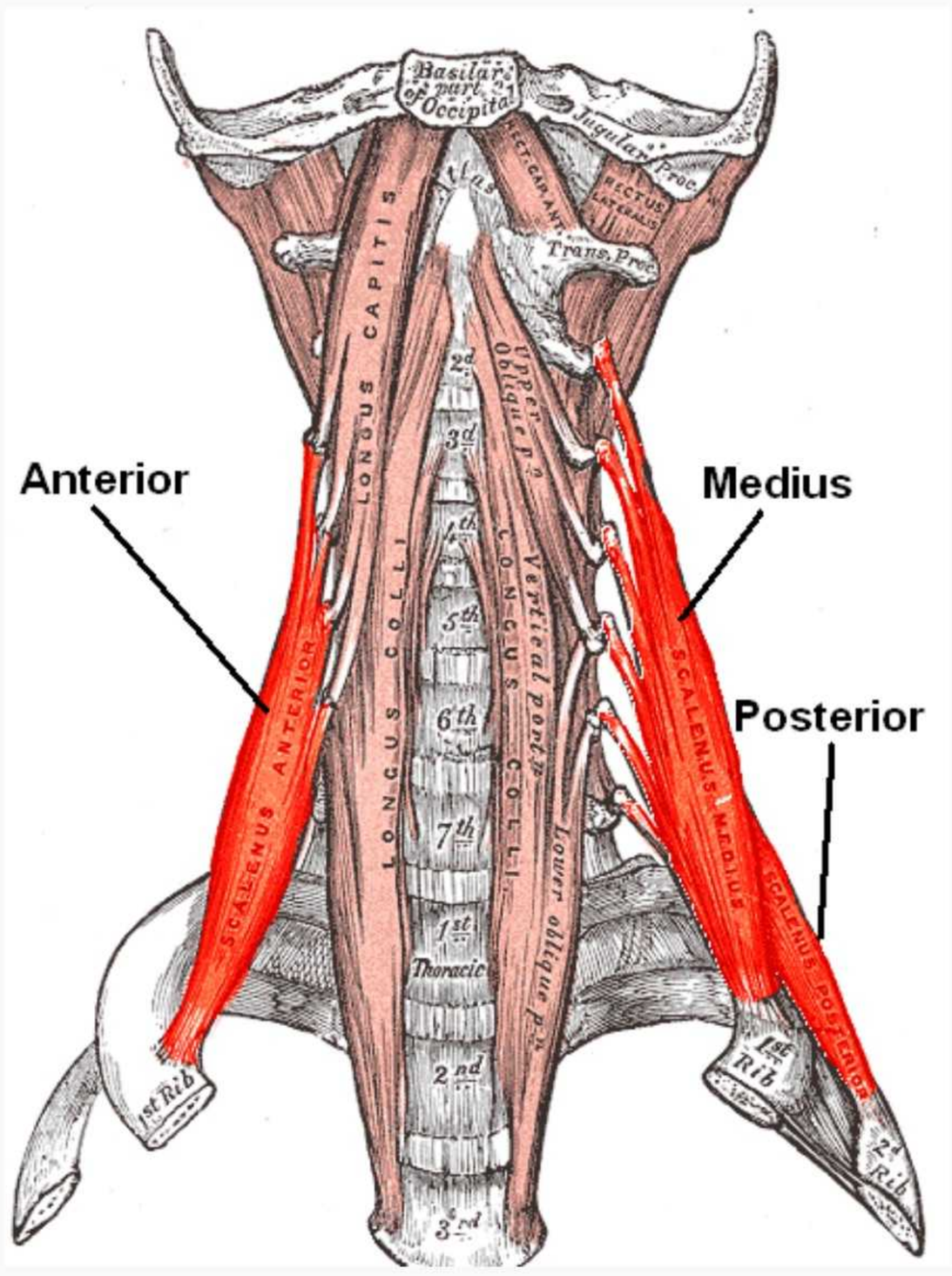

By User:Mikael Häggström (Image:Gray387.png) [Public domain, Public domain or Public domain], via Wikimedia Commons

< Previous | Next > | Something wrong?

Question Navigator

1 Answered
2 Answered
3 Answered
4 Answered
5 Answered
6 Answered
7 Answered
8 Answered
9 Answered
10 Answered
11 Answered
12 Answered

Clear Exam

©2014 - 2017 FRCEM Success | Website designed & hosted by Cyberfrog Design

Anatomy: Neck

Question 42 of 78

In adults the spinal cord usually ends at which vertebral level:

a T12/L1

b L1/L2

c L2/L3

d L3/L4

e L4/L5

< Previous | Next > | See Answer

Something wrong?

Question Navigator

1 Answered
2 Answered
3 Answered
4 Answered
5 Answered
6 Answered
7 Answered
8 Answered
9 Answered
10 Answered
11 Answered
12 Answered

Clear Exam

©2014 - 2017 FRCEM Success | Website designed & hosted by Cyberfrog Design

Anatomy: Neck

Question 42 of 78

In adults the spinal cord usually ends at which vertebral level:

a) T12/L1 ✗
b) L1/L2 ✓
c) L2/L3
d) L3/L4
e) L4/L5

Answer

In adults, the spinal cord typically ends between L1/L2 whereas the subarachnoid space extends to approximately the lower border of vertebra S2.

Notes

The vertebral canal extends from the first cervical vertebra (C1) to the last sacral vertebra (S5). Superiorly the vertebral canal is continuous, through the foramen magnum of the skull, with the cranial cavity.

The vertebral canal is bounded anteriorly by the vertebral bodies, intervertebral discs and the posterior longitudinal ligament, laterally by the vertebral pedicles and posteriorly by the vertebral laminae.

The vertebral canal contains the spinal cord and its protective membranes, together with blood vessels, connective tissue, fat and spinal nerve roots. The conus medullaris is the point below which the canal contains only the cauda equina and filum terminale.

Meninges

The spinal cord is surrounded by a series of three spinal meninges consisting of a dura, arachnoid and pia mater.

The bony walls of the spinal canal are separated from the meninges by the epidural (extradural) space.

The subarachnoid space, containing CSF, is found between the arachnoid and pia mater. The subarachnoid space around the spinal cord is continuous at the foramen magnum with the subarachnoid space surrounding the brain.

Lumbar puncture

In adults, the spinal cord typically ends between L1/L2 whereas the subarachnoid space extends to approximately the lower border of vertebra S2. As a result of this, CSF can be withdrawn from the subarachnoid space in the lower lumbar region without endangering the spinal cord.

When performing a lumbar puncture, the needle passes between adjacent vertebral spinous processes, through the supraspinous and interspinous ligaments and through the ligamentum flavum to enter the extradural space. The needle then continues through the dura and the arachnoid mater to enter the subarachnoid space.

Layers penetrated during lumbar puncture:

- Skin
- Superficial fascia
- Supraspinous ligament
- Interspinous ligament
- Ligamentum flavum (first 'give')
- Extradural space
- Dura mater (second 'give')
- Subdural space
- Arachnoid mater
- Subarachnoid space (containing CSF)

< Previous | Next >

Something wrong?

Question Navigator

1 Answered
2 Answered
3 Answered
4 Answered
5 Answered
6 Answered
7 Answered
8 Answered
9 Answered
10 Answered
11 Answered
12 Answered

Clear Exam

©2014 - 2017 FRCEM Success | Website designed & hosted by Cyberfrog Design

Anatomy: Neck

Question 43 of 78

The sternocleidomastoid muscle inserts onto which of the following structures:

a Mandible

b Mastoid process and superior nuchal line

c Temporomandibular joint

d Hyoid bone

e Zygomatic arch

< Previous | Next > | See Answer

Something wrong?

Question Navigator

1 Answered
2 Answered
3 Answered
4 Answered
5 Answered
6 Answered
7 Answered
8 Answered
9 Answered
10 Answered
11 Answered
12 Answered

Clear Exam

©2014 - 2017 FRCEM Success | Website designed & hosted by Cyberfrog Design

Anatomy: Neck

Question 43 of 78

The sternocleidomastoid muscle inserts onto which of the following structures:

a) Mandible ✗
b) Mastoid process and superior nuchal line ✓
c) Temporomandibular joint
d) Hyoid bone
e) Zygomatic arch

Answer

The sternocleidomastoid muscle has two heads; the sternal head originates from the upper part of the anterior manubrium of the sternum and inserts onto the lateral one-half of the superior nuchal line (occipital bone) and the clavicular head originates from the superior surface of the medial one-third of the clavicle and inserts onto the lateral surface of the mastoid process (temporal bone).

Notes

Muscle	Sternocleidomastoid
Origin	• Sternal head: anterior manubrium of sternum • Clavicular head: medial one-third of clavicle
Insertion	• Sternal head: lateral one-half of superior nuchal line • Clavicular head: lateral mastoid process
Innervation	Accessory nerve (and by branches of anterior rami of C2 – C3)
Action	• Acting unilaterally: lateral rotation of head towards same side and rotation of head towards opposite side • Acting bilaterally: dorsal extension of head

The sternocleidomastoid muscle has two heads; the sternal head originates from the upper part of the anterior manubrium of the sternum and inserts onto the lateral one-half of the superior nuchal line (occipital bone) and the clavicular head originates from the superior surface of the medial one-third of the clavicle and inserts onto the lateral surface of the mastoid process (temporal bone).

The sternocleidomastoid is innervated by the accessory nerve (CN XI) and by branches of anterior rami of C2 – C3.

Individually each muscle will tilt the head towards the shoulder on the same side (lateral flexion) and rotate the head to turn to face the opposite side. Acting together the muscles draw the head forward, through extension of the neck at the atlanto-occipital joints (dorsal extension).

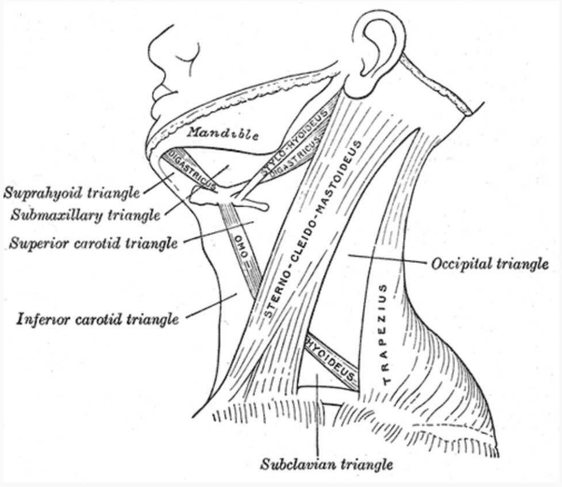

By Henry Vandyke Carter [Public domain], via Wikimedia Commons

< Previous | Next >

Something wrong?

Question Navigator

1 Answered
2 Answered
3 Answered
4 Answered
5 Answered
6 Answered
7 Answered
8 Answered
9 Answered
10 Answered
11 Answered
12 Answered

Clear Exam

©2014 - 2017 FRCEM Success | Website designed & hosted by Cyberfrog Design

Anatomy: Neck

Question 44 of 78

Regarding the neck, which of the following statements is CORRECT:

a The posterior triangle is bounded anteriorly by the anterior margin of the sternocleidomastoid.

b The anterior triangle is bounded superiorly by the inferior margin of the mandible.

c The posterior triangle is bounded posteriorly by the anterior margin of the scalenus anterior.

d The posterior triangle is bounded inferiorly by the lateral one-third of the clavicle.

e The anterior triangle is bounded laterally by the anterior margin of the trapezius muscle.

< Previous | Next > | See Answer

Something wrong?

Question Navigator

1 Answered
2 Answered
3 Answered
4 Answered
5 Answered
6 Answered
7 Answered
8 Answered
9 Answered
10 Answered
11 Answered
12 Answered

Clear Exam

©2014 - 2017 FRCEM Success | Website designed & hosted by Cyberfrog Design

Anatomy: Neck

Question 44 of 78

Regarding the neck, which of the following statements is CORRECT:

a)
The posterior triangle is bounded anteriorly by the anterior margin of the sternocleidomastoid.

b) The anterior triangle is bounded superiorly by the inferior margin of the mandible.

c) The posterior triangle is bounded posteriorly by the anterior margin of the scalenus anterior.

d) The posterior triangle is bounded inferiorly by the lateral one-third of the clavicle.

e) The anterior triangle is bounded laterally by the anterior margin of the trapezius muscle.

Answer

The anterior triangle is bounded superiorly by the inferior margin of the mandible.

Notes

The trapezius and sternocleidomastoid divide the neck into anterior and posterior triangles on each side.

Each anterior triangle is bounded:

- medially by the median vertical line of the neck
- laterally by the anterior margin of the sternocleidomastoid
- superiorly by the inferior margin of the mandible.

Each posterior triangle is bounded:

- anteriorly by the posterior margin of the sternocleidomastoid
- posteriorly by the anterior margin of the trapezius
- basally by the middle one-third of the clavicle
- apically by the occipital bone.

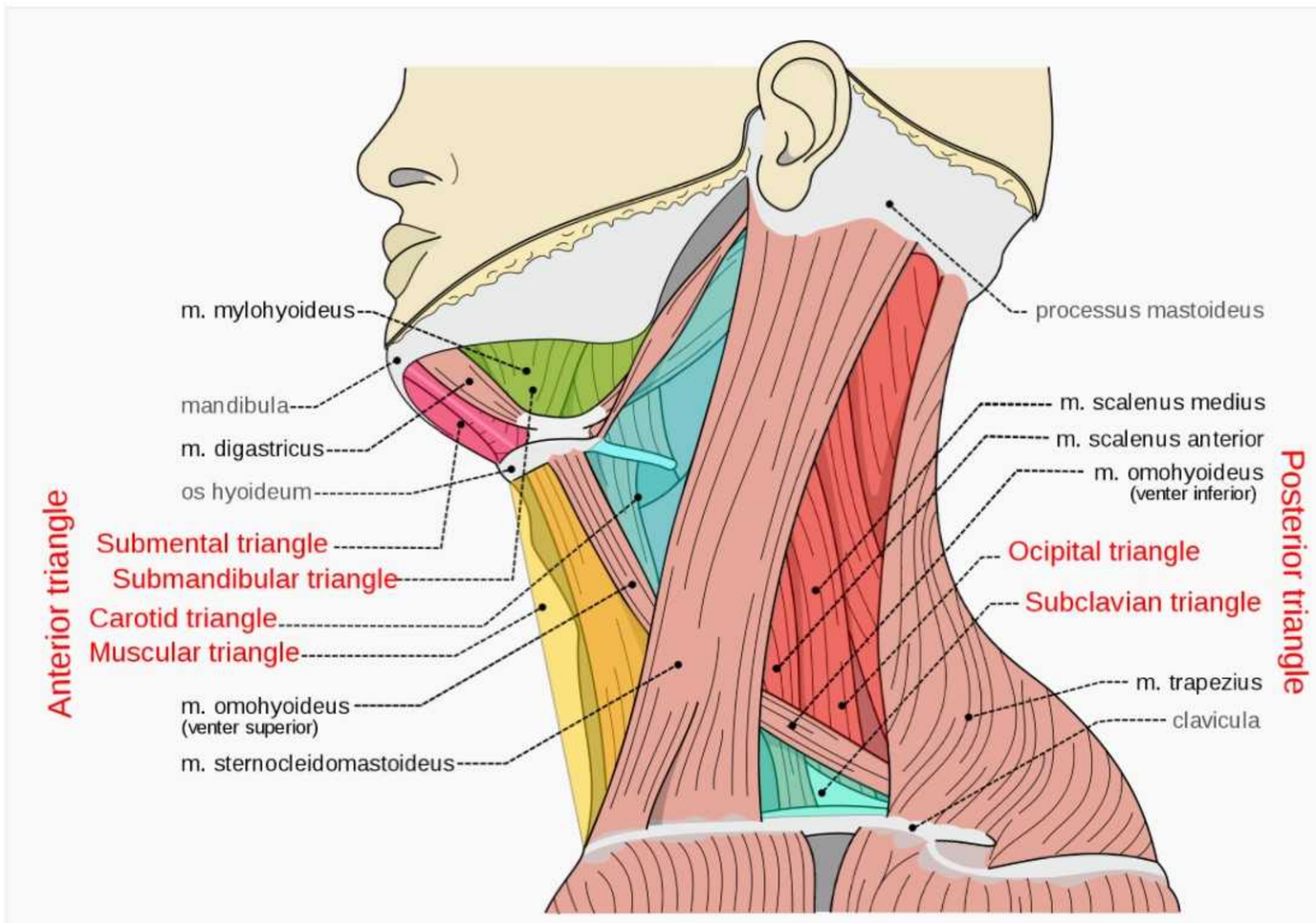

By Olek Remesz (wiki-pl: Orem, commons: Orem) Modified by user:madhero88 (original image File:Musculi coli base.svg) [CC BY 3.0], via Wikimedia Commons

< Previous | Next >

Something wrong?

Question Navigator

1 Answered
2 Answered
3 Answered
4 Answered
5 Answered
6 Answered
7 Answered
8 Answered
9 Answered
10 Answered
11 Answered
12 Answered

Clear Exam

©2014 - 2017 FRCEM Success | Website designed & hosted by Cyberfrog Design

Anatomy: Neck

Question 45 of 78

A 29 year old man is brought to ED having been involved in a road traffic collision in which he has sustained significant trauma to the head and neck. Imaging shows a large haematoma inferior to the left jugular foramen. On examination you note pupillary constriction and ptosis of the right eye, and loss of sweating over the right side of the face. Which of the following ganglia is most likely being compressed:

a Otic ganglion

b Pterygopalatine ganglion

c Submandibular ganglion

d Superior cervical ganglion

e Ciliary ganglion

< Previous | Next > | See Answer

Something wrong?

Question Navigator

1 Answered
2 Answered
3 Answered
4 Answered
5 Answered
6 Answered
7 Answered
8 Answered
9 Answered
10 Answered
11 Answered
12 Answered

Clear Exam

©2014 - 2017 FRCEM Success | Website designed & hosted by Cyberfrog Design

Anatomy: Neck

Question 45 of 78

A 29 year old man is brought to ED having been involved in a road traffic collision in which he has sustained significant trauma to the head and neck. Imaging shows a large haematoma inferior to the left jugular foramen. On examination you note pupillary constriction and ptosis of the right eye, and loss of sweating over the right side of the face. Which of the following ganglia is most likely being compressed:

a) Otic ganglion ✗
b) Pterygopalatine ganglion
c) Submandibular ganglion
d) Superior cervical ganglion ✓
e) Ciliary ganglion

Answer

The superior cervical ganglion, uppermost ganglion of the sympathetic chain, supplies sympathetic innervation to the head and neck. Damage to the sympathetic chain results in Horner's syndrome, characterised by miosis, partial ptosis and anhydrosis. The remaining ganglia are parasympathetic ganglia.

Notes

The sympathetic trunks are two parallel cords that run from the base of the skull to the coccyx. Along the way they are punctuated by ganglia, collections of neuronal cell bodies outside of the CNS. The cervical part of the sympathetic trunk is anterior to the longus colli and longus capitis muscles and posterior to the common carotid artery in the carotid sheath.

There are three ganglia along the course of the sympathetic trunk in the cervical region within which ascending preganglionic sympathetic fibres from upper thoracic spinal cord levels synapse with postganglionic sympathetic fibres. The postganglionic fibres are distributed from these ganglia in branches, called grey rami communicantes, which connect with cervical spinal nerves C1 – C8.

Superior cervical ganglion

The superior cervical ganglion is responsible for sympathetic innervation to the structures in the head and neck. The superior cervical ganglion lies in the area of vertebrae C1 – C2 and has branches to:

- the internal and external carotid arteries
- the cervical spinal nerves C1 – C4
- the pharynx
- the heart.

Middle cervical ganglion

The middle cervical ganglion lies in the area of vertebra C6 and has branches to:

- cervical spinal nerves C5 – C6
- the heart.

Inferior cervical ganglion

The inferior cervical ganglion lies in the area of vertebra C7 (anterior to the neck of rib I, posterior to the first part of the subclavian artery), combines with the first thoracic ganglion to form the cervicothoracic ganglion and has branches to:

- spinal nerves C7 – T1
- the vertebral and subclavian artery
- the heart.

This ganglion may also receive white rami communicantes from thoracic spinal nerves T1 – T2.

Horner's syndrome

The sympathetic fibres can be stretched or damage along their course and if unilaterally disturbed may produce Horner's syndrome, a triad of partial ptosis (due to paralysis of the superior tarsal muscle), miosis (due to paralysis of the dilator pupillae muscle) and anhidrosis (due to loss of innervation to the sweat glands).

Secondary changes may also include ipsilateral vasodilation (due to loss of sympathetic control of subcutaneous blood vessels) and enophthalmos (due to paralysis of the orbitalis muscle).

Possible causes of Horner's syndrome include:

- Apical lung tumour (Pancoast's tumour) eroding the cervicothoracic ganglion
- Thyroid carcinoma
- Penetrating injury to neck
- Lymphadenopathy
- Cervical rib
- Injury to carotid arteries

< Previous | Next >

Something wrong?

Question Navigator

1 Answered
2 Answered
3 Answered
4 Answered
5 Answered
6 Answered
7 Answered
8 Answered
9 Answered
10 Answered
11 Answered
12 Answered

Clear Exam

©2014 - 2017 FRCEM Success | Website designed & hosted by Cyberfrog Design

Anatomy: Neck

Question 46 of 78

The sensory innervation of the nasopharynx is provided by which of the following nerves:

a Glossopharyngeal nerve

b Maxillary nerve

c Mandibular nerve

d Facial nerve

e Vagus nerve

< Previous | Next > | See Answer

Something wrong?

Question Navigator

1 Answered
2 Answered
3 Answered
4 Answered
5 Answered
6 Answered
7 Answered
8 Answered
9 Answered
10 Answered
11 Answered
12 Answered

Clear Exam

©2014 - 2017 FRCEM Success | Website designed & hosted by Cyberfrog Design

Anatomy: Neck

Question 46 of 78

The sensory innervation of the nasopharynx is provided by which of the following nerves:

a) Glossopharyngeal nerve ✗
b) Maxillary nerve ✓
c) Mandibular nerve
d) Facial nerve
e) Vagus nerve

Answer

Each subdivision of the pharynx has a different sensory innervation:

- the nasopharynx is innervated by the maxillary nerve
- the oropharynx is innervated by the glossopharyngeal nerve
- the laryngopharynx is innervated by the vagus nerve.

Notes

The pharynx is a musculofascial structure that connects the oral and nasal cavities in the head to the larynx and the oesophagus in the neck.

The pharynx is attached above to the base of the skull, and is continuous below, approximately at the level of vertebra C6, with the top of the oesophagus.

The pharynx is separated from the posterior vertebral column by a thin retropharyngeal space, bordered anteriorly by the buccopharyngeal fascia and posteriorly by the prevertebral fascia.

Arrangement

The walls of the pharynx are attached anteriorly to the margins of the nasal cavities, oral cavity and larynx, dividing the pharynx into the continuous nasopharynx, oropharynx and laryngopharynx respectively.

The posterior apertures of the nasal cavities open into the nasopharynx, the oropharyngeal isthmus opens into the oropharynx and the superior aperture of the larynx opens into the laryngopharynx.

The pharyngotympanic tubes (from the middle ear) open into the lateral walls of the nasopharynx.

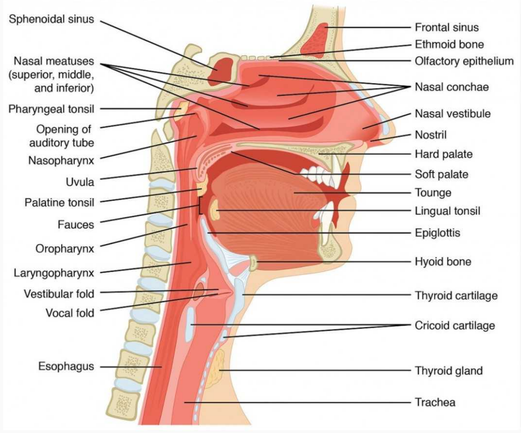

By OpenStax College [CC BY 3.0], via Wikimedia Commons

Muscles

The muscles of the pharyngeal wall are organised into two groups.

The three sheet-like constrictor muscles constrict the pharyngeal cavity sequentially to move a bolus of food through the pharynx and into the oesophagus during swallowing.

The three longitudinal muscles elevate the pharyngeal wall, or during swallowing, pull the pharyngeal wall up and over a bolus of food being moved through the pharynx into the oesophagus.

Nerve supply

The muscles of the pharynx are all innervated by the vagus nerve except for the stylopharyngeus muscle, innervated by the glossopharyngeal nerve. The branches of the vagus and glossopharyngeal nerves form a pharyngeal plexus in the outer fascia of the pharyngeal wall.

Each subdivision of the pharynx has a different sensory innervation:

- the nasopharynx is innervated by the maxillary nerve
- the oropharynx is innervated by the glossopharyngeal nerve
- the laryngopharynx is innervated by the vagus nerve.

Lymphatics

Lymphatic vessels from the pharynx drain into the deep cervical lymph nodes.

< Previous | Next >

Something wrong?

Question Navigator

1 Answered
2 Answered
3 Answered
4 Answered
5 Answered
6 Answered
7 Answered
8 Answered
9 Answered
10 Answered
11 Answered
12 Answered

Clear Exam

©2014 - 2017 FRCEM Success | Website designed & hosted by Cyberfrog Design

Anatomy: Neck

Question 47 of 78

Regarding the ligaments of the spinal column, which of the following statements is INCORRECT:

a The ligamenta flava pass between the laminae of adjacent vertebrae.

b The supraspinous ligament connects and passes along the tips of the vertebral spinous processes.

c The ligamentum nuchae supports the head and resists over-flexion.

d The interspinous ligaments pass between the spinous processes of adjacent vertebrae.

e Above C7, the ligamenta flava becomes the ligamentum nuchae.

< Previous | Next > | See Answer

Something wrong?

Question Navigator

1 Answered
2 Answered
3 Answered
4 Answered
5 Answered
6 Answered
7 Answered
8 Answered
9 Answered
10 Answered
11 Answered
12 Answered

Clear Exam

©2014 - 2017 FRCEM Success | Website designed & hosted by Cyberfrog Design

Anatomy: Neck

Question 47 of 78

Regarding the ligaments of the spinal column, which of the following statements is INCORRECT:

a) **The ligamenta flava pass between the laminae of adjacent vertebrae.** ✖
b) The supraspinous ligament connects and passes along the tips of the vertebral spinous processes.
c) The ligamentum nuchae supports the head and resists over-flexion.
d) The interspinous ligaments pass between the spinous processes of adjacent vertebrae.
e) Above C7, the ligamenta flava becomes the ligamentum nuchae. ✔

Answer

The supraspinous ligament connects and passes along the tips of the vertebral spinous processes from vertebra C7 to the sacrum. From vertebra C7 to the skull, the ligament is more structurally distinct and referred to as the ligamentum nuchae.

Notes

Joints between vertebrae are reinforced by numerous ligaments.

Ligament	Location	Function
Anterior longitudinal ligament	Extends from base of skull to sacrum, attached along its length to vertebral bodies anteriorly	Limits extension of vertebral column, supports annulus fibrosus anteriorly, resists gravitational pull
Posterior longitudinal ligament	Extends from C2 to sacrum, attached along its length to vertebral bodies posteriorly	Limits flexion of vertebral column, supports annulus fibrosus posteriorly, resists gravitational pull
Ligamenta flava	Pass between laminae of adjacent vertebrae	Resist separation of laminae in flexion and assist in extension back to anatomical position
Supraspinous ligament	Passes between and connects tips of spinous processes, extending from C7 to sacrum	Limits flexion of vertebral column
Ligamentum nuchae	Passes between and connects tips of spinous processes, extending from skull to spinous process of C7	Supports head, resists flexion of neck and helps return head to anatomical position
Interspinous ligaments	Pass between spinous processes of adjacent vertebrae	Limit flexion of vertebral column

Ligaments

The anterior longitudinal ligament is attached superiorly to the base of the skull and extends inferiorly to attach to the anterior surface of the sacrum. Along its length it is attached to the vertebral bodies and intervertebral discs anteriorly. The anterior longitudinal ligament acts to limit extension of the vertebral column, support the annulus fibrosus anteriorly and resist gravitational pull.

The posterior longitudinal ligament is on the posterior surface of the vertebral bodies and lines the anterior surface of the vertebral canal. It is attached along its length to the vertebral bodies and intervertebral discs posteriorly. The posterior longitudinal ligament acts to support the posterior aspect of the vertebral bodies and the annulus fibrosus and limit flexion of the vertebral column.

The ligamenta flava, on each side, pass between the laminae of adjacent vertebrae, forming part of the posterior surface of the vertebral canal. The ligamenta flava resist separation of the laminae in flexion and assist in extension back to the anatomical position.

The supraspinous ligament connects and passes along the tips of the vertebral spinous processes from vertebra C7 to the sacrum. From vertebra C7 to the skull, the ligament is more structurally distinct and referred to as the ligamentum nuchae.

The ligamentum nuchae is attached superiorly to the skull (from the external occipital protuberance to the foramen magnum), inferiorly to the spinous process of C7 and between these two points to the spinous processes of the cervical vertebrae. The ligamentum nuchae supports the head, resists flexion and helps to return the head to the anatomical position. The ligament provides attachment for adjacent muscles.

The interspinous ligaments pass between adjacent vertebral spinous processes, blending posteriorly with the supraspinous ligament and anteriorly with the ligamenta flava on each side.

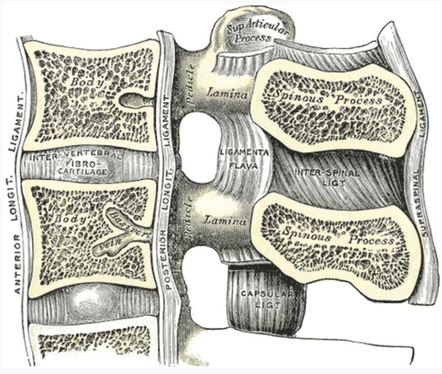

By Henry Vandyke Carter [Public domain], via Wikimedia Commons

< Previous | Next > | Something wrong?

Question Navigator

1 Answered
2 Answered
3 Answered
4 Answered
5 Answered
6 Answered
7 Answered
8 Answered
9 Answered
10 Answered
11 Answered
12 Answered

Clear Exam

©2014 - 2017 FRCEM Success | Website designed & hosted by Cyberfrog Design

Anatomy: Neck

Question 48 of 78

Regarding the larynx, which of the following statements is INCORRECT:

a The cricoid cartilage completely encircles the airway.

b The cricoid cartilage is the largest of the three unpaired cartilages.

c The thyroid cartilage articulates with the hyoid bone superiorly.

d The paired arytenoid cartilages articulate with the cricoid cartilage inferiorly.

e The cricoid cartilage articulates with the inferior horns of the thyroid cartilage posterolaterally.

< Previous | Next > | See Answer

Something wrong?

Question Navigator

1 Answered
2 Answered
3 Answered
4 Answered
5 Answered
6 Answered
7 Answered
8 Answered
9 Answered
10 Answered
11 Answered
12 Answered

Clear Exam

©2014 - 2017 FRCEM Success | Website designed & hosted by Cyberfrog Design

Anatomy: Neck

Question 48 of 78

Regarding the larynx, which of the following statements is INCORRECT:

a) The cricoid cartilage completely encircles the airway. ✗

b) The cricoid cartilage is the largest of the three unpaired cartilages. ✓

c) The thyroid cartilage articulates with the hyoid bone superiorly.

d) The paired arytenoid cartilages articulate with the cricoid cartilage inferiorly.

e) The cricoid cartilage articulates with the inferior horns of the thyroid cartilage posterolaterally.

Answer

The thyroid cartilage is the largest of the laryngeal cartilages. The thyroid cartilage articulates with the cricoid cartilage inferiorly and the hyoid bone superiorly.

Notes

The structure of the larynx is formed from three large unpaired cartilages (cricoid, thyroid, and epiglottis), three smaller paired cartilages (arytenoid, corniculate and cuneiform), joints, ligaments, a fibroelastic membrane and numerous intrinsic muscles.

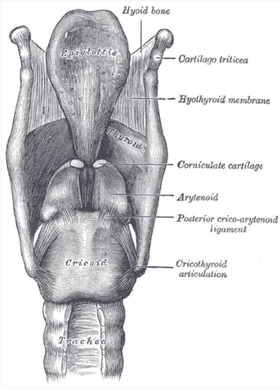

By Henry Vandyke Carter [Public domain], via Wikimedia Commons

Cartilages

The cricoid cartilage is the most inferior of the laryngeal cartilages and completely encircles the airway. The cricoid cartilage articulates with the base of the arytenoid cartilages superiorly (forming the cricoarytenoid joint) and the inferior horns of the thyroid cartilage posterolaterally (forming the cricothyroid joint).

The thyroid cartilage is the largest of the laryngeal cartilages. The thyroid cartilage articulates with the cricoid cartilage inferiorly and the hyoid bone superiorly.

The epiglottis is attached to the posterior aspect of the thyroid cartilage and projects posterosuperiorly. The upper margin of the epiglottis is behind the pharyngeal part of the tongue.

The two arytenoid cartilages articulate inferiorly with the cricoid cartilage and superiorly with the corniculate cartilages.

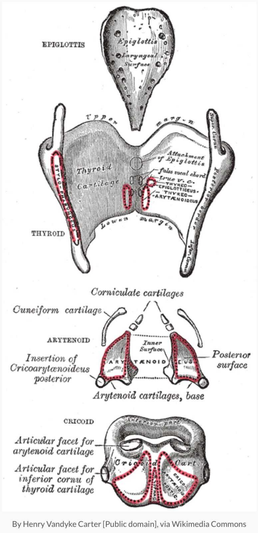

By Henry Vandyke Carter [Public domain], via Wikimedia Commons

Joints

The cricothyroid and cricoarytenoid joints are the main laryngeal joints allowing normal function.

Movements at the cricoarytenoid joints abduct and adduct the vocal ligaments.

Movements at the cricothyroid joint enable the thyroid cartilage to move forward and tilt downwards on the cricoid cartilage which effectively lengthens and puts tension on the vocal ligaments.

Cricothyroid membrane

The cricothyroid membrane (conus elasticus) is attached to the arch of the cricoid cartilage and extends superiorly to end in a free upper margin within the space enclosed by the thyroid cartilage. This upper free margin attaches on each side anteriorly to the thyroid cartilage and posteriorly to the vocal processes of the arytenoid cartilage. The free margin between these two points is thickened to form the vocal ligament which is under the vocal fold of the larynx.

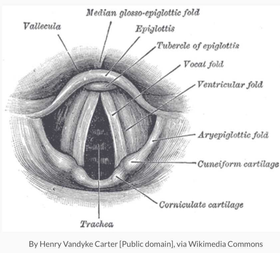

By Henry Vandyke Carter [Public domain], via Wikimedia Commons

The cricothyroid membrane is also thickened anteriorly in the midline to form the distinct median cricothyroid ligament, which spans the distance between the arch of the cricoid cartilage and the thyroid cartilage up to the attachments of the vocal ligaments. In emergency situations, when the airway is blocked above the level of the vocal folds, the median cricothyroid ligament can be perforated to establish an airway (cricothyrotomy).

< Previous | Next >

Something wrong?

Question Navigator

1 Answered
2 Answered
3 Answered
4 Answered
5 Answered
6 Answered
7 Answered
8 Answered
9 Answered
10 Answered
11 Answered
12 Answered

Clear Exam

©2014 - 2017 FRCEM Success | Website designed & hosted by Cyberfrog Design

Anatomy: Neck

Question 49 of 78

Regarding the neck fascia, which of the following statements is INCORRECT:

a The viscera of the neck lie anterior to the prevertebral fascia.

b The prevertebral layer surrounds the prevertebral muscles which act as weak neck flexors.

c The sternocleidomastoid lies superficial to the deep fascia.

d The retropharyngeal space extends from the base of the skull to the upper posterior mediastinum.

e The prevertebral space lies within the prevertebral fascia.

< Previous | Next > | See Answer

Something wrong?

Question Navigator

1 Answered
2 Answered
3 Answered
4 Answered
5 Answered
6 Answered
7 Answered
8 Answered
9 Answered
10 Answered
11 Answered
12 Answered

Clear Exam

©2014 - 2017 FRCEM Success | Website designed & hosted by Cyberfrog Design

Anatomy: Neck

Question 49 of 78

Regarding the neck fascia, which of the following statements is INCORRECT:

a) **The viscera of the neck lie anterior to the prevertebral fascia.** ✖
b) The prevertebral layer surrounds the prevertebral muscles which act as weak neck flexors.
c) The sternocleidomastoid lies superficial to the deep fascia. ✔
d) The retropharyngeal space extends from the base of the skull to the upper posterior mediastinum.
e) The prevertebral space lies within the prevertebral fascia.

Answer

The trapezius and sternocleidomastoid muscles lie within the investing layer of the deep cervical fascia.

Notes

Neck fascia

The neck fascia is divided into the superficial and deep fascia.

The deep fascia is further divided into:

- 1) an investing layer (blue) which lies deep to the superficial fascia and surrounds all structures in the neck
- 2) the prevertebral layer (green) which surrounds the vertebral column and the deep muscles associated with the back
- 3) the pretracheal layer (yellow) which encloses the viscera of the neck (the trachea, oesophagus and thyroid)
- 4) the carotid sheaths (red) which receive a contribution from the other three fascial layers and surround the two major neurovascular bundles on either side of the neck (containing the common carotid artery, the internal carotid artery, the internal jugular vein and the vagus nerve).

The trapezius and sternocleidomastoid muscles lie within the investing layer of the deep cervical fascia.

The viscera of the neck lie anterior to the prevertebral fascia, within the pretracheal layer.

The prevertebral muscles lie within the prevertebral fascial layer and act as weak neck flexors.

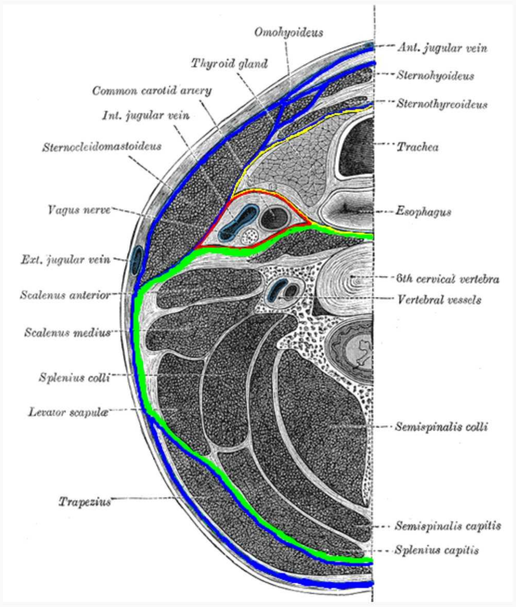

Modified by FRCEM Success. Original by Henry Vandyke Carter [Public domain], via Wikimedia Commons

Neck spaces

Between the fascial layers in the neck are spaces that may provide a conduit for the spread of infections from the neck to the mediastinum:

The pretracheal space lies between the investing layer of cervical fascia and the pretracheal fascia and passes between the neck and the anterior part of the superior mediastinum.

The retropharyngeal space lies between the buccopharyngeal fascia (the part of the pretracheal fascia posterior to the pharynx) and the prevertebral fascia and extends from the base of the skull to the upper part of the posterior mediastinum.

The prevertebral space is within the prevertebral layer as it splits into two laminae, extending from the base of the skull and extends through the posterior mediastinum to the diaphragm.

< Previous | Next >

Something wrong?

Question Navigator

1 Answered
2 Answered
3 Answered
4 Answered
5 Answered
6 Answered
7 Answered
8 Answered
9 Answered
10 Answered
11 Answered
12 Answered

Clear Exam

©2014 - 2017 FRCEM Success | Website designed & hosted by Cyberfrog Design

Anatomy: Neck

Question 50 of 78

How many vertebrae make up the vertebral column:

a 26

b 30

c 33

d 29

e 27

< Previous | Next > | See Answer

Something wrong?

Question Navigator

1 Answered
2 Answered
3 Answered
4 Answered
5 Answered
6 Answered
7 Answered
8 Answered
9 Answered
10 Answered
11 Answered
12 Answered

Clear Exam

©2014 - 2017 FRCEM Success | Website designed & hosted by Cyberfrog Design

Anatomy: Neck

Question 50 of 78

How many vertebrae make up the vertebral column:

a) 26
b) 30 ✗
c) 33 ✓
d) 29
e) 27

Answer

There are 33 vertebrae: seven cervical, twelve thoracic, five lumbar, five fused sacral and four fused coccygeal vertebrae.

Notes

The vertebral column consists of 33 vertebrae: seven cervical, twelve thoracic, five lumbar, five fused sacral and four fused coccygeal vertebrae.

A typical vertebra consists of a vertebral body and a vertebral arch.

The vertebral body is anterior and is separated from adjacent vertebral bodies by fibrocartilaginous intervertebral discs. The size of the vertebral body increases inferiorly as the amount of weight supported increases.

The vertebral arch is anchored to the posterior surface of the vertebral body by two pedicles, which form the lateral pillars of the arch. The roof of the vertebral arch is formed by the right and left laminae which fuse at the midline.

A spinous process projects posteriorly and inferiorly from the roof of the vertebral arch and is a site for muscle and ligament attachment.

On each side of the vertebral arch, a transverse process extends laterally from the region where a lamina meets a pedicle and is a site for articulation with ribs in the thoracic region. From the same region, a superior articular process and an inferior articular process articulate with similar processes on adjacent vertebrae.

The vertebral arches are aligned to form the lateral and posterior walls of the vertebral foramen; the vertebral foramina of all the vertebrae together form the vertebral canal.

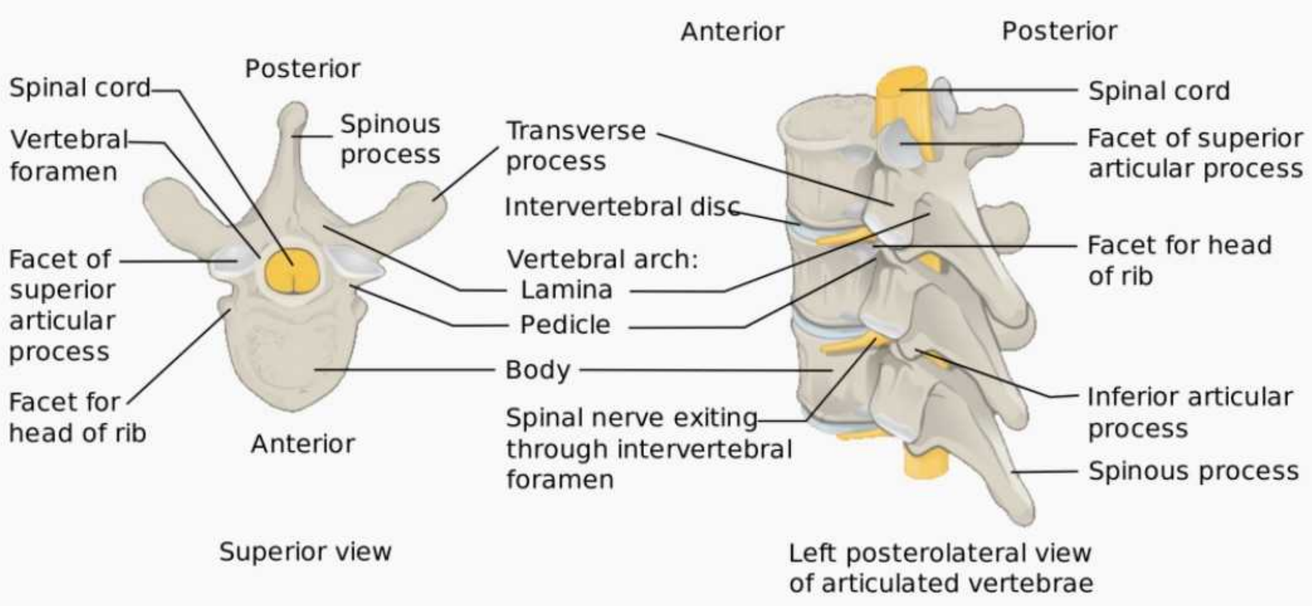

By Jmarchn (Own work) [CC BY-SA 3.0], via Wikimedia Commons

< Previous | Next >

Something wrong?

Question Navigator

1 Answered
2 Answered
3 Answered
4 Answered
5 Answered
6 Answered
7 Answered
8 Answered
9 Answered
10 Answered
11 Answered
12 Answered

Clear Exam

©2014 - 2017 FRCEM Success | Website designed & hosted by Cyberfrog Design

Anatomy: Neck

Question 51 of 78

Which of the following nerves curves under and behind the subclavian artery before ascending in the neck:

a Accessory nerve

b Right superior laryngeal nerve

c Left superior laryngeal nerve

d Right recurrent laryngeal nerve

e Left recurrent laryngeal nerve

< Previous | Next > | See Answer

Something wrong?

Question Navigator

1 Answered
2 Answered
3 Answered
4 Answered
5 Answered
6 Answered
7 Answered
8 Answered
9 Answered
10 Answered
11 Answered
12 Answered

Clear Exam

©2014 - 2017 FRCEM Success | Website designed & hosted by Cyberfrog Design

Anatomy: Neck

Question 51 of 78

Which of the following nerves curves under and behind the subclavian artery before ascending in the neck:

a) Accessory nerve ✖
b) Right superior laryngeal nerve
c) Left superior laryngeal nerve
d) Right recurrent laryngeal nerve ✔
e) Left recurrent laryngeal nerve

Answer

The right recurrent laryngeal nerve originates in the root of the neck, as a branch of the right vagus nerve as it reaches the lower edge of the first part of the subclavian artery. It passes around the subclavian artery and travels upwards and medially in a groove between the trachea and the oesophagus as it heads to the larynx.

Notes

The right recurrent laryngeal nerve originates in the root of the neck, as a branch of the right vagus nerve as it reaches the lower edge of the first part of the subclavian artery. It passes around the subclavian artery and travels upwards and medially in a groove between the trachea and the oesophagus as it heads to the larynx.

The left recurrent laryngeal nerve originates more inferiorly, from the left vagus nerve as it crosses the arch of the aorta in the superior mediastinum. It passes below and behind the arch of the aorta and then ascends beside the trachea to the larynx.

Damage to the recurrent laryngeal nerves may result in hoarseness, respiratory obstruction, inability to speak and loss of sensation below the vocal cord.

Causes of damage include:

- thyroid/parathyroid surgery
- mediastinal lymphadenopathy
- cricothyroidotomy
- aneurysm of the aortic arch
- lung cancer in the apex of the right lung
- malignancy infiltrating into the 'aortopulmonary window'.

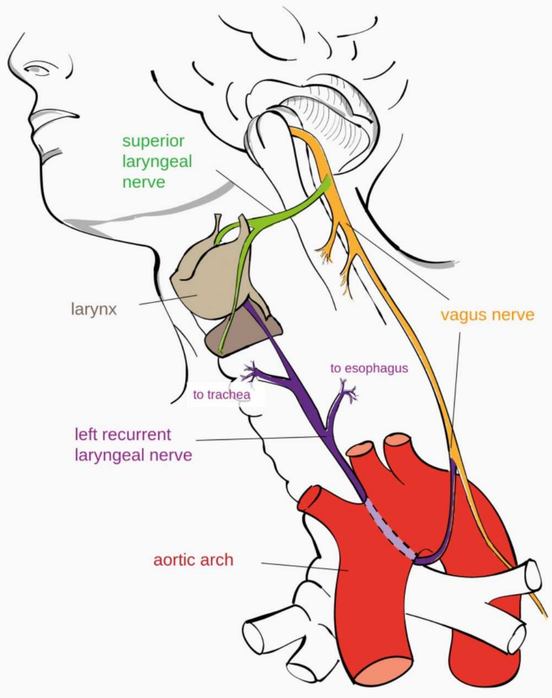

By Jkwchui (Based on drawing by Truth-seeker2004) [CC BY-SA 3.0 (http://creativecommons.org/licenses/by-sa/3.0)], via Wikimedia Commons

< Previous | Next >

Something wrong?

Question Navigator

1 Answered
2 Answered
3 Answered
4 Answered
5 Answered
6 Answered
7 Answered
8 Answered
9 Answered
10 Answered
11 Answered
12 Answered

Clear Exam

©2014 - 2017 FRCEM Success | Website designed & hosted by Cyberfrog Design

Anatomy: Neck

Question 52 of 78

Regarding the tonsils, which of the following statements is CORRECT:

a The adenoid tonsils are found on the lateral walls of the oropharynx.

b The palatine tonsils drain mainly to the jugulodigastric lymph node.

c The palatine tonsils are found on the lateral walls of the nasopharynx.

d The lingual tonsil is found on the anterior two-thirds of the tongue.

e The palatine tonsils lie just posterior to the palatopharyngeal arch.

< Previous | Next > | See Answer

Something wrong?

Question Navigator

1 Answered
2 Answered
3 Answered
4 Answered
5 Answered
6 Answered
7 Answered
8 Answered
9 Answered
10 Answered
11 Answered
12 Answered

Clear Exam

©2014 - 2017 FRCEM Success | Website designed & hosted by Cyberfrog Design

Anatomy: Neck

Question 52 of 78

Regarding the tonsils, which of the following statements is CORRECT:

a) **The adenoid tonsils are found on the lateral walls of the oropharynx.** ✗
b) The palatine tonsils drain mainly to the jugulodigastric lymph node. ✓
c) The palatine tonsils are found on the lateral walls of the nasopharynx.
d) The lingual tonsil is found on the anterior two-thirds of the tongue.
e) The palatine tonsils lie just posterior to the palatopharyngeal arch.

Answer

The lymphatic drainage of the palatine tonsils drains through the pharyngeal wall into the jugulodigastric nodes in the region where the facial vein drains into the internal jugular vein, inferior to the posterior belly of the digastric muscle.

Notes

Large collections of lymphoid tissue are found on the pharyngeal surface (posterior one-third) of the tongue and collectively known as the lingual tonsil.

The adenoid (pharyngeal) tonsil is a large collection of lymphoid tissue in the mucosa covering the roof of the nasopharynx.

The palatine tonsils are on the lateral walls of the oropharynx. On each side there is a large ovoid collection of lymphoid tissue in the mucosa lining the superior constrictor muscle, between the palatoglossal and palatopharyngeal arches and just posterior to the oropharyngeal isthmus.

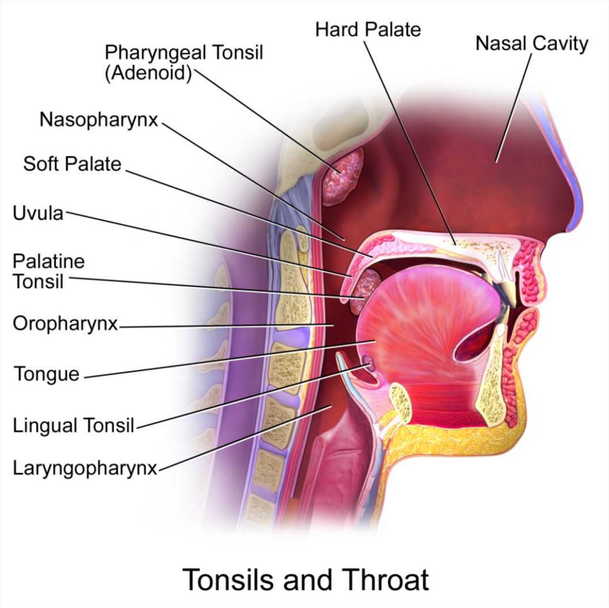

By Blausen.com staff. "Blausen gallery 2014". Wikiversity Journal of Medicine. DOI:10.15347/wjm/2014.010. ISSN 20018762. (Own work) [CC BY 3.0 (http://creativecommons.org/licenses/by/3.0)], via Wikimedia Commons

Blood supply

The palatine tonsils are highly vascular, receiving blood from the ascending palatine and tonsillar branches of the facial artery, the descending palatine branch of the maxillary artery, a palatine branch of the ascending pharyngeal artery and a branch of the lingual artery.

Tonsillectomy may result in severe haemorrhage, which may occur from the branches of the facial, ascending pharyngeal, maxillary and lingual arteries, or from paratonsillar veins.

Lymphatics

The lymphatic drainage of the palatine tonsils drains through the pharyngeal wall into the jugulodigastric nodes in the region where the facial vein drains into the internal jugular vein, inferior to the posterior belly of the digastric muscle.

< Previous | Next >

Something wrong?

Question Navigator

1 Answered
2 Answered
3 Answered
4 Answered
5 Answered
6 Answered
7 Answered
8 Answered
9 Answered
10 Answered
11 Answered
12 Answered

Clear Exam

©2014 - 2017 FRCEM Success | Website designed & hosted by Cyberfrog Design

Anatomy: Neck

Question 53 of 78

Regarding the ligaments of the spinal column, which of the following statements is CORRECT:

a The anterior longitudinal ligament lines the anterior surface of the vertebral canal.

b The posterior longitudinal ligament lines the posterior surface of the vertebral canal.

c The ligamenta flava pass between the transverse processes of adjacent vertebrae.

d The posterior longitudinal ligament limits extension of the vertebral column.

e The ligamentum nuchae resists flexion of the neck and helps return the head to the anatomical position.

< Previous | Next > | See Answer

Something wrong?

Question Navigator

1 Answered
2 Answered
3 Answered
4 Answered
5 Answered
6 Answered
7 Answered
8 Answered
9 Answered
10 Answered
11 Answered
12 Answered

Clear Exam

©2014 - 2017 FRCEM Success | Website designed & hosted by Cyberfrog Design

Anatomy: Neck

Question 53 of 78

Regarding the ligaments of the spinal column, which of the following statements is CORRECT:

a) ✖
The anterior longitudinal ligament lines the anterior surface of the vertebral canal.
b) The posterior longitudinal ligament lines the posterior surface of the vertebral canal.
c) The ligamenta flava pass between the transverse processes of adjacent vertebrae.
d) The posterior longitudinal ligament limits extension of the vertebral column.
e) ✔
The ligamentum nuchae resists flexion of the neck and helps return the head to the anatomical position.

Answer

The ligamentum nuchae is attached superiorly to the skull (from the external occipital protuberance to the foramen magnum), inferiorly to the spinous process of C7 and between these two points to the spinous processes of the cervical vertebrae. The ligamentum nuchae supports the head, resists flexion and helps to return the head to the anatomical position. The ligament provides attachment for adjacent muscles.

Notes

Joints between vertebrae are reinforced by numerous ligaments.

Ligament	Location	Function
Anterior longitudinal ligament	Extends from base of skull to sacrum, attached along its length to vertebral bodies anteriorly	Limits extension of vertebral column, supports annulus fibrosus anteriorly, resists gravitational pull
Posterior longitudinal ligament	Extends from C2 to sacrum, attached along its length to vertebral bodies posteriorly	Limits flexion of vertebral column, supports annulus fibrosus posteriorly, resists gravitational pull
Ligamenta flava	Pass between laminae of adjacent vertebrae	Resist separation of laminae in flexion and assist in extension back to anatomical position
Supraspinous ligament	Passes between and connects tips of spinous processes, extending from C7 to sacrum	Limits flexion of vertebral column
Ligamentum nuchae	Passes between and connects tips of spinous processes, extending from skull to spinous process of C7	Supports head, resists flexion of neck and helps return head to anatomical position
Interspinous ligaments	Pass between spinous processes of adjacent vertebrae	Limit flexion of vertebral column

Ligaments

The anterior longitudinal ligament is attached superiorly to the base of the skull and extends inferiorly to attach to the anterior surface of the sacrum. Along its length it is attached to the vertebral bodies and intervertebral discs anteriorly. The anterior longitudinal ligament acts to limit extension of the vertebral column, support the annulus fibrosus anteriorly and resist gravitational pull.

The posterior longitudinal ligament is on the posterior surface of the vertebral bodies and lines the anterior surface of the vertebral canal. It is attached along its length to the vertebral bodies and intervertebral discs posteriorly. The posterior longitudinal ligament acts to support the posterior aspect of the vertebral bodies and the annulus fibrosus and limit flexion of the vertebral column.

The ligamenta flava, on each side, pass between the laminae of adjacent vertebrae, forming part of the posterior surface of the vertebral canal. The ligamenta flava resist separation of the laminae in flexion and assist in extension back to the anatomical position.

The supraspinous ligament connects and passes along the tips of the vertebral spinous processes from vertebra C7 to the sacrum. From vertebra C7 to the skull, the ligament is more structurally distinct and referred to as the ligamentum nuchae.

The ligamentum nuchae is attached superiorly to the skull (from the external occipital protuberance to the foramen magnum), inferiorly to the spinous process of C7 and between these two points to the spinous processes of the cervical vertebrae. The ligamentum nuchae supports the head, resists flexion and helps to return the head to the anatomical position. The ligament provides attachment for adjacent muscles.

The interspinous ligaments pass between adjacent vertebral spinous processes, blending posteriorly with the supraspinous ligament and anteriorly with the ligamenta flava on each side.

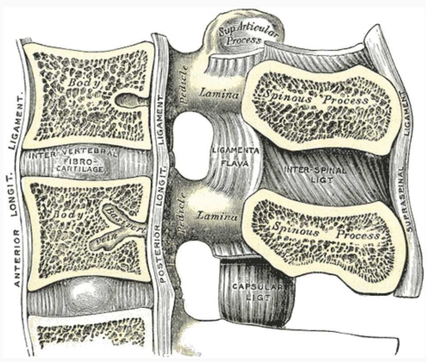

By Henry Vandyke Carter [Public domain], via Wikimedia Commons

< Previous | Next >

Something wrong?

Question Navigator

1 Answered
2 Answered
3 Answered
4 Answered
5 Answered
6 Answered
7 Answered
8 Answered
9 Answered
10 Answered
11 Answered
12 Answered

Clear Exam

©2014 - 2017 FRCEM Success | Website designed & hosted by Cyberfrog Design

Anatomy: Neck

Question 54 of 78

The sensation produced by touching the arm with cotton wool during a neurological examination is mediated by which of the following spinal tracts:

a Anterior spinothalamic tract

b Lateral spinothalamic tract

c Anterior corticospinal tract

d Posterior column

e Anterior spinocerebellar tract

< Previous | Next > | See Answer

Something wrong?

Question Navigator

1 Answered
2 Answered
3 Answered
4 Answered
5 Answered
6 Answered
7 Answered
8 Answered
9 Answered
10 Answered
11 Answered
12 Answered

Clear Exam

©2014 - 2017 FRCEM Success | Website designed & hosted by Cyberfrog Design

Anatomy: Neck

Question 14 of 78

The sensation produced by touching the arm with cotton wool during a neurological examination is mediated by which of the following spinal tracts:

a) **Anterior spinothalamic tract** ✗
b) Lateral spinothalamic tract
c) Anterior corticospinal tract
d) Posterior column ✓
e) Anterior spinocerebellar tract

Answer

Fine-touch, proprioception and vibration sensation are mediated by the posterior column-medial lemniscus pathway.

Notes

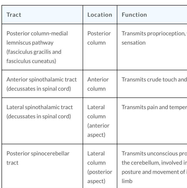

By Polarlys and Mikael Häggström [CC BY-SA 3.0 (http://creativecommons.org/licenses/by-sa/3.0) or GFDL (http://www.gnu.org/copyleft/fdl.html)], via Wikimedia Commons

Ascending tracts

The ascending spinal cord tracts represent functional pathways that convey sensory information from the periphery to higher levels.

Tract	Location	Function
Posterior column-medial lemniscus pathway (fasciculus gracilis and fasciculus cuneatus)	Posterior column	Transmits proprioception, vibration and fine-touch sensation
Anterior spinothalamic tract (decussates in spinal cord)	Anterior column	Transmits crude touch and pressure sensation
Lateral spinothalamic tract (decussates in spinal cord)	Lateral column (anterior aspect)	Transmits pain and temperature sensation
Posterior spinocerebellar tract	Lateral column (posterior aspect)	Transmits unconscious proprioceptive information to the cerebellum, involved in fine coordination of posture and movement of individual muscles of lower limb
Anterior spinocerebellar tract	Lateral column (anterior aspect)	Transmits unconscious proprioceptive information to the cerebellum, involved with coordination movement and posture of the entire lower limb

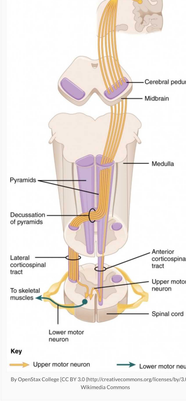

By OpenStax College [CC BY 3.0 (http://creativecommons.org/licenses/by/3.0)], via Wikimedia Commons

Descending tracts

The descending tracts are functional pathways concerned with somatic and visceral motor activities.

Tract	Location	Function
Lateral corticospinal tract	Lateral column (posterior aspect)	Involved in voluntary skilled motor activity of limbs
Anterior corticospinal tract (decussates in spinal cord)	Anterior column	Involved with control of axial muscles

By OpenStax College [CC BY 3.0 (http://creativecommons.org/licenses/by/3.0)], via Wikimedia Commons

Clinical implications

Spinal cord syndrome	Mechanism	Tracts affected	Clinical features
Complete cord transection	Major trauma	All tracts	Death (C1 – C3); paralysis of voluntary/automatic breathing (above C5), quadriplegia (C4 – C5), paraplegia (below T1), UMN paralysis below lesion, complete sensory loss below lesion, urinary and faecal incontinence, anhidrosis and loss of vasomotor tone
Brown-Sequard syndrome (hemisection)	Penetrating trauma	All tracts on one side	Ipsilateral UMN paralysis below lesion, ipsilateral loss of proprioception/vibration/fine touch sensation below lesion, contralateral loss of crude touch/pain/temperature sensation below lesion, bilateral lower limb ataxia
Central cord syndrome	Hyperextension injury of cervical spine in patient with pre-existing cervical stenosis	Lateral corticospinal tract, spinothalamic tract	Bilateral sensory loss and UMN motor loss below lesion with greater loss in upper limbs than lower limbs, and greater loss of motor function than sensory function
Anterior cord syndrome	Occlusion of anterior spinal artery with infarction of territory supplied	Corticospinal, spinothalamic and spinocerebellar	Paralysis of voluntary/automatic breathing, faecal and urinary incontinence, bilateral Horner's syndrome, bilateral flaccid paralysis at level of lesion, bilateral spastic paralysis below lesion, bilateral loss of crude touch/pain/temperature sensation below lesion, cerebellar incoordination

by Fjjacquot, via Wikimedia Commons

Question Navigator

1 Answered
2 Answered
3 Answered
4 Answered
5 Answered
6 Answered
7 Answered
8 Answered
9 Answered
10 Answered
11 Answered
12 Answered

Clear Exam

< Previous | Next >

Something wrong?

©2014 - 2017 FRCEM Success | Website designed & hosted by Cyberfrog Design

Anatomy: Neck

Question 55 of 78

A 29 year old male racing driver has fractured a cervical vertebra. On examination, he has weakness of the right side of his body with upgoing plantars, loss of pain and temperature sensation in his left limbs, with normal fine-touch sensation over all four limbs. This clinical picture is most likely seen in a lesion of the:

a Anterior column, left side

b Anterior column, right side

c Lateral column, right side

d Lateral column, left side

e Posterior column, right side

< Previous | Next > | See Answer

Something wrong?

Question Navigator

1 Answered
2 Answered
3 Answered
4 Answered
5 Answered
6 Answered
7 Answered
8 Answered
9 Answered
10 Answered
11 Answered
12 Answered

Clear Exam

©2014 - 2017 FRCEM Success | Website designed & hosted by Cyberfrog Design

Anatomy: Neck

Question 55 of 78

A 29 year old male racing driver has fractured a cervical vertebra. On examination, he has weakness of the right side of his body with upgoing plantars, loss of pain and temperature sensation in his left limbs, with normal fine-touch sensation over all four limbs. This clinical picture is most likely seen in a lesion of the:

a) **Anterior column, left side** ✗
b) Anterior column, right side
c) Lateral column, right side ✓
d) Lateral column, left side
e) Posterior column, right side

Answer

The lesion is likely affecting the corticospinal and lateral spinothalamic tracts in the lateral column. Motor power of the limbs is mediated by the ipsilateral corticospinal tract, and pain and temperature sensation is mediated by the contralateral spinothalamic tract, therefore the lesion is likely on the right side. The posterior column is spared, as fine-touch sensation is normal throughout.

Notes

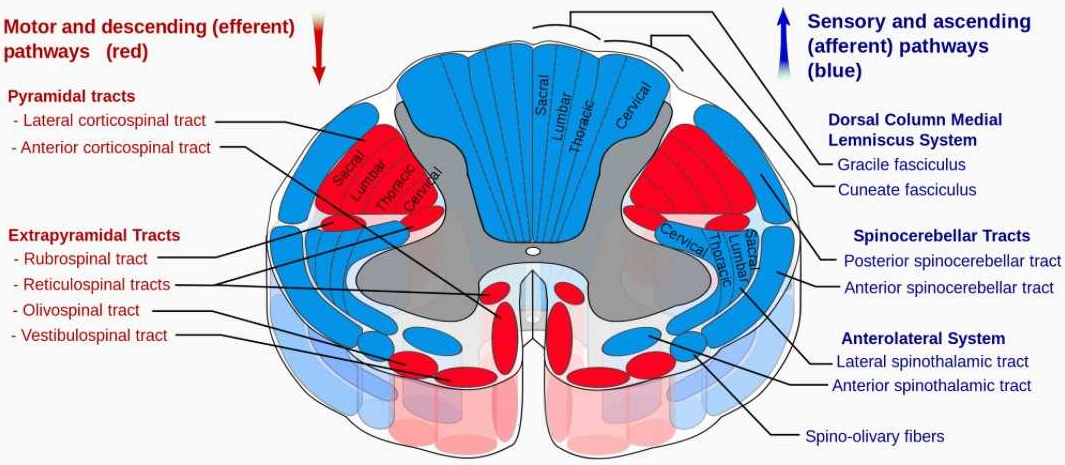

By Polarlys and Mikael Häggström [CC BY-SA 3.0 (http://creativecommons.org/licenses/by-sa/3.0) or GFDL (http://www.gnu.org/copyleft/fdl.html)], via Wikimedia Commons

Ascending tracts

The ascending spinal cord tracts represent functional pathways that convey sensory information from the periphery to higher levels.

Question Navigator

1 Answered
2 Answered
3 Answered
4 Answered
5 Answered
6 Answered
7 Answered
8 Answered
9 Answered
10 Answered
11 Answered
12 Answered

Clear Exam

Tract	Location	Function
Posterior column-medial lemniscus pathway (fasciculus gracilis and fasciculus cuneatus)	Posterior column	Transmits proprioception, vibration and fine-touch sensation
Anterior spinothalamic tract (decussates in spinal cord)	Anterior column	Transmits crude touch and pressure sensation
Lateral spinothalamic tract (decussates in spinal cord)	Lateral column (anterior aspect)	Transmits pain and temperature sensation
Posterior spinocerebellar tract	Lateral column (posterior aspect)	Transmits unconscious proprioceptive information to the cerebellum, involved in fine coordination of posture and movement of individual muscles of lower limb
Anterior spinocerebellar tract	Lateral column (anterior aspect)	Transmits unconscious proprioceptive information to the cerebellum, involved with coordination movement and posture of the entire lower limb

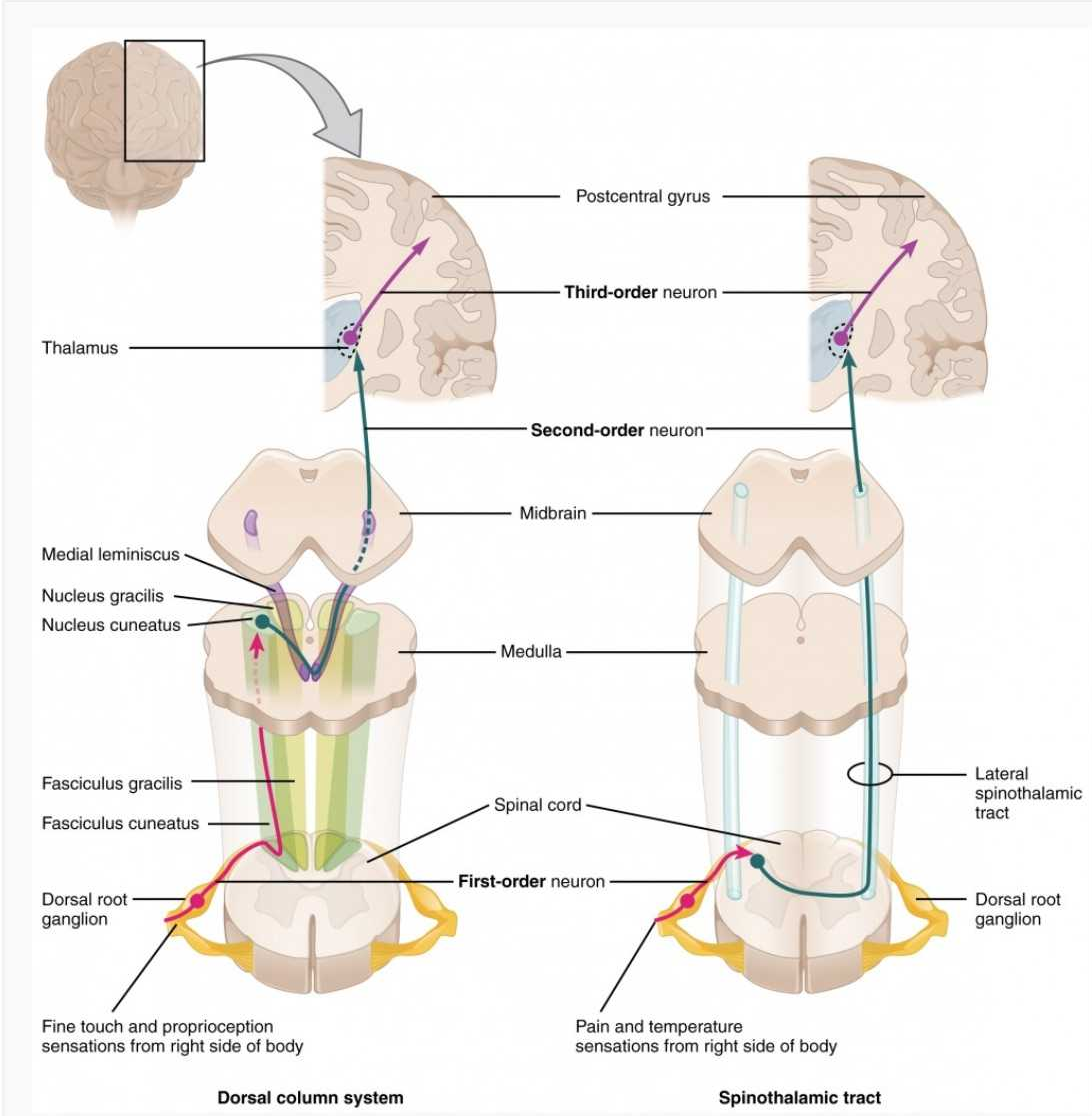

By OpenStax College [CC BY 3.0 (http://creativecommons.org/licenses/by/3.0)], via Wikimedia Commons

Descending tracts

The descending tracts are functional pathways concerned with somatic and visceral motor activities.

Tract	Location	Function
Lateral corticospinal tract	Lateral column (posterior aspect)	Involved in voluntary skilled motor activity of limbs
Anterior corticospinal tract (decussates in spinal cord)	Anterior column	Involved with control of axial muscles

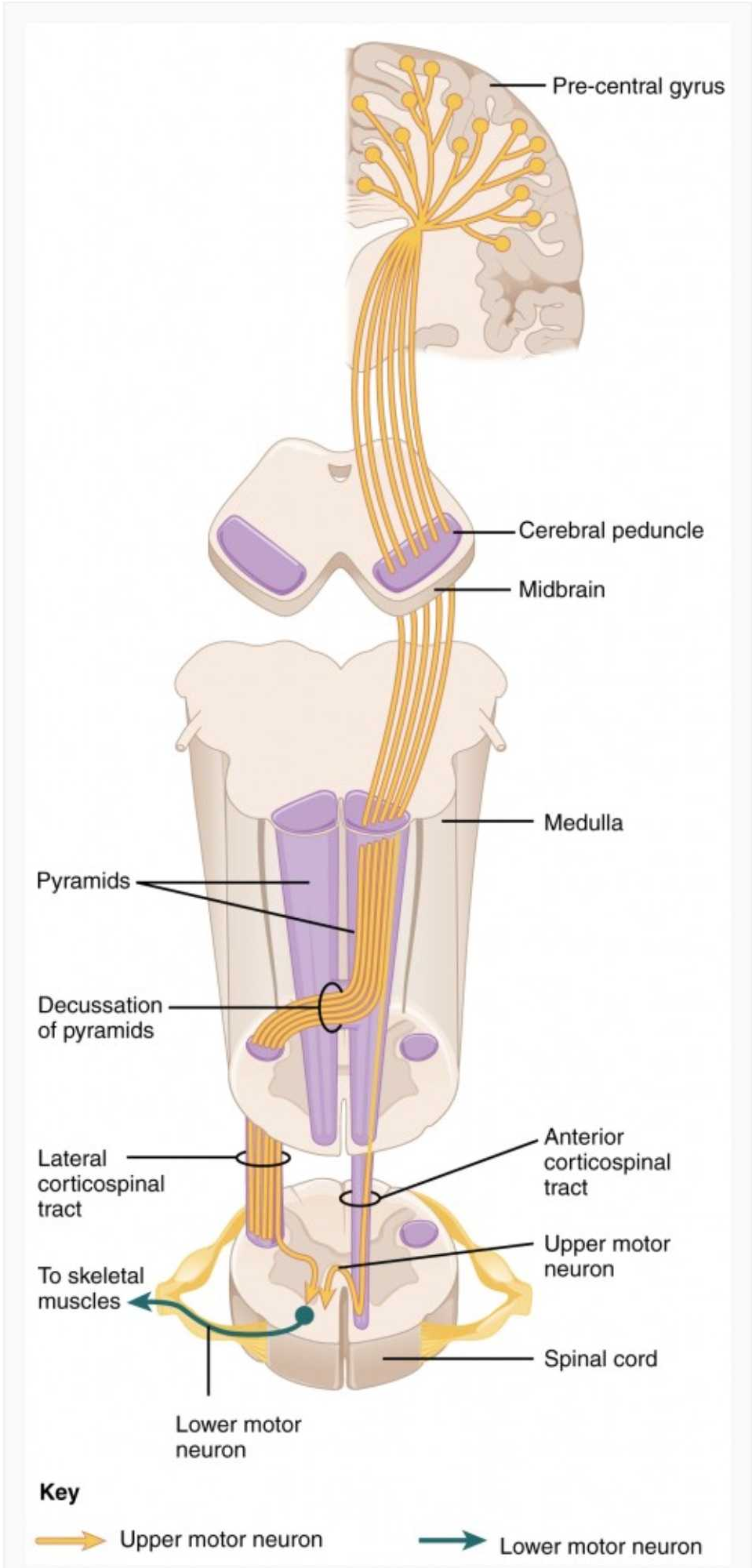

By OpenStax College [CC BY 3.0 (http://creativecommons.org/licenses/by/3.0)], via Wikimedia Commons

Clinical implications

Spinal cord syndrome	Mechanism	Tracts affected	Clinical features
Complete cord transection	Major trauma	All tracts	Death (C1 – C3), paralysis of voluntary/automatic breathing (above C5), quadriplegia (C4 – C5), paraplegia (below T1), UMN paralysis below lesion, complete sensory loss below lesion, urinary and faecal incontinence, anhidrosis and loss of vasomotor tone
Brown-Sequard syndrome (hemisection)	Penetrating trauma	All tracts on one side	Ipsilateral UMN paralysis below lesion, ipsilateral loss of proprioception/vibration/fine touch sensation below lesion, contralateral loss of crude touch/pain/temperature sensation below lesion, bilateral lower limb ataxia
Central cord syndrome	Hyperextension injury of cervical spine in patient with pre-existing cervical stenosis	Lateral corticospinal tract, spinothalamic tract	Bilateral sensory loss and UMN motor loss below lesion with greater loss in upper limbs than lower limbs, and greater loss of motor function than sensory function
Anterior cord syndrome	Occlusion of anterior spinal artery with infarction of territory supplied	Corticospinal, spinothalamic and spinocerebellar	Paralysis of voluntary/automatic breathing, faecal and urinary incontinence, bilateral Horner's syndrome, bilateral flaccid paralysis at level of lesion, bilateral spastic paralysis below lesion, bilateral loss of crude touch/pain/temperature sensation below lesion, cerebellar incoordination

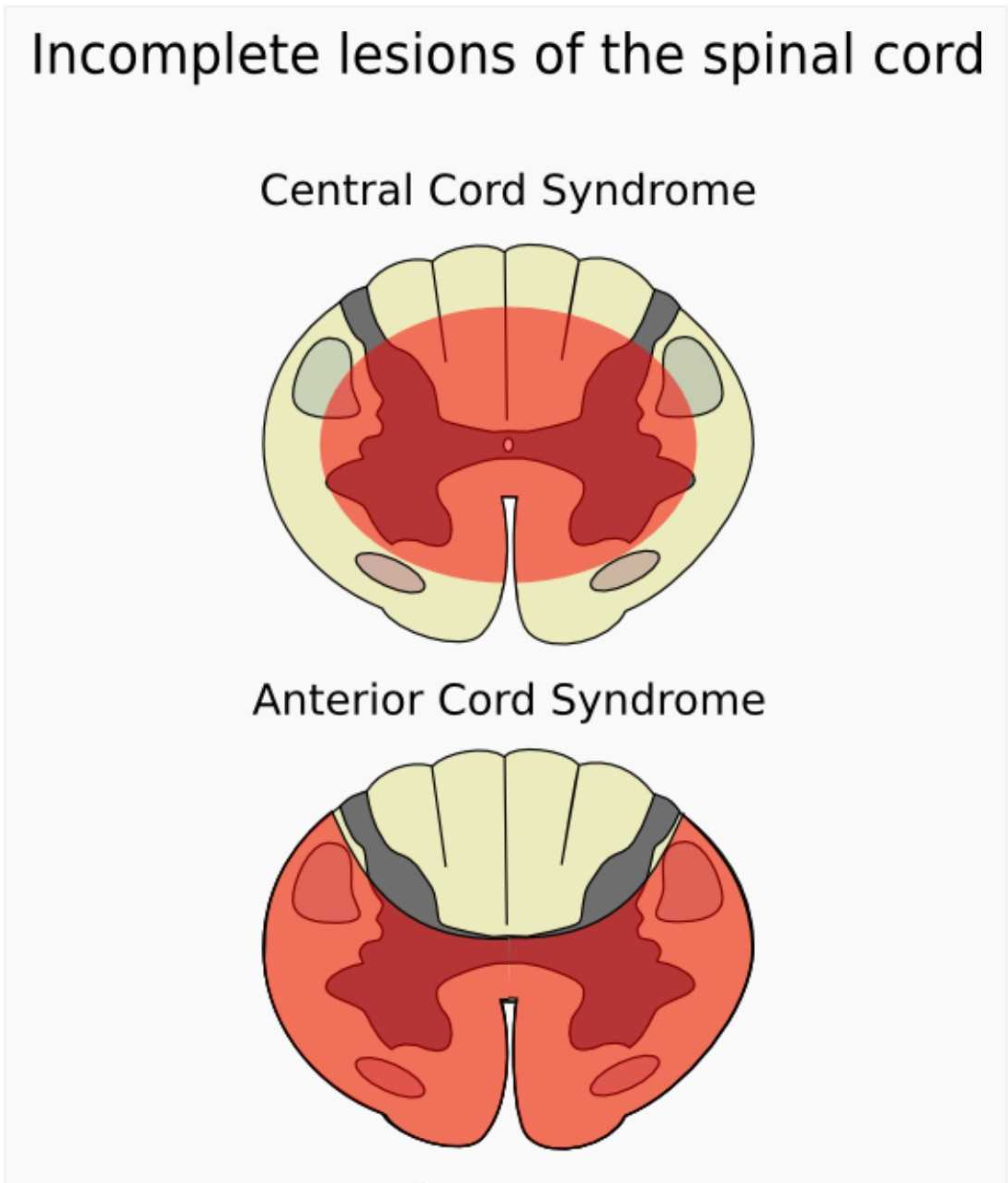

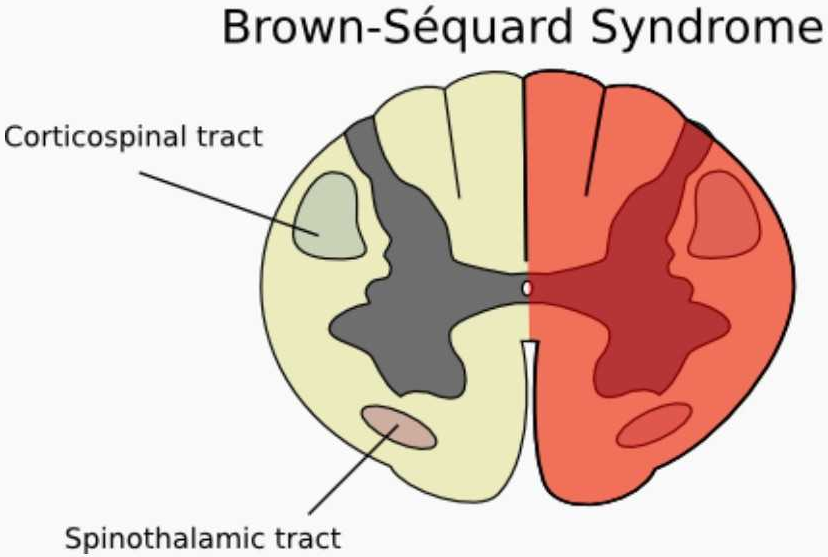

by Fpjacquot, via Wikimedia Commons

< Previous Next >

Something wrong?

FRCEM Success

We are an online revision resource for FRCEM Primary and Intermediate exam preparation.

Terms & Conditions
Get in Touch

Resources

- The Royal College of Emergency Medicine
- Irish Association for Emergency Medicine
- Advanced Trauma Life Support
- Resuscitation Council (UK)
- TeachMeAnatomy
- Trauma.org
- Radiopaedia
- Advanced Life Support Group
- Emergency Medicine Journal
- Lifeinthefastlane
- Instant Anatomy
- Patient.co.uk

FRCEMSuccess

©2014 - 2017 FRCEM Success | Website designed & hosted by Cyberfrog Design

Anatomy: Neck

Question 56 of 78

Regarding the neck muscles, which of the following statements is INCORRECT:

a The suprahyoid muscles pass in a superior direction from the hyoid bone to the skull or mandible.

b The suprahyoid muscles act to elevate the hyoid bone.

c The infrahyoid muscles act to depress the hyoid bone and the larynx.

d The suprahyoid muscles acts to elevate the mandible.

e The suprahyoid muscles play a vital role in swallowing.

< Previous | Next > | See Answer

Something wrong?

Question Navigator

1 Answered
2 Answered
3 Answered
4 Answered
5 Answered
6 Answered
7 Answered
8 Answered
9 Answered
10 Answered
11 Answered
12 Answered

Clear Exam

©2014 - 2017 FRCEM Success | Website designed & hosted by Cyberfrog Design

Anatomy: Neck

Question 56 of 78

Regarding the neck muscles, which of the following statements is INCORRECT:

a) ✖
The suprahyoid muscles pass in a superior direction from the hyoid bone to the skull or mandible.

b) The suprahyoid muscles act to elevate the hyoid bone.

c) The infrahyoid muscles act to depress the hyoid bone and the larynx.

d) The suprahyoid muscles acts to elevate the mandible. ✔

e) The suprahyoid muscles play a vital role in swallowing.

Answer

The suprahyoid muscles act to elevate the hyoid bone, as occurs in swallowing, but also assist with depression of the mandible, as occurs in opening the mouth.

Notes

Muscles superior to the hyoid are called suprahyoid muscles and include the stylohyoid, digastric, mylohyoid and geniohyoid muscles. The suprahyoid muscles pass in a superior direction from the hyoid bone to the skull or mandible and act to raise the hyoid bone, as occurs in swallowing.

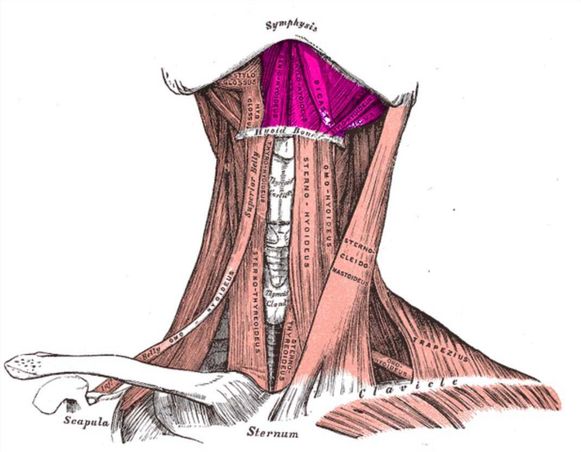

By Häggström, Mikael. "Medical gallery of Mikael Häggström 2014". Wikiversity Journal of Medicine 1 (2). DOI:10.15347/wjm/2014.008. ISSN 20018762. (Image:Gray386.png) [Public domain or Public domain], via Wikimedia Commons

Muscles inferior to the hyoid are the infrahyoid muscles and include the omohyoid, sternohyoid, thyrohyoid and sternothyroid. The infrahyoid muscles attach the hyoid bone to inferior structures and act to depress the hyoid bone and the larynx. They also provide a stable point of attachment for the suprahyoid muscles.

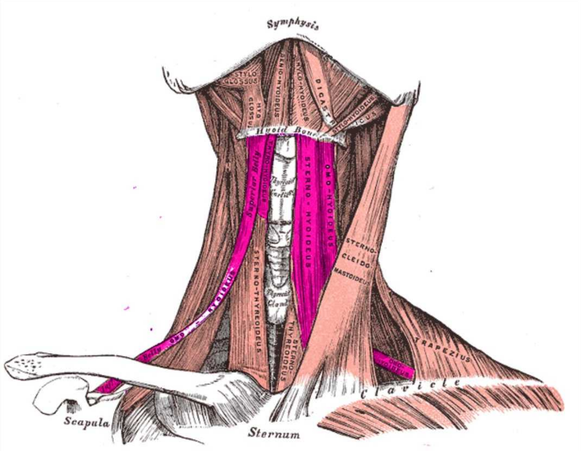

By Häggström, Mikael. "Medical gallery of Mikael Häggström 2014". Wikiversity Journal of Medicine 1 (2). DOI:10.15347/wjm/2014.008. ISSN 20018762. (Image:Gray386.png) [Public domain, Public domain or Public domain], via Wikimedia Commons

< Previous | Next > | Something wrong?

Question Navigator

1 Answered
2 Answered
3 Answered
4 Answered
5 Answered
6 Answered
7 Answered
8 Answered
9 Answered
10 Answered
11 Answered
12 Answered

Clear Exam

©2014 - 2017 FRCEM Success | Website designed & hosted by Cyberfrog Design

Anatomy: Neck

Question 57 of 78

Regarding the thyroid gland, which of the following statements is INCORRECT:

a The isthmus of the thyroid crosses the anterior surface of the second and third tracheal rings.

b The thyroid gland lies anterior to the pretracheal fascia.

c The thyroid gland lies deep to the infrahyoid muscles.

d The thyroid gland spans between the C5 and T1 vertebrae.

e The recurrent laryngeal nerves pass deep to the lateral lobes of the thyroid gland to enter the larynx.

< Previous | Next > | See Answer

Something wrong?

Question Navigator

1 Answered
2 Answered
3 Answered
4 Answered
5 Answered
6 Answered
7 Answered
8 Answered
9 Answered
10 Answered
11 Answered
12 Answered

Clear Exam

©2014 - 2017 FRCEM Success | Website designed & hosted by Cyberfrog Design

Anatomy: Neck

Question 57 of 78

Regarding the thyroid gland, which of the following statements is INCORRECT:

a)
The isthmus of the thyroid crosses the anterior surface of the second and third tracheal rings.

b) The thyroid gland lies anterior to the pretracheal fascia.

c) The thyroid gland lies deep to the infrahyoid muscles.

d) The thyroid gland spans between the C5 and T1 vertebrae.

e) The recurrent laryngeal nerves pass deep to the lateral lobes of the thyroid gland to enter the larynx.

Answer

The thyroid gland lies within the pretracheal fascia, together with the trachea and the oesophagus.

Notes

The thyroid gland is anterior in the neck, below and lateral to the thyroid cartilage, and spanning between the C5 and T1 vertebrae.

It has two lateral lobes (which cover the anterolateral surfaces of the trachea, cricoid cartilage and the lower part of the thyroid cartilage) connected by the isthmus which crosses the anterior surface of the second and third tracheal cartilages.

Relations

It lies deep to the sternohyoid, sternothyroid and omohyoid muscles, in the visceral compartment of the neck, together with and anterior to the pharynx, trachea and oesophagus, and surrounded by the pretracheal fascia.

Structures vulnerable in thyroid surgery include:

- Thyroidea ima artery
- Inferior thyroid vein
- Anterior jugular vein
- Recurrent laryngeal nerve
- Cervical dome of the pleura
- Oesophagus
- Parathyroid glands

Blood supply

The thyroid gland is supplied predominantly by the superior thyroid artery (branch of the external carotid artery) and the inferior thyroid artery (branch of the thyrocervical trunk from the subclavian artery). Occasionally a small thyroidea ima artery arises from the brachiocephalic trunk or the arch of the aorta and ascends to supply the thyroid gland.

Venous supply

The venous drainage of the thyroid is to the superior and middle thyroid veins (draining to the internal jugular vein) and the inferior thyroid veins (draining to the brachiocephalic veins).

Lymphatics

Lymphatic drainage of the thyroid gland is to nodes beside the trachea (paratracheal nodes) and to deep cervical nodes inferior to the omohyoid muscle along the internal jugular vein.

Recurrent laryngeal nerve

The thyroid gland is closely related to the recurrent laryngeal nerves. After branching from the vagus nerve and looping around the subclavian artery on the right and the arch of the aorta on the left, the recurrent laryngeal nerves ascend in the neck in a groove between the trachea and oesophagus. They pass deep to the posteromedial surface of the lateral lobes of the thyroid gland and enter the larynx by passing deep to the lower margin of the inferior constrictor of the pharynx.

The recurrent laryngeal nerve is the most commonly injured nerve during thyroid surgery. The recurrent laryngeal nerves supply sensory innervation to the laryngeal cavity below the level of the vocal folds and motor innervation to all intrinsic muscles of the larynx except for the cricothyroid muscle.

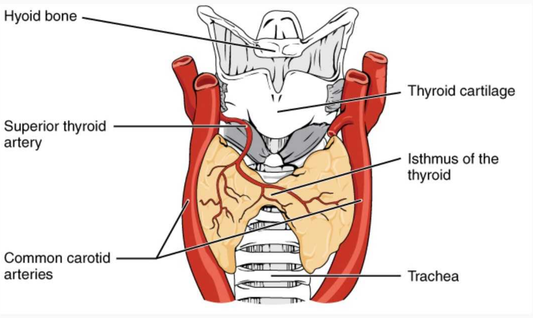

By CFCF (Own work) [CC BY-SA 3.0 (http://creativecommons.org/licenses/by-sa/3.0)], via Wikimedia Commons

< Previous | Next > | Something wrong?

Question Navigator

1 Answered
2 Answered
3 Answered
4 Answered
5 Answered
6 Answered
7 Answered
8 Answered
9 Answered
10 Answered
11 Answered
12 Answered

Clear Exam

©2014 - 2017 FRCEM Success | Website designed & hosted by Cyberfrog Design

Anatomy: Neck

Question 58 of 78

Regarding the larynx, which of the following statements is INCORRECT:

a The larynx is suspended from the hyoid bone.

b The larynx is continuous with the trachea at vertebral level C6.

c Recurrent laryngeal nerve palsy may result in a hoarse voice.

d The intrinsic laryngeal muscles are responsible for elevation and depression of the larynx to effect swallowing.

e Motor innervation to the intrinsic laryngeal muscles is provided by a branch of the vagus nerve.

< Previous | Next > | See Answer

Something wrong?

Question Navigator

1 Answered
2 Answered
3 Answered
4 Answered
5 Answered
6 Answered
7 Answered
8 Answered
9 Answered
10 Answered
11 Answered
12 Answered

Clear Exam

©2014 - 2017 FRCEM Success | Website designed & hosted by Cyberfrog Design

Anatomy: Neck

Question 58 of 78

Regarding the larynx, which of the following statements is INCORRECT:

a) **The larynx is suspended from the hyoid bone.** ✖

b) The larynx is continuous with the trachea at vertebral level C6.

c) Recurrent laryngeal nerve palsy may result in a hoarse voice.

d) ✔
The intrinsic laryngeal muscles are responsible for elevation and depression of the larynx to effect swallowing.

e) Motor innervation to the intrinsic laryngeal muscles is provided by a branch of the vagus nerve.

Answer

The intrinsic muscles alter the size and shape of the laryngeal inlet and move the vocal folds. The extrinsic muscles are involved in elevation and depression of the larynx to produce swallowing.

Notes

The larynx is suspended from the superior hyoid bone and attached to the trachea below by membranes and ligaments. It opens above into the pharynx immediately posterior and slightly inferior to the tongue and the oropharyngeal isthmus of the oral cavity, and blends inferiorly with the trachea at the vertebral level C6.

Function

There are four principal roles of the larynx:

- phonation
- sphincteric to close the lower respiratory tract (for example during swallowing)
- coughing
- breath-holding while straining (vocal cord adduction).

Laryngeal muscles

The laryngeal muscles are divided into intrinsic and extrinsic groups.

The intrinsic muscles alter the size and shape of the laryngeal inlet and move the vocal folds.

The extrinsic muscles are involved in elevation and depression of the larynx to produce swallowing.

Innervation

Motor and sensory innervation of the larynx is provided by the vagus nerve via its superior laryngeal and recurrent laryngeal branches.

The recurrent laryngeal nerves are sensory to the laryngeal cavity below the level of the vocal folds and motor to all intrinsic muscles of the larynx except for the cricothyroid muscle (innervated by the superior laryngeal branch of the vagus nerve).

A lesion of the recurrent laryngeal nerve may cause respiratory obstruction, hoarseness, inability to speak and loss of sensation below the vocal cord.

The superior laryngeal nerve supplies sensation to the mucous membrane above the vocal cord and the taste buds on the epiglottis, and motor innervation to the cricothyroid and the inferior pharyngeal constrictor muscles.

A lesion of the superior laryngeal nerve may cause loss of sensation above the vocal cord and taste on the epiglottis, and a weak hoarse voice.

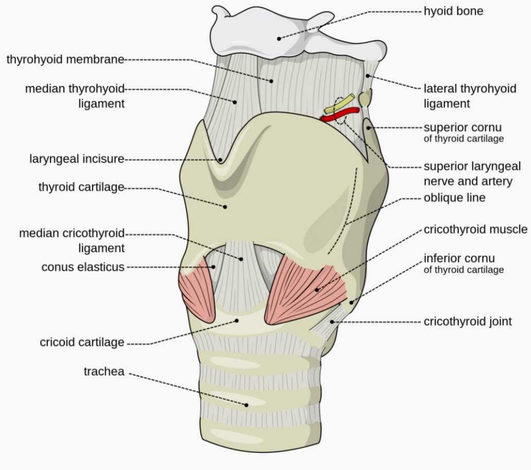

By Olek Remesz (wiki-pl: Orem, commons: Orem) [CC BY-SA 2.5-2.0-1.0], via Wikimedia Commons

< Previous | Next > | Something wrong?

Question Navigator

1 Answered
2 Answered
3 Answered
4 Answered
5 Answered
6 Answered
7 Answered
8 Answered
9 Answered
10 Answered
11 Answered
12 Answered

Clear Exam

©2014 - 2017 FRCEM Success | Website designed & hosted by Cyberfrog Design

Anatomy: Neck

Question 59 of 78

Regarding the larynx, which of the following statements is INCORRECT:

a The cricoid cartilage is the most inferior of the laryngeal cartilages.

b The thyroid cartilage is the largest of the laryngeal cartilages.

c The larynx is formed from three large unpaired cartilages and one smaller paired cartilage.

d The median cricothyroid ligament can be perforated to establish an emergency airway.

e Movement at the cricoarytenoid joints abducts or adducts the vocal ligament.

< Previous | Next > | See Answer

Something wrong?

Question Navigator

1 Answered
2 Answered
3 Answered
4 Answered
5 Answered
6 Answered
7 Answered
8 Answered
9 Answered
10 Answered
11 Answered
12 Answered

Clear Exam

©2014 - 2017 FRCEM Success | Website designed & hosted by Cyberfrog Design

Anatomy: Neck

Question 59 of 78

Regarding the larynx, which of the following statements is INCORRECT:

a) **The cricoid cartilage is the most inferior of the laryngeal cartilages.** ✗
b) The thyroid cartilage is the largest of the laryngeal cartilages.
c) The larynx is formed from three large unpaired cartilages and one smaller paired cartilage. ✓
d) The median cricothyroid ligament can be perforated to establish an emergency airway.
e) Movement at the cricoarytenoid joints abducts or adducts the vocal ligament.

Answer

The structure of the larynx is formed from three large unpaired cartilages (cricoid, thyroid, and epiglottis), three smaller paired cartilages (arytenoid, corniculate and cuneiform), joints, ligaments, a fibroelastic membrane and numerous intrinsic muscles.

Notes

The structure of the larynx is formed from three large unpaired cartilages (cricoid, thyroid, and epiglottis), three smaller paired cartilages (arytenoid, corniculate and cuneiform), joints, ligaments, a fibroelastic membrane and numerous intrinsic muscles.

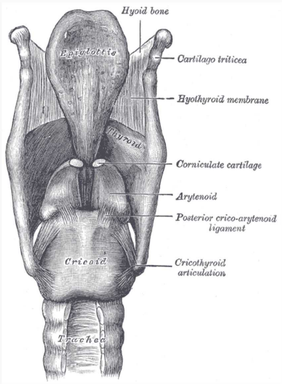

By Henry Vandyke Carter [Public domain], via Wikimedia Commons

Cartilages

The cricoid cartilage is the most inferior of the laryngeal cartilages and completely encircles the airway. The cricoid cartilage articulates with the base of the arytenoid cartilages superiorly (forming the cricoarytenoid joint) and the inferior horns of the thyroid cartilage posterolaterally (forming the cricothyroid joint).

The thyroid cartilage is the largest of the laryngeal cartilages. The thyroid cartilage articulates with the cricoid cartilage inferiorly and the hyoid bone superiorly.

The epiglottis is attached to the posterior aspect of the thyroid cartilage and projects posterosuperiorly. The upper margin of the epiglottis is behind the pharyngeal part of the tongue.

The two arytenoid cartilages articulate inferiorly with the cricoid cartilage and superiorly with the corniculate cartilages.

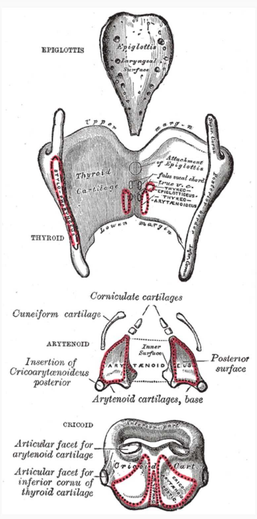

By Henry Vandyke Carter [Public domain], via Wikimedia Commons

Joints

The cricothyroid and cricoarytenoid joints are the main laryngeal joints allowing normal function.

Movements at the cricoarytenoid joints abduct and adduct the vocal ligaments.

Movements at the cricothyroid joint enable the thyroid cartilage to move forward and tilt downwards on the cricoid cartilage which effectively lengthens and puts tension on the vocal ligaments.

Cricothyroid membrane

The cricothyroid membrane (conus elasticus) is attached to the arch of the cricoid cartilage and extends superiorly to end in a free upper margin within the space enclosed by the thyroid cartilage. This upper free margin attaches on each side anteriorly to the thyroid cartilage and posteriorly to the vocal processes of the arytenoid cartilage. The free margin between these two points is thickened to form the vocal ligament which is under the vocal fold of the larynx.

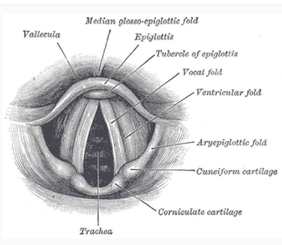

By Henry Vandyke Carter [Public domain], via Wikimedia Commons

The cricothyroid membrane is also thickened anteriorly in the midline to form the distinct median cricothyroid ligament, which spans the distance between the arch of the cricoid cartilage and the thyroid cartilage up to the attachments of the vocal ligaments. In emergency situations, when the airway is blocked above the level of the vocal folds, the median cricothyroid ligament can be perforated to establish an airway (cricothyrotomy).

< Previous | Next >

Something wrong?

Question Navigator

1 Answered
2 Answered
3 Answered
4 Answered
5 Answered
6 Answered
7 Answered
8 Answered
9 Answered
10 Answered
11 Answered
12 Answered

Clear Exam

©2014 - 2017 FRCEM Success | Website designed & hosted by Cyberfrog Design

Anatomy: Neck

Question 60 of 78

Regarding the trachea, which of the following statements is INCORRECT:

a The trachea begins at vertebral level C6.

b The trachea lies directly anterior to the oesophagus.

c The thyroidea ima artery is particularly vulnerable in tracheostomy.

d A cricothyrotomy involves making an opening in the neck inferior to the cricoid cartilage.

e A cricothyroidotomy is suitable for airway obstruction superior to the vocal folds.

< Previous | Next > | See Answer

Something wrong?

Question Navigator

1 Answered
2 Answered
3 Answered
4 Answered
5 Answered
6 Answered
7 Answered
8 Answered
9 Answered
10 Answered
11 Answered
12 Answered

Clear Exam

©2014 - 2017 FRCEM Success | Website designed & hosted by Cyberfrog Design

Anatomy: Neck

Question 60 of 78

Regarding the trachea, which of the following statements is INCORRECT:

a) **The trachea begins at vertebral level C6.** ✖
b) The trachea lies directly anterior to the oesophagus.
c) The thyroidea ima artery is particularly vulnerable in tracheostomy.
d) A cricothyrotomy involves making an opening in the neck inferior to the cricoid cartilage. ✔
e) A cricothyroidotomy is suitable for airway obstruction superior to the vocal folds.

Answer

A cricothyrotomy involves making an opening in the median cricothyroid ligament (the medial part of the cricothyroid ligament), between the cricoid and thyroid cartilages of the larynx.

Notes

The trachea begins at vertebral level C6, where it is continuous with the larynx above. The trachea lies directly anterior to the oesophagus and travels inferiorly to pass through the thoracic inlet.

Cricothyrotomy

A cricothyrotomy is performed to provide a temporary emergency airway in situations where there is obstruction at or above the level of the larynx, such that oral/nasal endotracheal intubation is impossible e.g. as a result of inhalation of a foreign body, severe oedema secondary to anaphylactic reaction, or severe head and neck trauma.

Compared with an emergency tracheostomy, it is quicker and easier to perform and associated with fewer complications. It involves making an opening in the median cricothyroid ligament (the medial part of the cricothyroid ligament), between the cricoid and thyroid cartilages of the larynx. The ligament can be palpated in the midline and usually there are only small blood vessels, connective tissue and skin overlying it.

Tracheostomy

At a lower level, the airway can be accessed surgically (or percutaneously) through the anterior wall of the trachea by tracheostomy. Tracheostomy is usually performed in non-emergency situations.

A small transverse incision is placed in the lower third of the neck anteriorly. The strap (infrahyoid) muscles are deviated laterally and the trachea can be easily visualised. Occasionally it is necessary to divide the isthmus of the thyroid. An incision is typically made between the second and third or the third and fourth tracheal rings and a small tracheostomy tube inserted.

This route of entry is complicated because large veins and part of the thyroid gland overlie this region. Structures particularly vulnerable include the isthmus of the thyroid, the jugular arch connecting the anterior jugular veins, the inferior thyroid vein, the left brachiocephalic vein, the thyroidea ima artery, and the recurrent laryngeal nerve (less commonly).

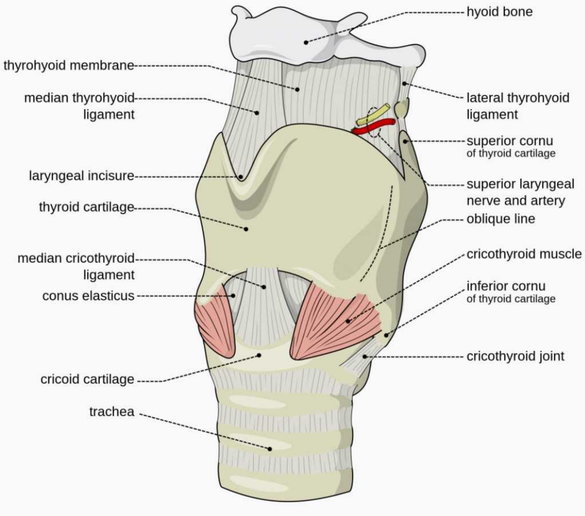

By Olek Remesz (wiki-pl: Orem, commons: Orem) [CC BY-SA 2.5-2.0-1.0], via Wikimedia Commons

< Previous | Next >

Something wrong?

Question Navigator

1 Answered
2 Answered
3 Answered
4 Answered
5 Answered
6 Answered
7 Answered
8 Answered
9 Answered
10 Answered
11 Answered
12 Answered

Clear Exam

©2014 - 2017 FRCEM Success | Website designed & hosted by Cyberfrog Design

Anatomy: Neck

Question 61 of 78

Regarding the vertebral canal, which of the following statements is CORRECT:

a The vertebral canal is bounded posteriorly by the vertebral bodies.

b Superiorly the vertebral canal is continuous with the jugular foramen.

c The spinal cord is surrounded by two layers of meninges.

d The subarachnoid space is found between the arachnoid and the dura mater.

e The conus medullaris is the point below which the canal contains only the cauda equina and filum terminale.

< Previous | Next > | See Answer

Something wrong?

Question Navigator

1 Answered
2 Answered
3 Answered
4 Answered
5 Answered
6 Answered
7 Answered
8 Answered
9 Answered
10 Answered
11 Answered
12 Answered

Clear Exam

©2014 - 2017 FRCEM Success | Website designed & hosted by Cyberfrog Design

Anatomy: Neck

Question 61 of 78

Regarding the vertebral canal, which of the following statements is CORRECT:

a) **The vertebral canal is bounded posteriorly by the vertebral bodies.** ✖

b) Superiorly the vertebral canal is continuous with the jugular foramen.

c) The spinal cord is surrounded by two layers of meninges.

d) The subarachnoid space is found between the arachnoid and the dura mater.

e) ✔

The conus medullaris is the point below which the canal contains only the cauda equina and filum terminale.

Answer

The conus medullaris is the point below which the canal contains only the cauda equina and filum terminale.

Notes

The vertebral canal extends from the first cervical vertebra (C1) to the last sacral vertebra (S5). Superiorly the vertebral canal is continuous, through the foramen magnum of the skull, with the cranial cavity.

The vertebral canal is bounded anteriorly by the vertebral bodies, intervertebral discs and the posterior longitudinal ligament, laterally by the vertebral pedicles and posteriorly by the vertebral laminae.

The vertebral canal contains the spinal cord and its protective membranes, together with blood vessels, connective tissue, fat and spinal nerve roots. The conus medullaris is the point below which the canal contains only the cauda equina and filum terminale.

Meninges

The spinal cord is surrounded by a series of three spinal meninges consisting of a dura, arachnoid and pia mater.

The bony walls of the spinal canal are separated from the meninges by the epidural (extradural) space.

The subarachnoid space, containing CSF, is found between the arachnoid and pia mater. The subarachnoid space around the spinal cord is continuous at the foramen magnum with the subarachnoid space surrounding the brain.

Lumbar puncture

In adults, the spinal cord typically ends between L1/L2 whereas the subarachnoid space extends to approximately the lower border of vertebra S2. As a result of this, CSF can be withdrawn from the subarachnoid space in the lower lumbar region without endangering the spinal cord.

When performing a lumbar puncture, the needle passes between adjacent vertebral spinous processes, through the supraspinous and interspinous ligaments and through the ligamentum flavum to enter the extradural space. The needle then continues through the dura and the arachnoid mater to enter the subarachnoid space.

Layers penetrated during lumbar puncture:

- Skin
- Superficial fascia
- Supraspinous ligament
- Interspinous ligament
- Ligamentum flavum (first 'give')
- Extradural space
- Dura mater (second 'give')
- Subdural space
- Arachnoid mater
- Subarachnoid space (containing CSF)

< Previous | Next >

Something wrong?

Question Navigator

1 Answered
2 Answered
3 Answered
4 Answered
5 Answered
6 Answered
7 Answered
8 Answered
9 Answered
10 Answered
11 Answered
12 Answered

Clear Exam

©2014 - 2017 FRCEM Success | Website designed & hosted by Cyberfrog Design

Anatomy: Neck

Question 62 of 78

The sensory innervation of the oropharynx is provided by which of the following nerves:

a Glossopharyngeal nerve

b Maxillary nerve

c Mandibular nerve

d Facial nerve

e Vagus nerve

< Previous | Next > | See Answer

Something wrong?

Question Navigator

1 Answered
2 Answered
3 Answered
4 Answered
5 Answered
6 Answered
7 Answered
8 Answered
9 Answered
10 Answered
11 Answered
12 Answered

Clear Exam

©2014 - 2017 FRCEM Success | Website designed & hosted by Cyberfrog Design

Anatomy: Neck

Question 62 of 78

The sensory innervation of the oropharynx is provided by which of the following nerves:

a) **Glossopharyngeal nerve** ✔
b) Maxillary nerve
c) Mandibular nerve
d) Facial nerve
e) Vagus nerve

Answer

Each subdivision of the pharynx has a different sensory innervation:

- the nasopharynx is innervated by the maxillary nerve
- the oropharynx is innervated by the glossopharyngeal nerve
- the laryngopharynx is innervated by the vagus nerve.

Notes

The pharynx is a musculofascial structure that connects the oral and nasal cavities in the head to the larynx and the oesophagus in the neck.

The pharynx is attached above to the base of the skull, and is continuous below, approximately at the level of vertebra C6, with the top of the oesophagus.

The pharynx is separated from the posterior vertebral column by a thin retropharyngeal space, bordered anteriorly by the buccopharyngeal fascia and posteriorly by the prevertebral fascia.

Arrangement

The walls of the pharynx are attached anteriorly to the margins of the nasal cavities, oral cavity and larynx, dividing the pharynx into the continuous nasopharynx, oropharynx and laryngopharynx respectively.

The posterior apertures of the nasal cavities open into the nasopharynx, the oropharyngeal isthmus opens into the oropharynx and the superior aperture of the larynx opens into the laryngopharynx.

The pharyngotympanic tubes (from the middle ear) open into the lateral walls of the nasopharynx.

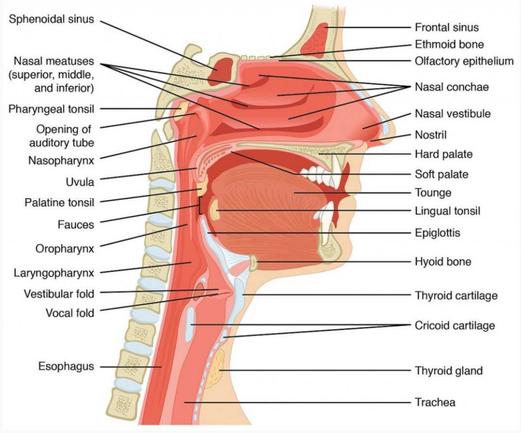

By OpenStax College [CC BY 3.0], via Wikimedia Commons

Muscles

The muscles of the pharyngeal wall are organised into two groups.

The three sheet-like constrictor muscles constrict the pharyngeal cavity sequentially to move a bolus of food through the pharynx and into the oesophagus during swallowing.

The three longitudinal muscles elevate the pharyngeal wall, or during swallowing, pull the pharyngeal wall up and over a bolus of food being moved through the pharynx into the oesophagus.

Nerve supply

The muscles of the pharynx are all innervated by the vagus nerve except for the stylopharyngeus muscle, innervated by the glossopharyngeal nerve. The branches of the vagus and glossopharyngeal nerves form a pharyngeal plexus in the outer fascia of the pharyngeal wall.

Each subdivision of the pharynx has a different sensory innervation:

- the nasopharynx is innervated by the maxillary nerve
- the oropharynx is innervated by the glossopharyngeal nerve
- the laryngopharynx is innervated by the vagus nerve.

Lymphatics

Lymphatic vessels from the pharynx drain into the deep cervical lymph nodes.

< Previous | Next >

Something wrong?

Question Navigator

1 Answered
2 Answered
3 Answered
4 Answered
5 Answered
6 Answered
7 Answered
8 Answered
9 Answered
10 Answered
11 Answered
12 Answered

Clear Exam

©2014 - 2017 FRCEM Success | Website designed & hosted by Cyberfrog Design

Anatomy: Neck

Question 63 of 78

Regarding the intervertebral disc, which of the following statements is CORRECT:

a Herniation of the intervertebral disc usually occurs in an anterior direction.

b The intervertebral disc consists of an outer layer called the fibrous pulposus.

c In L4 – L5 disc herniation, the L5 spinal nerve root is the most commonly affected.

d Disc herniation most commonly occurs in the thoracic region.

e Herniation of the intervertebral disc occurs when the outer fibrous layer herniates through vertebral bodies.

< Previous | Next > | See Answer

Something wrong?

Question Navigator

1 Answered
2 Answered
3 Answered
4 Answered
5 Answered
6 Answered
7 Answered
8 Answered
9 Answered
10 Answered
11 Answered
12 Answered

Clear Exam

©2014 - 2017 FRCEM Success | Website designed & hosted by Cyberfrog Design

Anatomy: Neck

Question 63 of 78

Regarding the intervertebral disc, which of the following statements is CORRECT:

a) **Herniation of the intervertebral disc usually occurs in an anterior direction.** ✘

b) The intervertebral disc consists of an outer layer called the fibrous pulposus.

c) In L4 – L5 disc herniation, the L5 spinal nerve root is the most commonly affected. ✔

d) Disc herniation most commonly occurs in the thoracic region.

e)

Herniation of the intervertebral disc occurs when the outer fibrous layer herniates through vertebral bodies.

Answer

A posterolateral herniation of the disc at the L4 – L5 level would be most likely to damage the fifth lumbar nerve root, not the fourth lumbar nerve root, due to more oblique descending of the fifth lumbar nerve root within the subarachnoid space.

Notes

Each vertebral body is separated from adjacent vertebral bodies by fibrocartilaginous intervertebral discs.

The intervertebral disc consists of the outer annulus fibrosus, a complex series of fibrous rings enclosing the central gelatinous nucleus pulposus.

The intervertebral discs allows movements between the vertebrae and act as a shock absorber.

Degenerative changes in the annulus fibrosus can lead to herniation of the nucleus pulposus. A tear can occur within the annulus fibrosus through which the nucleus pulposus can track into the intervertebral foramen or into the vertebral canal, compressing the spinal nerve root. It commonly occurs posterolaterally where the annulus fibrosis is not reinforced by the posterior longitudinal ligament, and frequently affects the lumbar region.

The spinal cord only occupies about 2/3s of the space available to it in the vertebral canal. The lower a nerve root, the more steeply it slopes down and the further it has to travel before gaining its intervertebral foramen. Therefore, a posterolateral herniation of the disc at the L4 – L5 level for example, would be most likely to damage the fifth lumbar nerve root, not the fourth lumbar nerve root, due to more oblique descending of the fifth lumbar nerve root within the subarachnoid space.

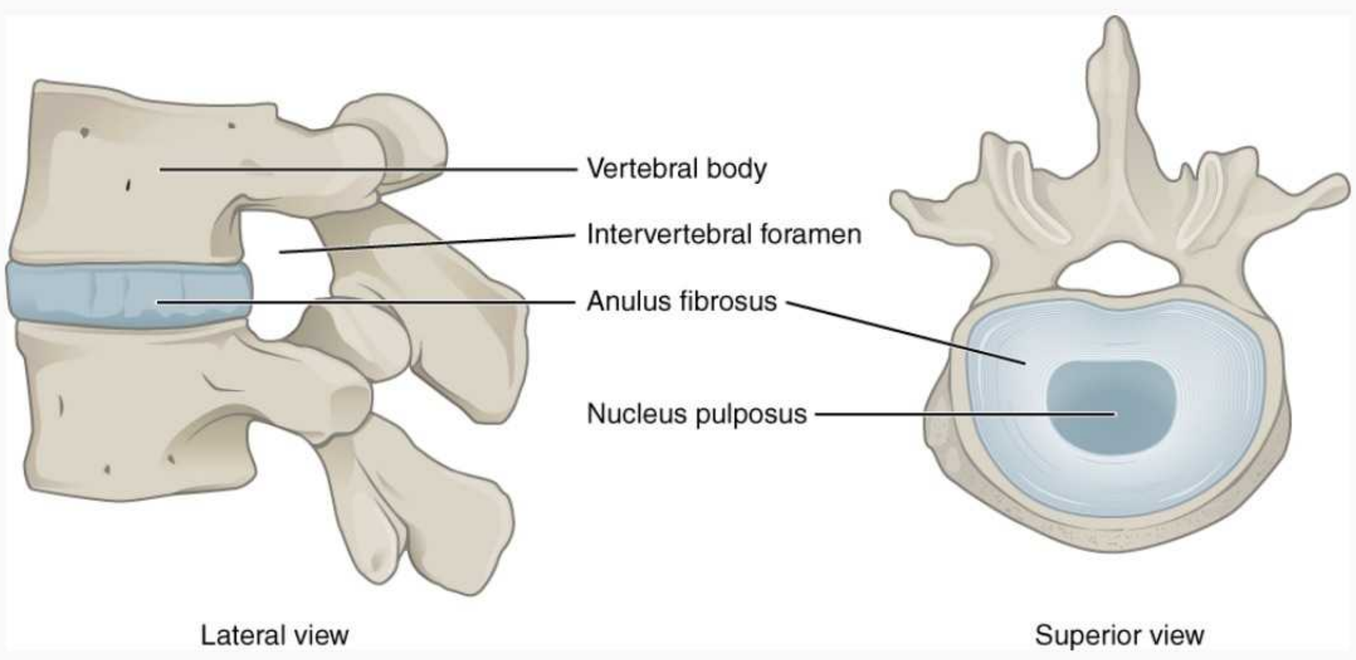

By OpenStax College [CC BY 3.0], via Wikimedia Commons

< Previous | Next >

Something wrong?

Question Navigator

1 Answered
2 Answered
3 Answered
4 Answered
5 Answered
6 Answered
7 Answered
8 Answered
9 Answered
10 Answered
11 Answered
12 Answered

Clear Exam

©2014 - 2017 FRCEM Success | Website designed & hosted by Cyberfrog Design

Anatomy: Neck

Question 64 of 78

A 21 year old student is sent in to ED by his GP with suspected meningitis. You are about to perform a lumbar puncture. Which of the following structures is normally penetrated in lumbar puncture:

a Filum terminale

b Pia mater

c Ligamentum flavum

d Posterior longitudinal ligament

e Anterior longitudinal ligament

< Previous | Next > | See Answer

Something wrong?

Question Navigator

1 Answered
2 Answered
3 Answered
4 Answered
5 Answered
6 Answered
7 Answered
8 Answered
9 Answered
10 Answered
11 Answered
12 Answered

Clear Exam

©2014 - 2017 FRCEM Success | Website designed & hosted by Cyberfrog Design

Anatomy: Neck

Question 64 of 78

A 21 year old student is sent in to ED by his GP with suspected meningitis. You are about to perform a lumbar puncture. Which of the following structures is normally penetrated in lumbar puncture:

a) **Filum terminale** ✗
b) Pia mater
c) Ligamentum flavum ✓
d) Posterior longitudinal ligament
e) Anterior longitudinal ligament

Answer

The cerebrospinal fluid (CSF) is located in the subarachnoid space, between the arachnoid layer and the pia mater. In a lumbar puncture, the needle penetrates the skin, fascia, supraspinous ligament, interspinous ligament, ligamentum flavum, epidural space, dura mater, subdural space, and arachnoid mater.

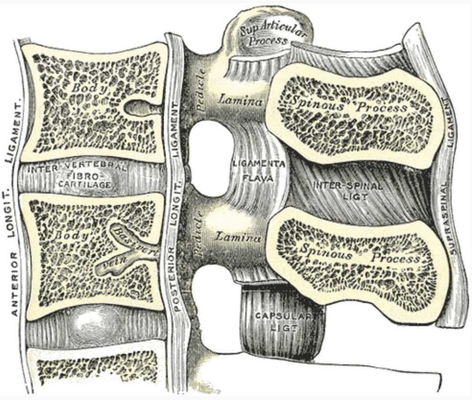

By Henry Vandyke Carter [Public domain], via Wikimedia Commons

Notes

The vertebral canal extends from the first cervical vertebra (C1) to the last sacral vertebra (S5). Superiorly the vertebral canal is continuous, through the foramen magnum of the skull, with the cranial cavity.

The vertebral canal is bounded anteriorly by the vertebral bodies, intervertebral discs and the posterior longitudinal ligament, laterally by the vertebral pedicles and posteriorly by the vertebral laminae.

The vertebral canal contains the spinal cord and its protective membranes, together with blood vessels, connective tissue, fat and spinal nerve roots. The conus medullaris is the point below which the canal contains only the cauda equina and filum terminale.

Meninges

The spinal cord is surrounded by a series of three spinal meninges consisting of a dura, arachnoid and pia mater.

The bony walls of the spinal canal are separated from the meninges by the epidural (extradural) space.

The subarachnoid space, containing CSF, is found between the arachnoid and pia mater. The subarachnoid space around the spinal cord is continuous at the foramen magnum with the subarachnoid space surrounding the brain.

Lumbar puncture

In adults, the spinal cord typically ends between L1/L2 whereas the subarachnoid space extends to approximately the lower border of vertebra S2. As a result of this, CSF can be withdrawn from the subarachnoid space in the lower lumbar region without endangering the spinal cord.

When performing a lumbar puncture, the needle passes between adjacent vertebral spinous processes, through the supraspinous and interspinous ligaments and through the ligamentum flavum to enter the extradural space. The needle then continues through the dura and the arachnoid mater to enter the subarachnoid space.

Layers penetrated during lumbar puncture:

- Skin
- Superficial fascia
- Supraspinous ligament
- Interspinous ligament
- Ligamentum flavum (first 'give')
- Extradural space
- Dura mater (second 'give')
- Subdural space
- Arachnoid mater
- Subarachnoid space (containing CSF)

< Previous | Next >

Something wrong?

Question Navigator

1 Answered
2 Answered
3 Answered
4 Answered
5 Answered
6 Answered
7 Answered
8 Answered
9 Answered
10 Answered
11 Answered
12 Answered

Clear Exam

©2014 - 2017 FRCEM Success | Website designed & hosted by Cyberfrog Design

Anatomy: Neck

Question 65 of 78

Regarding the thyroid gland, which of the following statements is CORRECT:

a The thyroid gland lies directly anterior to the thyroid cartilage.

b The thyroid gland spans between the C3 – C5 vertebrae.

c The thyroid gland receives its blood supply predominantly from branches of the internal carotid artery.

d The recurrent laryngeal nerves pass deep to the posteromedial surface of the lateral lobes.

e The lymphatics of the thyroid gland drain primarily to submental lymph nodes.

< Previous | Next > | See Answer

Something wrong?

Question Navigator

1 Answered
2 Answered
3 Answered
4 Answered
5 Answered
6 Answered
7 Answered
8 Answered
9 Answered
10 Answered
11 Answered
12 Answered

Clear Exam

©2014 - 2017 FRCEM Success | Website designed & hosted by Cyberfrog Design

Anatomy: Neck

Question 65 of 78

Regarding the thyroid gland, which of the following statements is CORRECT:

a) **The thyroid gland lies directly anterior to the thyroid cartilage.** ✖

b) The thyroid gland spans between the C3 – C5 vertebrae.

c)
The thyroid gland receives its blood supply predominantly from branches of the internal carotid artery.

d) The recurrent laryngeal nerves pass deep to the posteromedial surface of the lateral lobes. ✔

e) The lymphatics of the thyroid gland drain primarily to submental lymph nodes.

Answer

The thyroid gland is closely related to the recurrent laryngeal nerves. After branching from the vagus nerve and looping around the subclavian artery on the right and the arch of the aorta on the left, the recurrent laryngeal nerves ascend in the neck in a groove between the trachea and oesophagus. They pass deep to the posteromedial surface of the lateral lobes of the thyroid gland and enter the larynx by passing deep to the lower margin of the inferior constrictor of the pharynx.

Notes

The thyroid gland is anterior in the neck, below and lateral to the thyroid cartilage, and spanning between the C5 and T1 vertebrae.

It has two lateral lobes (which cover the anterolateral surfaces of the trachea, cricoid cartilage and the lower part of the thyroid cartilage) connected by the isthmus which crosses the anterior surface of the second and third tracheal cartilages.

Relations

It lies deep to the sternohyoid, sternothyroid and omohyoid muscles, in the visceral compartment of the neck, together with and anterior to the pharynx, trachea and oesophagus, and surrounded by the pretracheal fascia.

Structures vulnerable in thyroid surgery include:

- Thyroidea ima artery
- Inferior thyroid vein
- Anterior jugular vein
- Recurrent laryngeal nerve
- Cervical dome of the pleura
- Oesophagus
- Parathyroid glands

Blood supply

The thyroid gland is supplied predominantly by the superior thyroid artery (branch of the external carotid artery) and the inferior thyroid artery (branch of the thyrocervical trunk from the subclavian artery). Occasionally a small thyroidea ima artery arises from the brachiocephalic trunk or the arch of the aorta and ascends to supply the thyroid gland.

Venous supply

The venous drainage of the thyroid is to the superior and middle thyroid veins (draining to the internal jugular vein) and the inferior thyroid veins (draining to the brachiocephalic veins).

Lymphatics

Lymphatic drainage of the thyroid gland is to nodes beside the trachea (paratracheal nodes) and to deep cervical nodes inferior to the omohyoid muscle along the internal jugular vein.

Recurrent laryngeal nerve

The thyroid gland is closely related to the recurrent laryngeal nerves. After branching from the vagus nerve and looping around the subclavian artery on the right and the arch of the aorta on the left, the recurrent laryngeal nerves ascend in the neck in a groove between the trachea and oesophagus. They pass deep to the posteromedial surface of the lateral lobes of the thyroid gland and enter the larynx by passing deep to the lower margin of the inferior constrictor of the pharynx.

The recurrent laryngeal nerve is the most commonly injured nerve during thyroid surgery. The recurrent laryngeal nerves supply sensory innervation to the laryngeal cavity below the level of the vocal folds and motor innervation to all intrinsic muscles of the larynx except for the cricothyroid muscle.

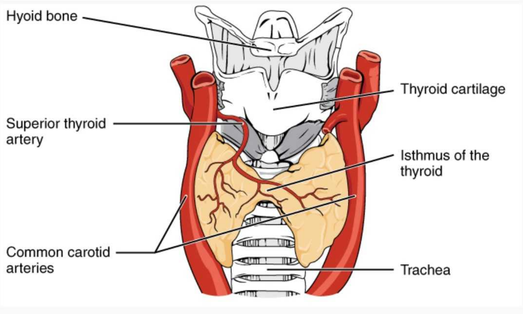

By CFCF (Own work) [CC BY-SA 3.0 (http://creativecommons.org/licenses/by-sa/3.0)], via Wikimedia Commons

< Previous | Next > | Something wrong?

Question Navigator

1 Answered
2 Answered
3 Answered
4 Answered
5 Answered
6 Answered
7 Answered
8 Answered
9 Answered
10 Answered
11 Answered
12 Answered

Clear Exam

©2014 - 2017 FRCEM Success | Website designed & hosted by Cyberfrog Design

Anatomy: Neck

Question 66 of 78

Regarding the cervical vertebrae, which of the following statements is INCORRECT:

a The atlas articulates with the articular processes of the axis inferiorly.

b The axis is characterised by the dens.

c The dens is held in position by the transverse ligament of atlas.

d The atlanto-occipital joints allow the head to rotate from side to side.

e The atlas is the first cervical vertebra.

< Previous | Next > | See Answer

Something wrong?

Question Navigator

1 Answered
2 Answered
3 Answered
4 Answered
5 Answered
6 Answered
7 Answered
8 Answered
9 Answered
10 Answered
11 Answered
12 Answered

Clear Exam

©2014 - 2017 FRCEM Success | Website designed & hosted by Cyberfrog Design

Anatomy: Neck

Question 66 of 78

Regarding the cervical vertebrae, which of the following statements is INCORRECT:

a) **The atlas articulates with the articular processes of the axis inferiorly.** ✖
b) The axis is characterised by the dens.
c) The dens is held in position by the transverse ligament of atlas.
d) The atlanto-occipital joints allow the head to rotate from side to side. ✔
e) The atlas is the first cervical vertebra.

Answer

The atlanto-occipital joints allow the head to nod up and down on the vertebral column. The atlanto-axial joints allow the head to rotate from side to side.

Notes

Vertebra C1 (the atlas) is distinguished by its lack of vertebral body, essentially being composed of two lateral masses interconnected by an anterior and posterior arch. Each lateral mass articulates above with an occipital condyle of the skull and below with the superior articular facet of vertebra C2 (the axis). The posterior surface of the anterior arch has an articular facet for the dens of the axis.

The axis is characterised by the large dens, which extends superiorly from its vertebral body to articulate with the anterior arch of the atlas, and by its bifid spinous process. The dens is held in position by the strong transverse ligament of atlas posterior to it and spanning the distance between the lateral masses of the atlas.

The atlanto-occipital joints allow the head to nod up and down on the vertebral column.

The atlanto-axial joints allow the head to rotate from side to side.

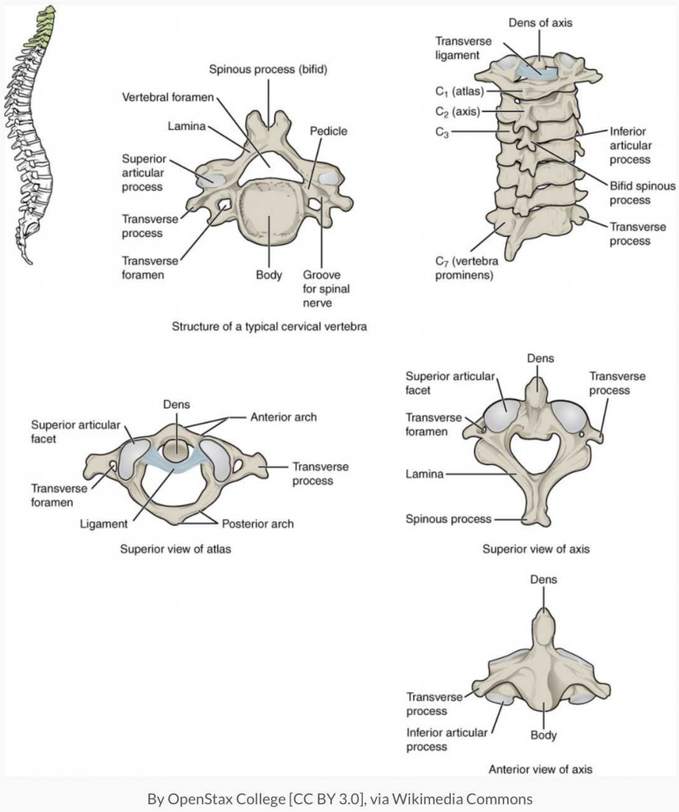

By OpenStax College [CC BY 3.0], via Wikimedia Commons

< Previous | Next >

Something wrong?

Question Navigator

1 Answered
2 Answered
3 Answered
4 Answered
5 Answered
6 Answered
7 Answered
8 Answered
9 Answered
10 Answered
11 Answered
12 Answered

Clear Exam

©2014 - 2017 FRCEM Success | Website designed & hosted by Cyberfrog Design

Anatomy: Neck

Question 67 of 78

At birth, the conus medullaris of the spinal cord lies at which of the following vertebral levels:

a L1

b L2

c L3

d L4

e L5

< Previous | Next > | See Answer

Something wrong?

Question Navigator

1 Answered
2 Answered
3 Answered
4 Answered
5 Answered
6 Answered
7 Answered
8 Answered
9 Answered
10 Answered
11 Answered
12 Answered

Clear Exam

©2014 - 2017 FRCEM Success | Website designed & hosted by Cyberfrog Design

Anatomy: Neck

Question 67 of 78

At birth, the conus medullaris of the spinal cord lies at which of the following vertebral levels:

a) L1 ✗
b) L2
c) L3 ✓
d) L4
e) L5

Answer

At birth, the conus medullaris lies at L3. By the age of 21, it sits at L1/L2.

Notes

Spinal cord extent

The spinal cord arises cranially as a continuation of the medulla oblongata at the foramen magnum. It then travels inferiorly within the vertebral canal, surrounded by the spinal meninges, before terminating as the conus medullaris. The filum terminale is an extension of pia mater that extends from the conus medullaris to the dural sac, and from the dural sac to the coccyx.

At birth, the conus medullaris lies at L3. By the age of 21, it sits at L1/L2, thus the spinal cord only occupies about 2/3s of the space available to it in the vertebral canal. The lower a nerve root, therefore, the more steeply it slopes down and the further it has to travel before gaining its intervertebral foramen. The lumbosacral nerve roots that arise from the end of the spinal cord and descend through the subarachnoid space to exit through their respective intervertebral or sacral foramina are bundled together forming the cauda equina.

Spinal cord enlargements

During the course of the spinal cord, there are two points of enlargement:

- The cervical enlargement is located at the C3 – T1 level and represents the origin of the brachial plexus.
- The lumbar enlargement is located at the T9 – L1 level and represents the origin of the lumbar and sacral plexuses.

Spinal nerve roots

The spinal nerves are formed by the union of posterior and anterior roots.

Spinal rootlets emerge from the spinal cord in the subarachnoid space and amalgamate shortly afterwards into roots. Anterior roots (containing motor nerve fibres) and posterior roots (containing the processes of sensory neurons) then emerge from their individual intervertebral foramina.

After invaginating the dura, the roots combine into mixed spinal nerves which divide into a posterior ramus (innervating intrinsic back muscles and an associated strip of skin on the back) and an anterior ramus (innervating the remaining muscles and skin of the trunk and limbs and the visceral organs).

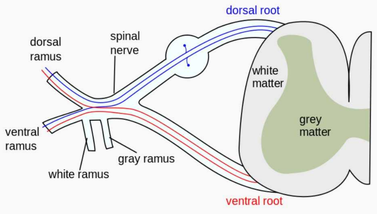

By Mysid (original by Tristanb) [GFDL (http://www.gnu.org/copyleft/fdl.html) or CC-BY-SA-3.0 (http://creativecommons.org/licenses/by-sa/3.0/)], via Wikimedia Commons

Internal anatomy

Internally the spinal cord has a small central canal (containing CSF) surrounded by grey and white matter. The central grey matter is rich in nerve cell bodies which are divided into three divisions (the anterior, posterior and lateral horns), which in cross-section form the characteristic H-shaped appearance in the central regions of the cord. The peripheral white matter surrounds the grey matter and is rich in myelinated nerve cell processes, which form large bundles or tracts that ascend and descend in the cord to other spinal cord levels or the brain. The white matter is divided bilaterally by sulci into three major divisions (the anterior, posterior and lateral columns).

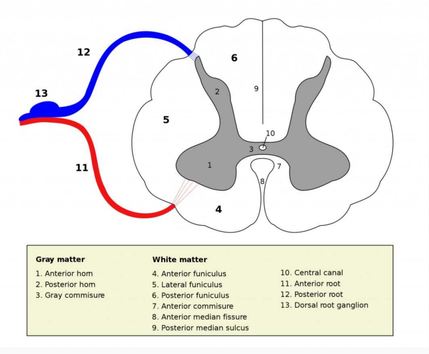

By User:Polarlys (Own work) [GFDL (http://www.gnu.org/copyleft/fdl.html), CC-BY-SA-3.0 (http://creativecommons.org/licenses/by-sa/3.0/) or CC BY 2.5 (http://creativecommons.org/licenses/by/2.5)], via Wikimedia Commons

Spinal cord blood supply

The spinal cord is supplied primarily by branches of the vertebral artery:

- The single anterior spinal artery is formed from the left and right vertebral arteries and supplies the anterior two-thirds of the spinal cord, including the anterior and lateral horns and the anterior and lateral columns.
- The paired posterior spinal arteries arise from either the posterior inferior cerebellar artery or directly from the vertebral artery and supply the posterior third of the spinal cord including the posterior horns and columns.

< Previous | Next >

Something wrong?

Question Navigator

1 Answered
2 Answered
3 Answered
4 Answered
5 Answered
6 Answered
7 Answered
8 Answered
9 Answered
10 Answered
11 Answered
12 Answered

Clear Exam

©2014 - 2017 FRCEM Success | Website designed & hosted by Cyberfrog Design

Anatomy: Neck

Question 68 of 78

Which of the following spinal tracts conveys nociceptive input from the contralateral side of the body:

a Lateral spinothalamic tract

b Posterior column

c Posterior spinocerebellar tract

d Posterior corticospinal tract

e Lateral corticospinal tract

< Previous | Next > | See Answer

Something wrong?

Question Navigator

1 Answered
2 Answered
3 Answered
4 Answered
5 Answered
6 Answered
7 Answered
8 Answered
9 Answered
10 Answered
11 Answered
12 Answered

Clear Exam

©2014 - 2017 FRCEM Success | Website designed & hosted by Cyberfrog Design

Anatomy: Neck

Question 68 of 78

Which of the following spinal tracts conveys nociceptive input from the contralateral side of the body:

a) **Lateral spinothalamic tract** ✔
b) Posterior column
c) Posterior spinocerebellar tract
d) Posterior corticospinal tract
e) Lateral corticospinal tract

Answer

The lateral spinothalamic tract transmits pain and temperature sensation from the contralateral side of the body.

Notes

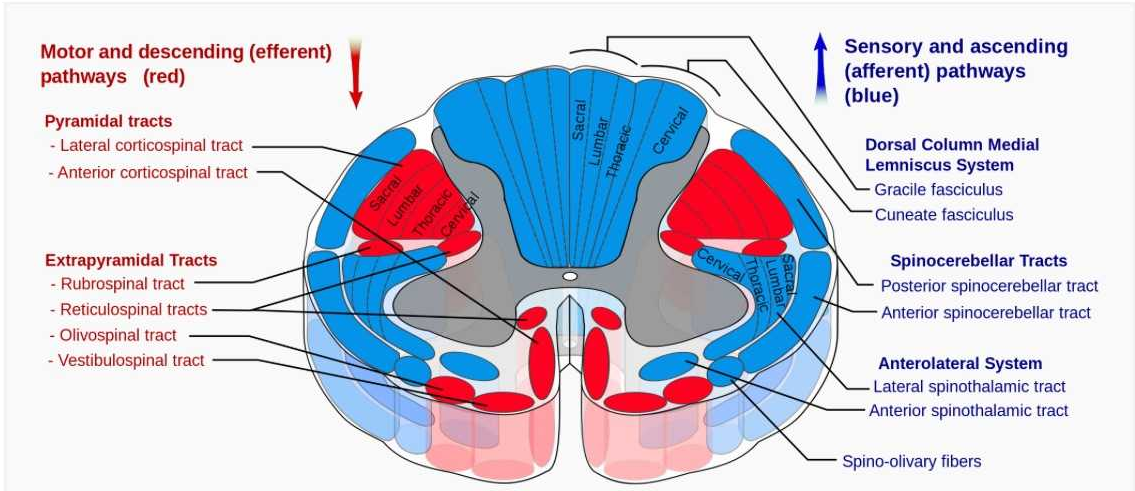

By Polarlys and Mikael Häggström [CC BY-SA 3.0 (http://creativecommons.org/licenses/by-sa/3.0) or GFDL (http://www.gnu.org/copyleft/fdl.html)], via Wikimedia Commons

Ascending tracts

The ascending spinal cord tracts represent functional pathways that convey sensory information from the periphery to higher levels.

Tract	Location	Function
Posterior column-medial lemniscus pathway (fasciculus gracilis and fasciculus cuneatus)	Posterior column	Transmits proprioception, vibration and fine-touch sensation
Anterior spinothalamic tract (decussates in spinal cord)	Anterior column	Transmits crude touch and pressure sensation
Lateral spinothalamic tract (decussates in spinal cord)	Lateral column (anterior aspect)	Transmits pain and temperature sensation

Question Navigator

1 Answered
2 Answered
3 Answered
4 Answered
5 Answered
6 Answered
7 Answered
8 Answered
9 Answered
10 Answered
11 Answered
12 Answered

Clear Exam

Posterior spinocerebellar tract	Lateral column (posterior aspect)	Transmits unconscious proprioceptive information to the cerebellum, involved in fine coordination of posture and movement of individual muscles of lower limb
Anterior spinocerebellar tract	Lateral column (anterior aspect)	Transmits unconscious proprioceptive information to the cerebellum, involved with coordination movement and posture of the entire lower limb

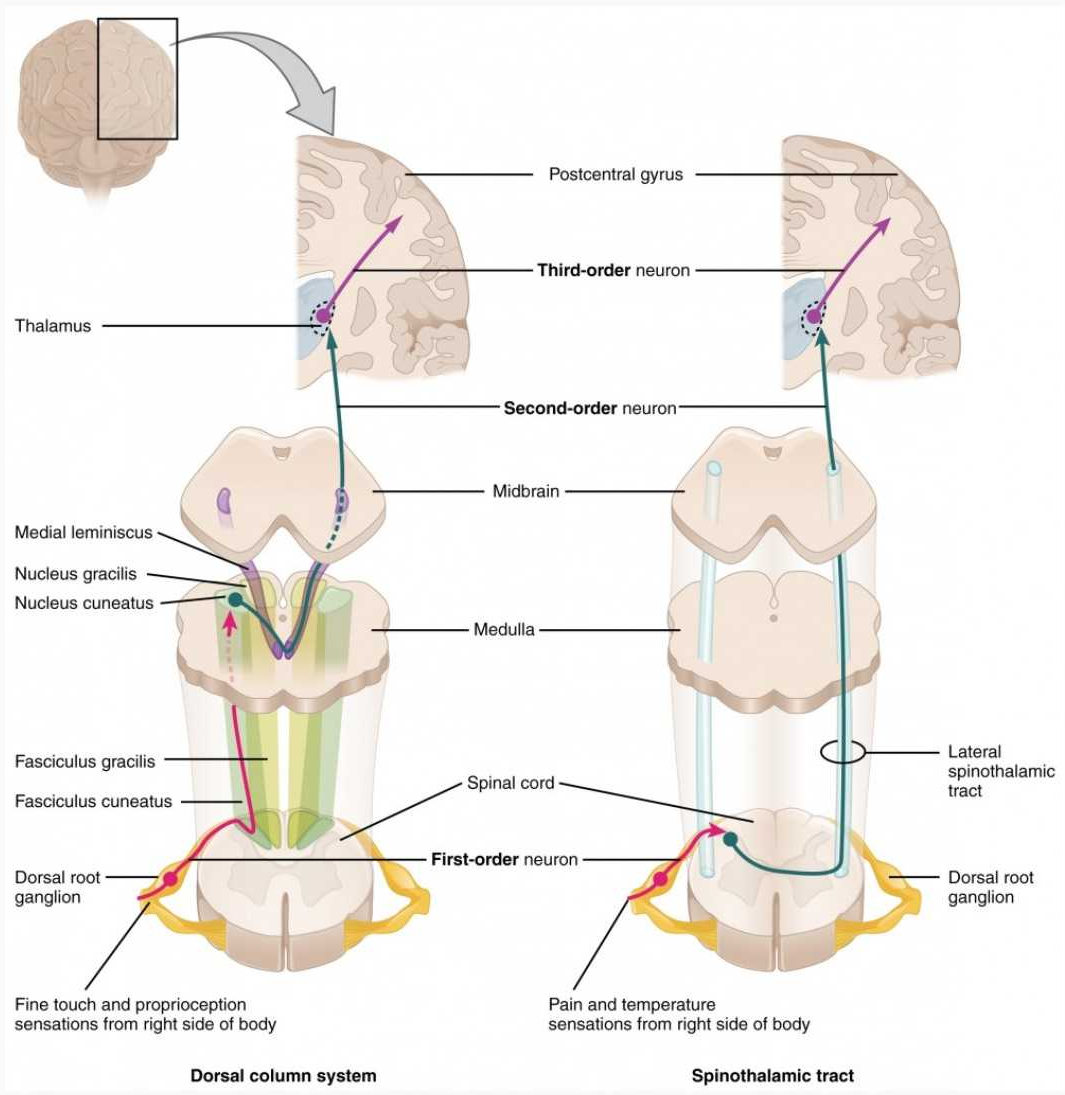

By OpenStax College [CC BY 3.0 (http://creativecommons.org/licenses/by/3.0)], via Wikimedia Commons

Descending tracts

The descending tracts are functional pathways concerned with somatic and visceral motor activities.

Tract	Location	Function
Lateral corticospinal tract	Lateral column (posterior aspect)	Involved in voluntary skilled motor activity of limbs
Anterior corticospinal tract (decussates in spinal cord)	Anterior column	Involved with control of axial muscles

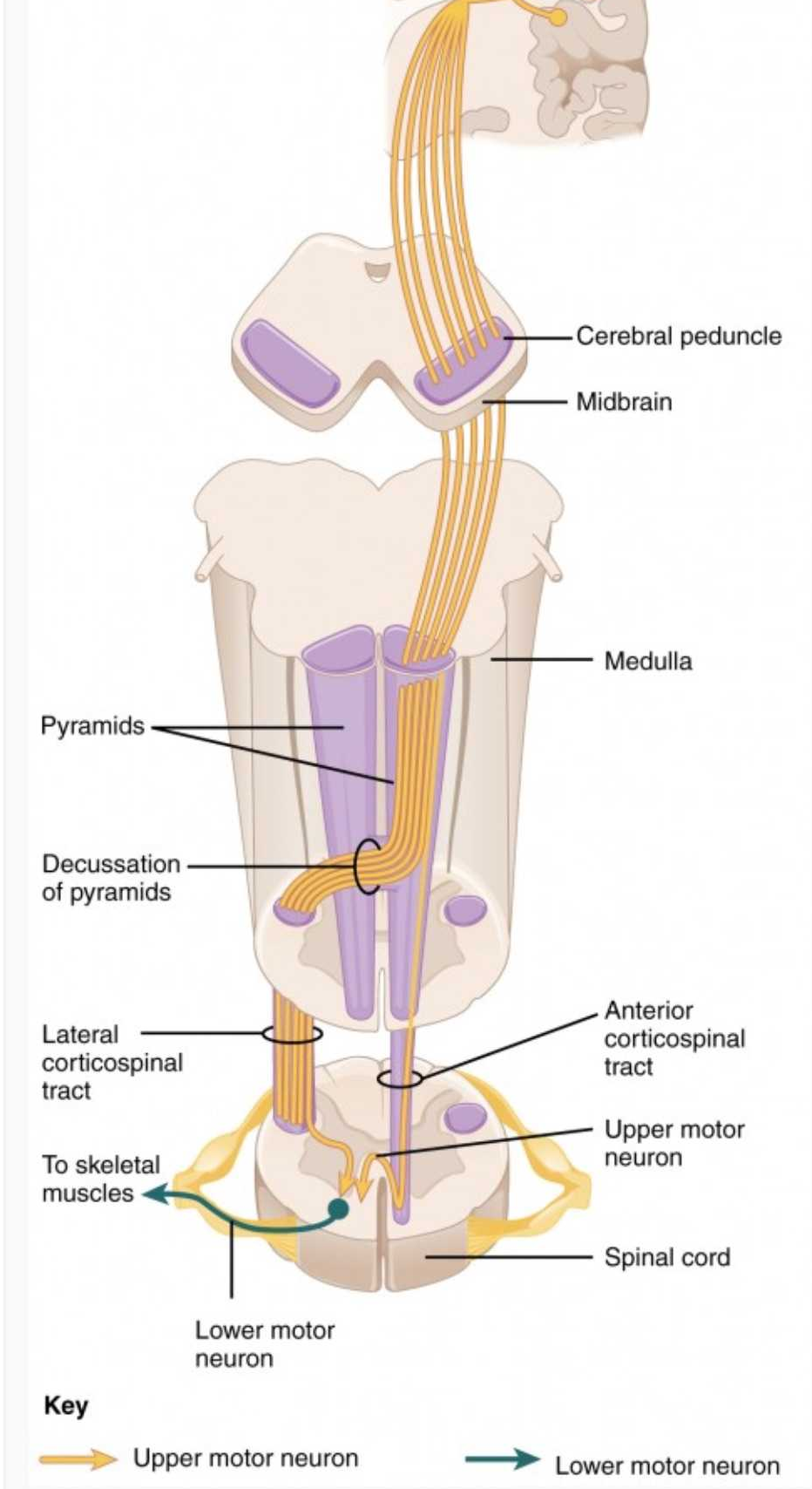

By OpenStax College [CC BY 3.0 (http://creativecommons.org/licenses/by/3.0)], via Wikimedia Commons

Clinical implications

Spinal cord syndrome	Mechanism	Tracts affected	Clinical features
Complete cord transection	Major trauma	All tracts	Death (C1 – C3), paralysis of voluntary/automatic breathing (above C5), quadriplegia (C4 – C5), paraplegia (below T1), UMN paralysis below lesion, complete sensory loss below lesion, urinary and faecal incontinence, anhidrosis and loss of vasomotor tone

Brown-Sequard syndrome (hemisection)	Penetrating trauma	All tracts on one side	Ipsilateral UMN paralysis below lesion, ipsilateral loss of proprioception/vibration/fine touch sensation below lesion, contralateral loss of crude touch/pain/temperature sensation below lesion, bilateral lower limb ataxia
Central cord syndrome	Hyperextension injury of cervical spine in patient with pre-existing cervical stenosis	Lateral corticospinal tract, spinothalamic tract	Bilateral sensory loss and UMN motor loss below lesion with greater loss in upper limbs than lower limbs, and greater loss of motor function than sensory function
Anterior cord syndrome	Occlusion of anterior spinal artery with infarction of territory supplied	Corticospinal, spinothalamic and spinocerebellar	Paralysis of voluntary/automatic breathing, faecal and urinary incontinence, bilateral Horner's syndrome, bilateral flaccid paralysis at level of lesion, bilateral spastic paralysis below lesion, bilateral loss of crude touch/pain/temperature sensation below lesion, cerebellar incoordination

Incomplete lesions of the spinal cord

Central Cord Syndrome

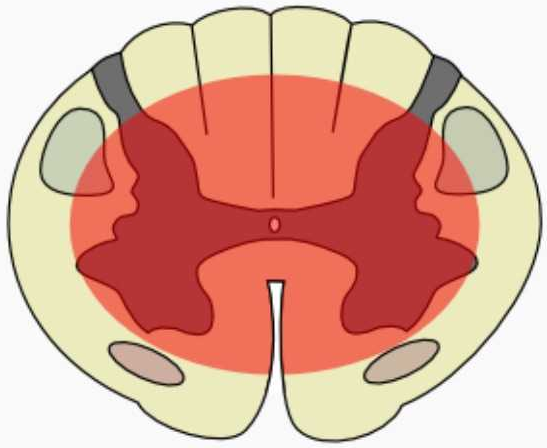

Anterior Cord Syndrome

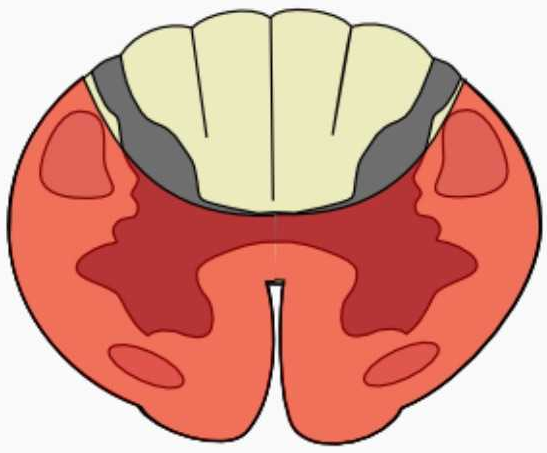

Brown-Séquard Syndrome

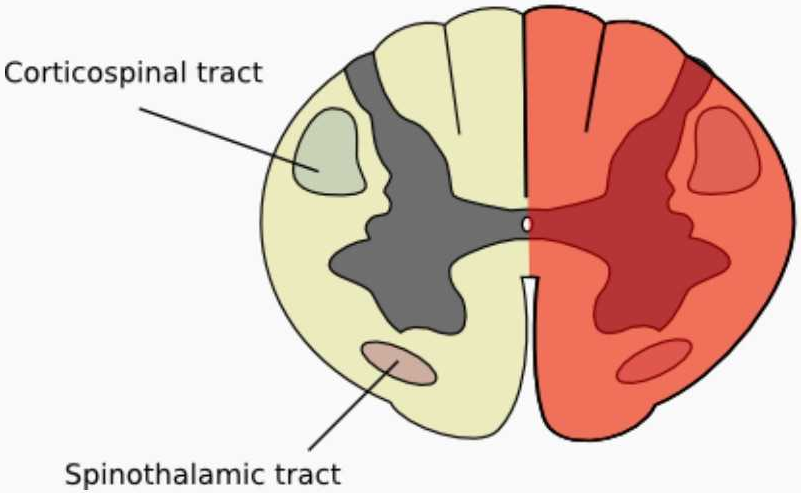

by Fpjacquot, via Wikimedia Commons

< Previous | Next >

Something wrong?

FRCEM Success

We are an online revision resource for FRCEM Primary and Intermediate exam preparation.

Terms & Conditions
Get in Touch

Resources

- The Royal College of Emergency Medicine
- Irish Association for Emergency Medicine
- Advanced Trauma Life Support
- Resuscitation Council (UK)
- TeachMeAnatomy
- Trauma.org
- Radiopaedia
- Advanced Life Support Group
- Emergency Medicine Journal
- Lifeinthefastlane
- Instant Anatomy
- Patient.co.uk

FRCEMSuccess

©2014 - 2017 FRCEM Success | Website designed & hosted by Cyberfrog Design

Anatomy: Neck

Question 69 of 78

The jugulo-omohyoid lymph node receives lymph drainage primarily from which of the following territories:

a Tongue

b Tonsils

c Lower teeth

d Upper teeth

e Nasopharynx

< Previous | Next > | See Answer

Something wrong?

Question Navigator

1 Answered
2 Answered
3 Answered
4 Answered
5 Answered
6 Answered
7 Answered
8 Answered
9 Answered
10 Answered
11 Answered
12 Answered

Clear Exam

©2014 - 2017 FRCEM Success | Website designed & hosted by Cyberfrog Design

Anatomy: Neck

Question 69 of 78

The jugulo-omohyoid lymph node receives lymph drainage primarily from which of the following territories:

a) Tongue ✔
b) **Tonsils** ✘
c) Lower teeth
d) Upper teeth
e) Nasopharynx

Answer

The jugulo-omohyoid node receives lymphatic drainage from the tongue.

Notes

The deep cervical nodes form a chain along the internal jugular vein and are divided into upper and lower groups.

The most superior node in the upper group (lying where the posterior belly of the digastric muscle crosses the internal jugular vein) is the jugulodigastric node which receives lymphatic drainage from the tonsils and tonsillar region.

The most superior node in the lower group (lying just inferior to the intermediate tendon of the omohyoid muscle) is the jugulo-omohyoid node which receives lymphatic drainage from the tongue.

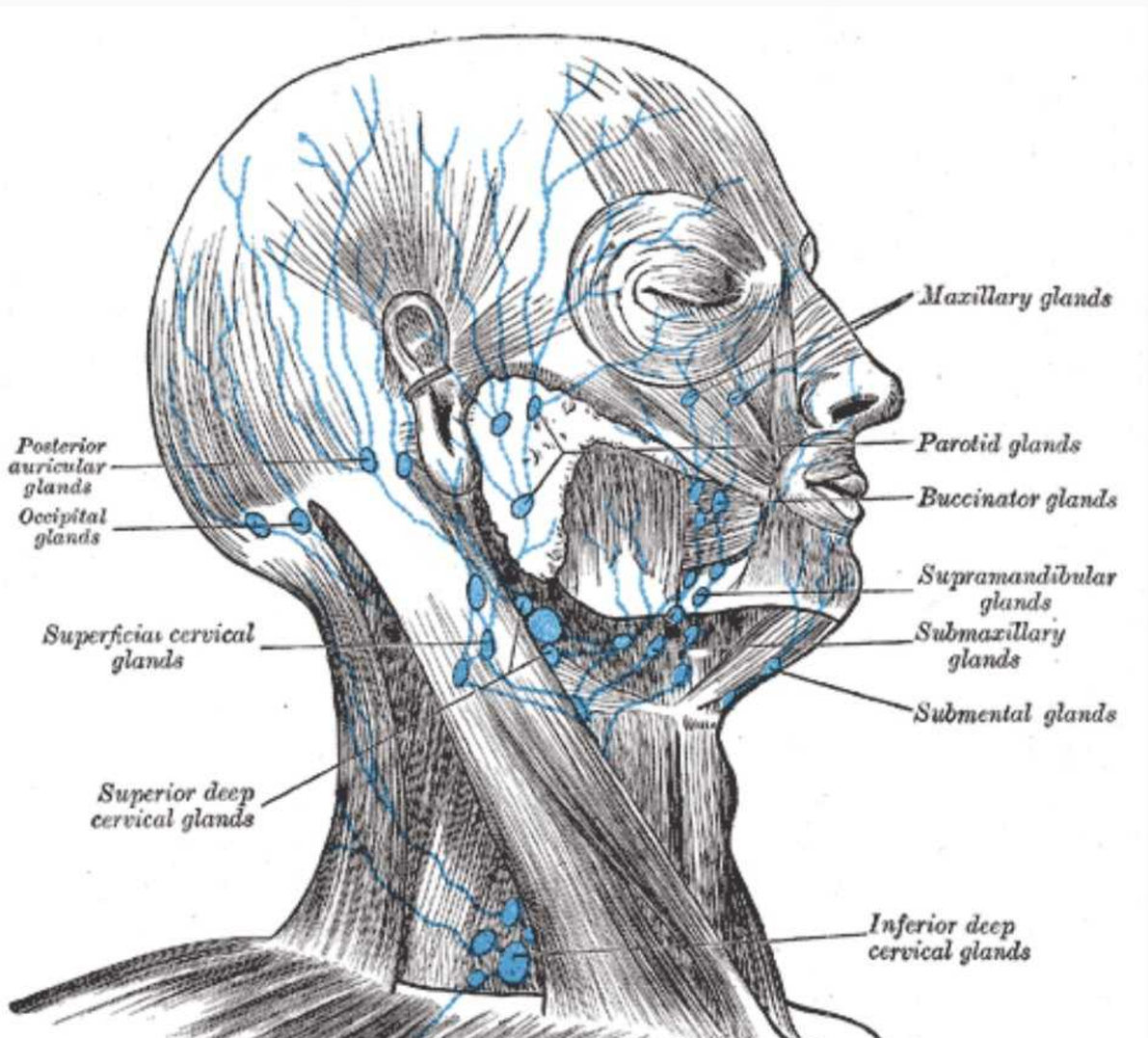

By Henry Vandyke Carter [Public domain], via Wikimedia Commons

< Previous | Next >

Something wrong?

Question Navigator

1 Answered
2 Answered
3 Answered
4 Answered
5 Answered
6 Answered
7 Answered
8 Answered
9 Answered
10 Answered
11 Answered
12 Answered

Clear Exam

©2014 - 2017 FRCEM Success | Website designed & hosted by Cyberfrog Design

Anatomy: Neck

Question 70 of 78

Which of the following is the most inferior cartilage of the larynx:

a Cricoid

b Thyroid

c Epiglottis

d Arytenoid

e Corniculate

< Previous | Next > | See Answer

Something wrong?

Question Navigator

1 Answered
2 Answered
3 Answered
4 Answered
5 Answered
6 Answered
7 Answered
8 Answered
9 Answered
10 Answered
11 Answered
12 Answered

Clear Exam

©2014 - 2017 FRCEM Success | Website designed & hosted by Cyberfrog Design

Anatomy: Neck

Question 70 of 78

Which of the following is the most inferior cartilage of the larynx:

a) Cricoid ✔
b) Thyroid
c) Epiglottis
d) Arytenoid
e) Corniculate

Answer

The cricoid cartilage is the most inferior of the laryngeal cartilages and completely encircles the airway.

Notes

The structure of the larynx is formed from three large unpaired cartilages (cricoid, thyroid, and epiglottis), three smaller paired cartilages (arytenoid, corniculate and cuneiform), joints, ligaments, a fibroelastic membrane and numerous intrinsic muscles.

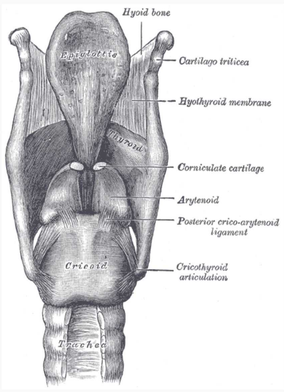

By Henry Vandyke Carter [Public domain], via Wikimedia Commons

Cartilages

The cricoid cartilage is the most inferior of the laryngeal cartilages and completely encircles the airway. The cricoid cartilage articulates with the base of the arytenoid cartilages superiorly (forming the cricoarytenoid joint) and the inferior horns of the thyroid cartilage posterolaterally (forming the cricothyroid joint).

The thyroid cartilage is the largest of the laryngeal cartilages. The thyroid cartilage articulates with the cricoid cartilage inferiorly and the hyoid bone superiorly.

The epiglottis is attached to the posterior aspect of the thyroid cartilage and projects posterosuperiorly. The upper margin of the epiglottis is behind the pharyngeal part of the tongue.

The two arytenoid cartilages articulate inferiorly with the cricoid cartilage and superiorly with the corniculate cartilages.

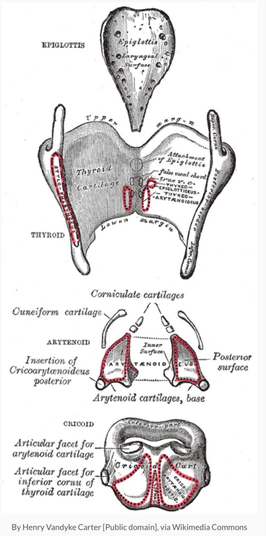

By Henry Vandyke Carter [Public domain], via Wikimedia Commons

Joints

The cricothyroid and cricoarytenoid joints are the main laryngeal joints allowing normal function.

Movements at the cricoarytenoid joints abduct and adduct the vocal ligaments.

Movements at the cricothyroid joint enable the thyroid cartilage to move forward and tilt downwards on the cricoid cartilage which effectively lengthens and puts tension on the vocal ligaments.

Cricothyroid membrane

The cricothyroid membrane (conus elasticus) is attached to the arch of the cricoid cartilage and extends superiorly to end in a free upper margin within the space enclosed by the thyroid cartilage. This upper free margin attaches on each side anteriorly to the thyroid cartilage and posteriorly to the vocal processes of the arytenoid cartilage. The free margin between these two points is thickened to form the vocal ligament which is under the vocal fold of the larynx.

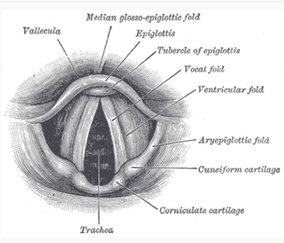

By Henry Vandyke Carter [Public domain], via Wikimedia Commons

The cricothyroid membrane is also thickened anteriorly in the midline to form the distinct median cricothyroid ligament, which spans the distance between the arch of the cricoid cartilage and the thyroid cartilage up to the attachments of the vocal ligaments. In emergency situations, when the airway is blocked above the level of the vocal folds, the median cricothyroid ligament can be perforated to establish an airway (cricothyrotomy).

< Previous | Next >

Something wrong?

Question Navigator

1 Answered
2 Answered
3 Answered
4 Answered
5 Answered
6 Answered
7 Answered
8 Answered
9 Answered
10 Answered
11 Answered
12 Answered

Clear Exam

©2014 - 2017 FRCEM Success | Website designed & hosted by Cyberfrog Design

Anatomy: Neck

Question 71 of 78

Regarding the tonsils, which of the following statements is CORRECT:

a The lingual tonsil is found on the underside of the posterior one-third of the tongue.

b The adenoid tonsil is a collection of lymphoid tissue found in the mucosa of the soft palate.

c The palatine tonsils are on the lateral walls of the nasopharynx.

d The palatine tonsils lie just posterior to the palatoglossal arch.

e Lymphatics primarily drain to the jugulo-omohyoid lymph node.

< Previous | Next > | See Answer

Something wrong?

Question Navigator

1 Answered
2 Answered
3 Answered
4 Answered
5 Answered
6 Answered
7 Answered
8 Answered
9 Answered
10 Answered
11 Answered
12 Answered

Clear Exam

©2014 - 2017 FRCEM Success | Website designed & hosted by Cyberfrog Design

Anatomy: Neck

Question 71 of 78

Regarding the tonsils, which of the following statements is CORRECT:

a) ✖
The lingual tonsil is found on the underside of the posterior one-third of the tongue.
b) The adenoid tonsil is a collection of lymphoid tissue found in the mucosa of the soft palate.
c) The palatine tonsils are on the lateral walls of the nasopharynx.
d) The palatine tonsils lie just posterior to the palatoglossal arch. ✔
e) Lymphatics primarily drain to the jugulo-omohyoid lymph node.

Answer

The palatine tonsils are on the lateral walls of the oropharynx. On each side there is a large ovoid collection of lymphoid tissue in the mucosa lining the superior constrictor muscle, between the palatoglossal and palatopharyngeal arches and just posterior to the oropharyngeal isthmus.

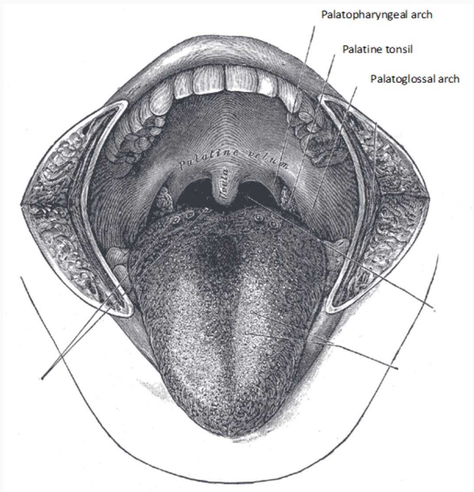

Modified by FRCEM Success. Original by Henry Vandyke Carter [Public domain], via Wikimedia Commons

Notes

Large collections of lymphoid tissue are found on the pharyngeal surface (posterior one-third) of the tongue and collectively known as the lingual tonsil.

The adenoid (pharyngeal) tonsil is a large collection of lymphoid tissue in the mucosa covering the roof of the nasopharynx.

The palatine tonsils are on the lateral walls of the oropharynx. On each side there is a large ovoid collection of lymphoid tissue in the mucosa lining the superior constrictor muscle, between the palatoglossal and palatopharyngeal arches and just posterior to the oropharyngeal isthmus.

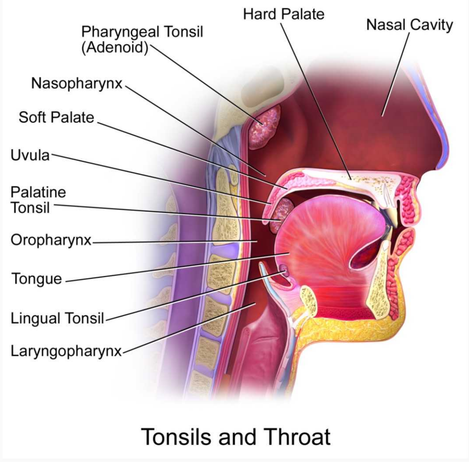

By Blausen.com staff. "Blausen gallery 2014". Wikiversity Journal of Medicine. DOI:10.15347/wjm/2014.010. ISSN 20018762. (Own work) [CC BY 3.0 (http://creativecommons.org/licenses/by/3.0)], via Wikimedia Commons

Blood supply

The palatine tonsils are highly vascular, receiving blood from the ascending palatine and tonsillar branches of the facial artery, the descending palatine branch of the maxillary artery, a palatine branch of the ascending pharyngeal artery and a branch of the lingual artery.

Tonsillectomy may result in severe haemorrhage, which may occur from the branches of the facial, ascending pharyngeal, maxillary and lingual arteries, or from paratonsillar veins.

Lymphatics

The lymphatic drainage of the palatine tonsils drains through the pharyngeal wall into the jugulodigastric nodes in the region where the facial vein drains into the internal jugular vein, inferior to the posterior belly of the digastric muscle.

< Previous | Next >

Something wrong?

Question Navigator

1 Answered
2 Answered
3 Answered
4 Answered
5 Answered
6 Answered
7 Answered
8 Answered
9 Answered
10 Answered
11 Answered
12 Answered

Clear Exam

©2014 - 2017 FRCEM Success | Website designed & hosted by Cyberfrog Design

Anatomy: Neck

Question 72 of 78

A 65 year old with known breast cancer presents to ED complaining of back pain. Imaging shows metastases compressing the intervertebral foramina between the fourth and fifth cervical vertebrae, and between the fourth and fifth thoracic vertebrae. Which of the following spinal nerves are most likely affected:

a Fourth cervical and fourth thoracic nerves

b Fifth cervical and fifth thoracic nerves

c Fifth cervical and fourth thoracic nerves

d Fourth cervical and fifth thoracic nerves

e Sixth cervical and fifth thoracic nerves

< Previous | Next > | See Answer

Something wrong?

Question Navigator

1 Answered
2 Answered
3 Answered
4 Answered
5 Answered
6 Answered
7 Answered
8 Answered
9 Answered
10 Answered
11 Answered
12 Answered

Clear Exam

©2014 - 2017 FRCEM Success | Website designed & hosted by Cyberfrog Design

Anatomy: Neck

Question 72 of 78

A 65 year old with known breast cancer presents to ED complaining of back pain. Imaging shows metastases compressing the intervertebral foramina between the fourth and fifth cervical vertebrae, and between the fourth and fifth thoracic vertebrae. Which of the following spinal nerves are most likely affected:

a) Fourth cervical and fourth thoracic nerves ✖
b) Fifth cervical and fifth thoracic nerves
c) Fifth cervical and fourth thoracic nerves ✔
d) Fourth cervical and fifth thoracic nerves
e) Sixth cervical and fifth thoracic nerves

Answer

All cervical spinal nerves exit through the intervertebral foramina above the corresponding vertebra (except the eighth cervical nerve which runs inferior to the seventh cervical vertebra). All other spinal nerves exit the intervertebral foramina below the corresponding vertebrae. Therefore the fifth cervical nerve passes between the fourth and fifth cervical vertebrae, and the fourth thoracic nerve passes between the fourth and fifth thoracic vertebrae.

Notes

Spinal cord extent

The spinal cord arises cranially as a continuation of the medulla oblongata at the foramen magnum. It then travels inferiorly within the vertebral canal, surrounded by the spinal meninges, before terminating as the conus medullaris. The filum terminale is an extension of pia mater that extends from the conus medullaris to the dural sac, and from the dural sac to the coccyx.

At birth, the conus medullaris lies at L3. By the age of 21, it sits at L1/L2, thus the spinal cord only occupies about 2/3s of the space available to it in the vertebral canal. The lower a nerve root, therefore, the more steeply it slopes down and the further it has to travel before gaining its intervertebral foramen. The lumbosacral nerve roots that arise from the end of the spinal cord and descend through the subarachnoid space to exit through their respective intervertebral or sacral foramina are bundled together forming the cauda equina.

Spinal cord enlargements

During the course of the spinal cord, there are two points of enlargement:

- The cervical enlargement is located at the C3 – T1 level and represents the origin of the brachial plexus.
- The lumbar enlargement is located at the T9 – L1 level and represents the origin of the lumbar and sacral plexuses.

Spinal nerve roots

The spinal nerves are formed by the union of posterior and anterior roots.

Spinal rootlets emerge from the spinal cord in the subarachnoid space and amalgamate shortly afterwards into roots. Anterior roots (containing motor nerve fibres) and posterior roots (containing the processes of sensory neurons) then emerge from their individual intervertebral foramina.

After invaginating the dura, the roots combine into mixed spinal nerves which divide into a posterior ramus (innervating intrinsic back muscles and an associated strip of skin on the back) and an anterior ramus (innervating the remaining muscles and skin of the trunk and limbs and the visceral organs).

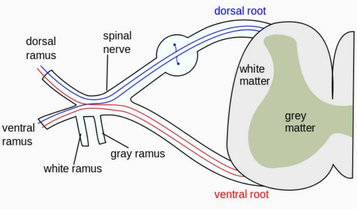

By Mysid (original by Tristanb) [GFDL (http://www.gnu.org/copyleft/fdl.html) or CC-BY-SA-3.0 (http://creativecommons.org/licenses/by-sa/3.0/)], via Wikimedia Commons

Internal anatomy

Internally the spinal cord has a small central canal (containing CSF) surrounded by grey and white matter. The central grey matter is rich in nerve cell bodies which are divided into three divisions (the anterior, posterior and lateral horns), which in cross-section form the characteristic H-shaped appearance in the central regions of the cord. The peripheral white matter surrounds the grey matter and is rich in myelinated nerve cell processes, which form large bundles or tracts that ascend and descend in the cord to other spinal cord levels or the brain. The white matter is divided bilaterally by sulci into three major divisions (the anterior, posterior and lateral columns).

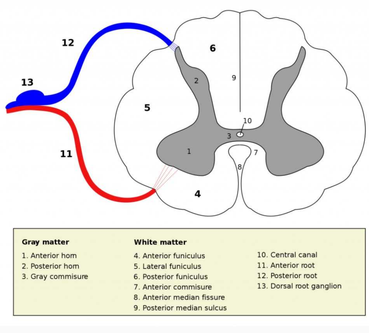

By User:Polarlys (Own work) [GFDL (http://www.gnu.org/copyleft/fdl.html), CC-BY-SA-3.0 (http://creativecommons.org/licenses/by-sa/3.0/) or CC BY 2.5 (http://creativecommons.org/licenses/by/2.5)], via Wikimedia Commons

Spinal cord blood supply

The spinal cord is supplied primarily by branches of the vertebral artery:

- The single anterior spinal artery is formed from the left and right vertebral arteries and supplies the anterior two-thirds of the spinal cord, including the anterior and lateral horns and the anterior and lateral columns.
- The paired posterior spinal arteries arise from either the posterior inferior cerebellar artery or directly from the vertebral artery and supply the posterior third of the spinal cord including the posterior horns and columns.

< Previous | Next >

Something wrong?

Question Navigator

1 Answered
2 Answered
3 Answered
4 Answered
5 Answered
6 Answered
7 Answered
8 Answered
9 Answered
10 Answered
11 Answered
12 Answered

Clear Exam

©2014 - 2017 FRCEM Success | Website designed & hosted by Cyberfrog Design

Anatomy: Neck

Question 73 of 78

A 28 year old male was brought into ED by the police following a drunken brawl. He has been punched on his mandible, resulting in subluxation of the atlanto-axial joint. Which of the following movements is most likely to be affected by this movement:

a Flexion

b Extension

c Rotation

d Lateral flexion

e Abduction

< Previous | Next > | See Answer

Something wrong?

Question Navigator

1 Answered
2 Answered
3 Answered
4 Answered
5 Answered
6 Answered
7 Answered
8 Answered
9 Answered
10 Answered
11 Answered
12 Answered

Clear Exam

©2014 - 2017 FRCEM Success | Website designed & hosted by Cyberfrog Design

Anatomy: Neck

Question 73 of 78

A 28 year old male was brought into ED by the police following a drunken brawl. He has been punched on his mandible, resulting in subluxation of the atlanto-axial joint. Which of the following movements is most likely to be affected by this movement:

a) Flexion ✗
b) Extension
c) Rotation ✓
d) Lateral flexion
e) Abduction

Answer

The atlanto-axial joints allow the head to rotate from side to side.

Notes

Vertebra C1 (the atlas) is distinguished by its lack of vertebral body, essentially being composed of two lateral masses interconnected by an anterior and posterior arch. Each lateral mass articulates above with an occipital condyle of the skull and below with the superior articular facet of vertebra C2 (the axis). The posterior surface of the anterior arch has an articular facet for the dens of the axis.

The axis is characterised by the large dens, which extends superiorly from its vertebral body to articulate with the anterior arch of the atlas, and by its bifid spinous process. The dens is held in position by the strong transverse ligament of atlas posterior to it and spanning the distance between the lateral masses of the atlas.

The atlanto-occipital joints allow the head to nod up and down on the vertebral column.

The atlanto-axial joints allow the head to rotate from side to side.

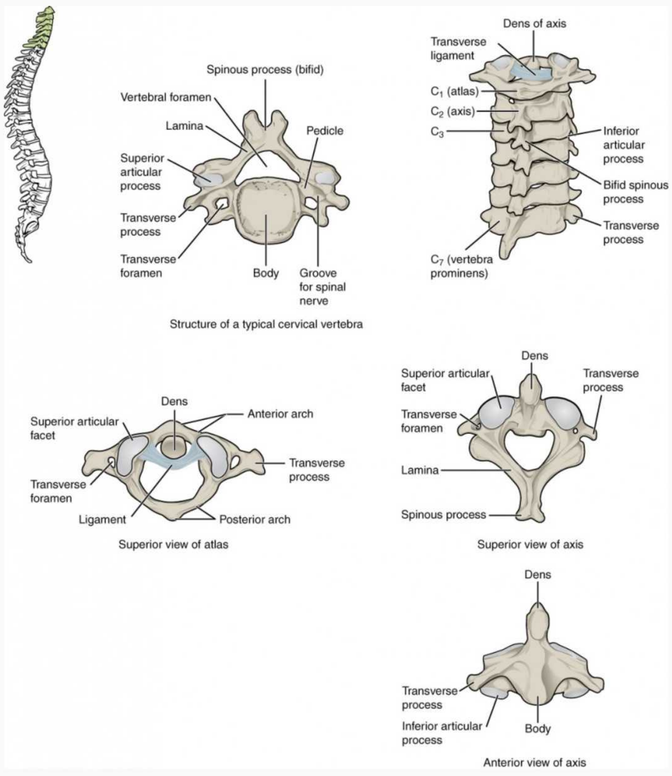

By OpenStax College [CC BY 3.0], via Wikimedia Commons

< Previous | Next >

Something wrong?

Question Navigator

1 Answered
2 Answered
3 Answered
4 Answered
5 Answered
6 Answered
7 Answered
8 Answered
9 Answered
10 Answered
11 Answered
12 Answered

Clear Exam

©2014 - 2017 FRCEM Success | Website designed & hosted by Cyberfrog Design

Anatomy: Neck

Question 74 of 78

The sternocleidomastoid muscle acts to produce which of the following movements:

a Flexion and rotation of the head

b Rotation of the head to face the opposite side and lateral flexion of the head to the opposite side

c Rotation of the head to face the same side and lateral flexion of the head to the same side

d Rotation of the head to face the same side and lateral flexion of the head to the opposite side

e Rotation of the head to face the opposite side and lateral flexion of the head to the same side

< Previous | Next > | See Answer

Something wrong?

Question Navigator

1 Answered
2 Answered
3 Answered
4 Answered
5 Answered
6 Answered
7 Answered
8 Answered
9 Answered
10 Answered
11 Answered
12 Answered

Clear Exam

©2014 - 2017 FRCEM Success | Website designed & hosted by Cyberfrog Design

Anatomy: Neck

Question 74 of 78

The sternocleidomastoid muscle acts to produce which of the following movements:

a) **Flexion and rotation of the head** ✗
b) Rotation of the head to face the opposite side and lateral flexion of the head to the opposite side
c) Rotation of the head to face the same side and lateral flexion of the head to the same side
d) Rotation of the head to face the same side and lateral flexion of the head to the opposite side
e) Rotation of the head to face the opposite side and lateral flexion of the head to the same side ✓

Answer

Individually each muscle will tilt the head towards the shoulder on the same side (lateral flexion) and rotate the head to turn to face the opposite side. Acting together the muscles draw the head forward, through extension of the neck at the atlanto-occipital joints (dorsal extension).

Notes

Muscle	Sternocleidomastoid
Origin	• Sternal head: anterior manubrium of sternum • Clavicular head: medial one-third of clavicle
Insertion	• Sternal head: lateral one-half of superior nuchal line • Clavicular head: lateral mastoid process
Innervation	Accessory nerve (and by branches of anterior rami of C2 – C3)
Action	• Acting unilaterally: lateral rotation of head towards same side and rotation of head towards opposite side • Acting bilaterally: dorsal extension of head

The sternocleidomastoid muscle has two heads; the sternal head originates from the upper part of the anterior manubrium of the sternum and inserts onto the lateral one-half of the superior nuchal line (occipital bone) and the clavicular head originates from the superior surface of the medial one-third of the clavicle and inserts onto the lateral surface of the mastoid process (temporal bone).

The sternocleidomastoid is innervated by the accessory nerve (CN XI) and by branches of anterior rami of C2 – C3.

Individually each muscle will tilt the head towards the shoulder on the same side (lateral flexion) and rotate the head to turn to face the opposite side. Acting together the muscles draw the head forward, through extension of the neck at the atlanto-occipital joints (dorsal extension).

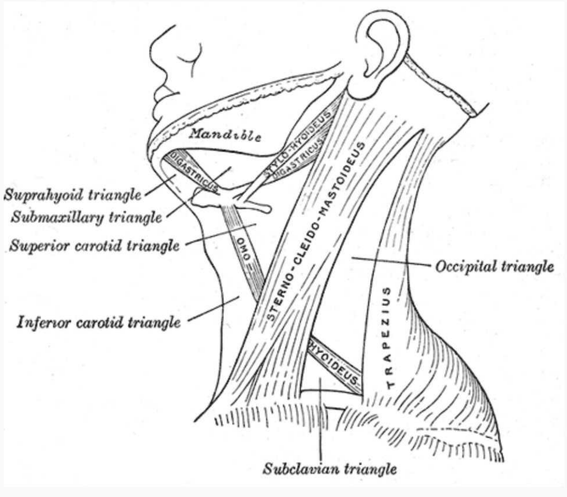

By Henry Vandyke Carter [Public domain], via Wikimedia Commons

< Previous | Next > | Something wrong?

Question Navigator

1 Answered
2 Answered
3 Answered
4 Answered
5 Answered
6 Answered
7 Answered
8 Answered
9 Answered
10 Answered
11 Answered
12 Answered

Clear Exam

©2014 - 2017 FRCEM Success | Website designed & hosted by Cyberfrog Design

Anatomy: Neck

Question 75 of 78

The vocal ligament is formed by which of the following structures:

a Vocal folds

b Cricothyroid membrane

c Thyrohyoid ligament

d Median cricothyroid ligament

e Cricothyroid muscle

< Previous | Next > | See Answer

Something wrong?

Question Navigator

1 Answered
2 Answered
3 Answered
4 Answered
5 Answered
6 Answered
7 Answered
8 Answered
9 Answered
10 Answered
11 Answered
12 Answered

Clear Exam

©2014 - 2017 FRCEM Success | Website designed & hosted by Cyberfrog Design

Anatomy: Neck

Question 75 of 78

The vocal ligament is formed by which of the following structures:

a) **Vocal folds** ✖
b) Cricothyroid membrane ✔
c) Thyrohyoid ligament
d) Median cricothyroid ligament
e) Cricothyroid muscle

Answer

The cricothyroid membrane (conus elasticus) is attached to the arch of the cricoid cartilage and extends superiorly to end in a free upper margin within the space enclosed by the thyroid cartilage. This upper free margin attaches on each side anteriorly to the thyroid cartilage and posteriorly to the vocal processes of the arytenoid cartilage. The free margin between these two points is thickened to form the vocal ligament which is under the vocal fold of the larynx.

Notes

The structure of the larynx is formed from three large unpaired cartilages (cricoid, thyroid, and epiglottis), three smaller paired cartilages (arytenoid, corniculate and cuneiform), joints, ligaments, a fibroelastic membrane and numerous intrinsic muscles.

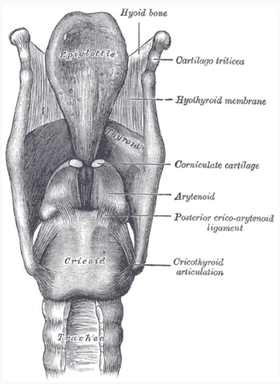

By Henry Vandyke Carter [Public domain], via Wikimedia Commons

Cartilages

The cricoid cartilage is the most inferior of the laryngeal cartilages and completely encircles the airway. The cricoid cartilage articulates with the base of the arytenoid cartilages superiorly (forming the cricoarytenoid joint) and the inferior horns of the thyroid cartilage posterolaterally (forming the cricothyroid joint).

The thyroid cartilage is the largest of the laryngeal cartilages. The thyroid cartilage articulates with the cricoid cartilage inferiorly and the hyoid bone superiorly.

The epiglottis is attached to the posterior aspect of the thyroid cartilage and projects posterosuperiorly. The upper margin of the epiglottis is behind the pharyngeal part of the tongue.

The two arytenoid cartilages articulate inferiorly with the cricoid cartilage and superiorly with the corniculate cartilages.

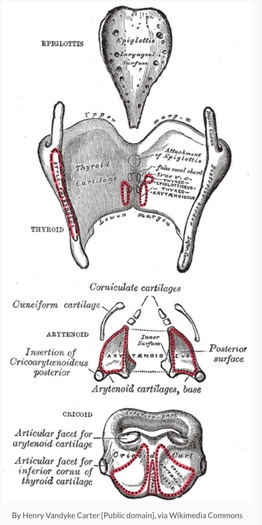

By Henry Vandyke Carter [Public domain], via Wikimedia Commons

Joints

The cricothyroid and cricoarytenoid joints are the main laryngeal joints allowing normal function.

Movements at the cricoarytenoid joints abduct and adduct the vocal ligaments.

Movements at the cricothyroid joint enable the thyroid cartilage to move forward and tilt downwards on the cricoid cartilage which effectively lengthens and puts tension on the vocal ligaments.

Cricothyroid membrane

The cricothyroid membrane (conus elasticus) is attached to the arch of the cricoid cartilage and extends superiorly to end in a free upper margin within the space enclosed by the thyroid cartilage. This upper free margin attaches on each side anteriorly to the thyroid cartilage and posteriorly to the vocal processes of the arytenoid cartilage. The free margin between these two points is thickened to form the vocal ligament which is under the vocal fold of the larynx.

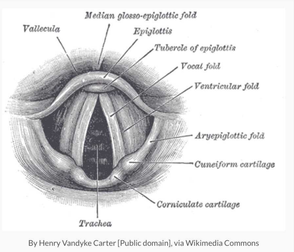

By Henry Vandyke Carter [Public domain], via Wikimedia Commons

The cricothyroid membrane is also thickened anteriorly in the midline to form the distinct median cricothyroid ligament, which spans the distance between the arch of the cricoid cartilage and the thyroid cartilage up to the attachments of the vocal ligaments. In emergency situations, when the airway is blocked above the level of the vocal folds, the median cricothyroid ligament can be perforated to establish an airway (cricothyrotomy).

< Previous | Next >

Something wrong?

Question Navigator

1 Answered
2 Answered
3 Answered
4 Answered
5 Answered
6 Answered
7 Answered
8 Answered
9 Answered
10 Answered
11 Answered
12 Answered

Clear Exam

©2014 - 2017 FRCEM Success | Website designed & hosted by Cyberfrog Design

Anatomy: Neck

Question 76 of 78

A 18 year old man presents to ED with gross lip and tongue swelling and difficulty breathing. He has a known peanut allergy and had been eating at a Thai restaurant for dinner. A decision is quickly made that he requires an emergency cricothyrotomy. Which of the following landmarks describes the most appropriate location to make the incision:

a The cricothyroid membrane, between the hyoid bone above and the thyroid cartilage below.

b The cricothyroid membrane, between the thyroid cartilage above and the cricoid cartilage below.

c The cricothyroid membrane between the cricoid cartilage above and the thyroid cartilage below.

d The thyrohyoid membrane, between the thyroid cartilage below and the hyoid bone above.

e The trachea just inferior to the cricoid cartilage.

< Previous | Next > | See Answer

Something wrong?

Question Navigator

1 Answered
2 Answered
3 Answered
4 Answered
5 Answered
6 Answered
7 Answered
8 Answered
9 Answered
10 Answered
11 Answered
12 Answered

Clear Exam

©2014 - 2017 FRCEM Success | Website designed & hosted by Cyberfrog Design

Anatomy: Neck

Question 76 of 78

A 18 year old man presents to ED with gross lip and tongue swelling and difficulty breathing. He has a known peanut allergy and had been eating at a Thai restaurant for dinner. A decision is quickly made that he requires an emergency cricothyrotomy. Which of the following landmarks describes the most appropriate location to make the incision:

a) ✖
The cricothyroid membrane, between the hyoid bone above and the thyroid cartilage below.

b) ✔
The cricothyroid membrane, between the thyroid cartilage above and the cricoid cartilage below.

c) The cricothyroid membrane between the cricoid cartilage above and the thyroid cartilage below.

d) The thyrohyoid membrane, between the thyroid cartilage below and the hyoid bone above.

e) The trachea just inferior to the cricoid cartilage.

Answer

A cricothyrotomy involves making an opening in the median cricothyroid ligament (the medial part of the cricothyroid membrane), between the cricoid cartilage below and the thyroid cartilage above.

Notes

The trachea begins at vertebral level C6, where it is continuous with the larynx above. The trachea lies directly anterior to the oesophagus and travels inferiorly to pass through the thoracic inlet.

Cricothyrotomy

A cricothyrotomy is performed to provide a temporary emergency airway in situations where there is obstruction at or above the level of the larynx, such that oral/nasal endotracheal intubation is impossible e.g. as a result of inhalation of a foreign body, severe oedema secondary to anaphylactic reaction, or severe head and neck trauma.

Compared with an emergency tracheostomy, it is quicker and easier to perform and associated with fewer complications. It involves making an opening in the median cricothyroid ligament (the medial part of the cricothyroid ligament), between the cricoid and thyroid cartilages of the larynx. The ligament can be palpated in the midline and usually there are only small blood vessels, connective tissue and skin overlying it.

Tracheostomy

At a lower level, the airway can be accessed surgically (or percutaneously) through the anterior wall of the trachea by tracheostomy. Tracheostomy is usually performed in non-emergency situations.

A small transverse incision is placed in the lower third of the neck anteriorly. The strap (infrahyoid) muscles are deviated laterally and the trachea can be easily visualised. Occasionally it is necessary to divide the isthmus of the thyroid. An incision is typically made between the second and third or the third and fourth tracheal rings and a small tracheostomy tube inserted.

This route of entry is complicated because large veins and part of the thyroid gland overlie this region. Structures particularly vulnerable include the isthmus of the thyroid, the jugular arch connecting the anterior jugular veins, the inferior thyroid vein, the left brachiocephalic vein, the thyroidea ima artery, and the recurrent laryngeal nerve (less commonly).

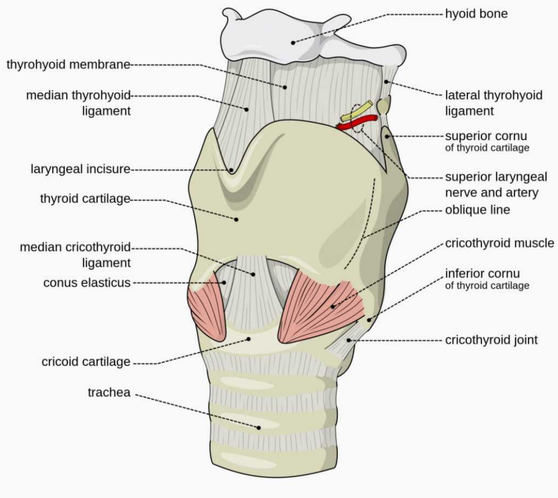

By Olek Remesz (wiki-pl: Orem, commons: Orem) [CC BY-SA 2.5-2.0-1.0], via Wikimedia Commons

< Previous | Next > | Something wrong?

Question Navigator

1 Answered
2 Answered
3 Answered
4 Answered
5 Answered
6 Answered
7 Answered
8 Answered
9 Answered
10 Answered
11 Answered
12 Answered

Clear Exam

©2014 - 2017 FRCEM Success | Website designed & hosted by Cyberfrog Design

Anatomy: Neck

Question 77 of 78

In adults, the conus medullaris of the spinal cord lies at which of the following vertebral levels:

a T11/T12

b T12/L1

c L1/L2

d L3/L4

e L4/L5

< Previous | Next > | See Answer

Something wrong?

Question Navigator

1 Answered
2 Answered
3 Answered
4 Answered
5 Answered
6 Answered
7 Answered
8 Answered
9 Answered
10 Answered
11 Answered
12 Answered

Clear Exam

©2014 - 2017 FRCEM Success | Website designed & hosted by Cyberfrog Design

Anatomy: Neck

Question 77 of 78

In adults, the conus medullaris of the spinal cord lies at which of the following vertebral levels:

a) T11/T12 ✗
b) T12/L1
c) L1/L2 ✓
d) L3/L4
e) L4/L5

Answer

At birth, the conus medullaris lies at L3. By the age of 21, it sits at L1/L2.

Notes

Spinal cord extent

The spinal cord arises cranially as a continuation of the medulla oblongata at the foramen magnum. It then travels inferiorly within the vertebral canal, surrounded by the spinal meninges, before terminating as the conus medullaris. The filum terminale is an extension of pia mater that extends from the conus medullaris to the dural sac, and from the dural sac to the coccyx.

At birth, the conus medullaris lies at L3. By the age of 21, it sits at L1/L2, thus the spinal cord only occupies about 2/3s of the space available to it in the vertebral canal. The lower a nerve root, therefore, the more steeply it slopes down and the further it has to travel before gaining its intervertebral foramen. The lumbosacral nerve roots that arise from the end of the spinal cord and descend through the subarachnoid space to exit through their respective intervertebral or sacral foramina are bundled together forming the cauda equina.

Spinal cord enlargements

During the course of the spinal cord, there are two points of enlargement:

- The cervical enlargement is located at the C3 – T1 level and represents the origin of the brachial plexus.
- The lumbar enlargement is located at the T9 – L1 level and represents the origin of the lumbar and sacral plexuses.

Spinal nerve roots

The spinal nerves are formed by the union of posterior and anterior roots.

Spinal rootlets emerge from the spinal cord in the subarachnoid space and amalgamate shortly afterwards into roots. Anterior roots (containing motor nerve fibres) and posterior roots (containing the processes of sensory neurons) then emerge from their individual intervertebral foramina.

After invaginating the dura, the roots combine into mixed spinal nerves which divide into a posterior ramus (innervating intrinsic back muscles and an associated strip of skin on the back) and an anterior ramus (innervating the remaining muscles and skin of the trunk and limbs and the visceral organs).

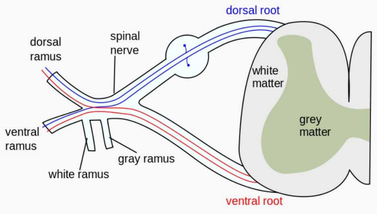

By Mysid (original by Tristanb) [GFDL (http://www.gnu.org/copyleft/fdl.html) or CC-BY-SA-3.0 (http://creativecommons.org/licenses/by-sa/3.0/)], via Wikimedia Commons

Internal anatomy

Internally the spinal cord has a small central canal (containing CSF) surrounded by grey and white matter. The central grey matter is rich in nerve cell bodies which are divided into three divisions (the anterior, posterior and lateral horns), which in cross-section form the characteristic H-shaped appearance in the central regions of the cord. The peripheral white matter surrounds the grey matter and is rich in myelinated nerve cell processes, which form large bundles or tracts that ascend and descend in the cord to other spinal cord levels or the brain. The white matter is divided bilaterally by sulci into three major divisions (the anterior, posterior and lateral columns).

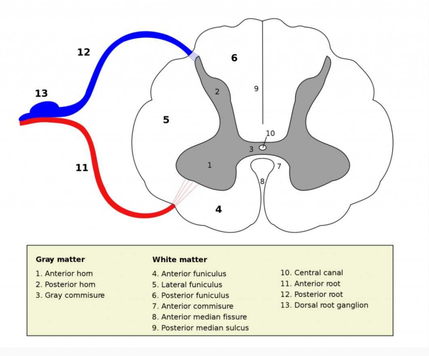

By User:Polarlys (Own work) [GFDL (http://www.gnu.org/copyleft/fdl.html), CC-BY-SA-3.0 (http://creativecommons.org/licenses/by-sa/3.0/) or CC BY 2.5 (http://creativecommons.org/licenses/by/2.5)], via Wikimedia Commons

Spinal cord blood supply

The spinal cord is supplied primarily by branches of the vertebral artery:

- The single anterior spinal artery is formed from the left and right vertebral arteries and supplies the anterior two-thirds of the spinal cord, including the anterior and lateral horns and the anterior and lateral columns.
- The paired posterior spinal arteries arise from either the posterior inferior cerebellar artery or directly from the vertebral artery and supply the posterior third of the spinal cord including the posterior horns and columns.

< Previous | Next >

Something wrong?

Question Navigator

1 Answered
2 Answered
3 Answered
4 Answered
5 Answered
6 Answered
7 Answered
8 Answered
9 Answered
10 Answered
11 Answered
12 Answered

Clear Exam

©2014 - 2017 FRCEM Success | Website designed & hosted by Cyberfrog Design

Anatomy: Neck

Question 78 of 78

Regarding the larynx, which of the following statements is INCORRECT:

a The cricoid cartilage articulates with the base of the arytenoid cartilages superiorly.

b The thyroid cartilage articulates with the cricoid cartilage inferiorly.

c The upper free margin of the cricothyroid membrane forms the vocal cords.

d The epiglottis is attached to the posterior aspect of the thyroid cartilage.

e The cricoid cartilage articulates with the hyoid bone superiorly.

< Previous | See Answer | Submit

Something wrong?

Question Navigator

1 Answered
2 Answered
3 Answered
4 Answered
5 Answered
6 Answered
7 Answered
8 Answered
9 Answered
10 Answered
11 Answered
12 Answered

Clear Exam

©2014 - 2017 FRCEM Success | Website designed & hosted by Cyberfrog Design

Anatomy: Neck

Question 78 of 78

Regarding the larynx, which of the following statements is INCORRECT:

a)
The cricoid cartilage articulates with the base of the arytenoid cartilages superiorly.
b) The thyroid cartilage articulates with the cricoid cartilage inferiorly.
c) The upper free margin of the cricothyroid membrane forms the vocal cords.
d) The epiglottis is attached to the posterior aspect of the thyroid cartilage.
e) The cricoid cartilage articulates with the hyoid bone superiorly.

Answer

The cricoid cartilage is the most inferior of the laryngeal cartilages and completely encircles the airway. The thyroid cartilage articulates with the hyoid bone superiorly.

Notes

The structure of the larynx is formed from three large unpaired cartilages (cricoid, thyroid, and epiglottis), three smaller paired cartilages (arytenoid, corniculate and cuneiform), joints, ligaments, a fibroelastic membrane and numerous intrinsic muscles.

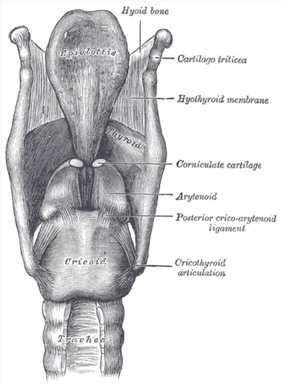

By Henry Vandyke Carter [Public domain], via Wikimedia Commons

Cartilages

The cricoid cartilage is the most inferior of the laryngeal cartilages and completely encircles the airway. The cricoid cartilage articulates with the base of the arytenoid cartilages superiorly (forming the cricoarytenoid joint) and the inferior horns of the thyroid cartilage posterolaterally (forming the cricothyroid joint).

The thyroid cartilage is the largest of the laryngeal cartilages. The thyroid cartilage articulates with the cricoid cartilage inferiorly and the hyoid bone superiorly.

The epiglottis is attached to the posterior aspect of the thyroid cartilage and projects posterosuperiorly. The upper margin of the epiglottis is behind the pharyngeal part of the tongue.

The two arytenoid cartilages articulate inferiorly with the cricoid cartilage and superiorly with the corniculate cartilages.

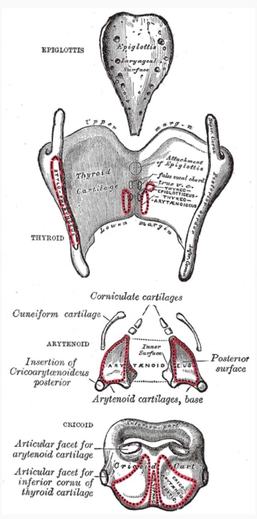

By Henry Vandyke Carter [Public domain], via Wikimedia Commons

Joints

The cricothyroid and cricoarytenoid joints are the main laryngeal joints allowing normal function.

Movements at the cricoarytenoid joints abduct and adduct the vocal ligaments.

Movements at the cricothyroid joint enable the thyroid cartilage to move forward and tilt downwards on the cricoid cartilage which effectively lengthens and puts tension on the vocal ligaments.

Cricothyroid membrane

The cricothyroid membrane (conus elasticus) is attached to the arch of the cricoid cartilage and extends superiorly to end in a free upper margin within the space enclosed by the thyroid cartilage. This upper free margin attaches on each side anteriorly to the thyroid cartilage and posteriorly to the vocal processes of the arytenoid cartilage. The free margin between these two points is thickened to form the vocal ligament which is under the vocal fold of the larynx.

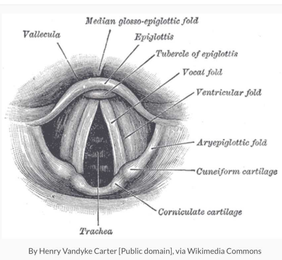

By Henry Vandyke Carter [Public domain], via Wikimedia Commons

The cricothyroid membrane is also thickened anteriorly in the midline to form the distinct median cricothyroid ligament, which spans the distance between the arch of the cricoid cartilage and the thyroid cartilage up to the attachments of the vocal ligaments. In emergency situations, when the airway is blocked above the level of the vocal folds, the median cricothyroid ligament can be perforated to establish an airway (cricothyrotomy).

< Previous | Submit | Something wrong?

Question Navigator

1 Answered
2 Answered
3 Answered
4 Answered
5 Answered
6 Answered
7 Answered
8 Answered
9 Answered
10 Answered
11 Answered
12 Answered

Clear Exam

©2014 - 2017 FRCEM Success | Website designed & hosted by Cyberfrog Design